

REM: A PUBLICATION FOR RESIDENTS AND FELLOWS

Images: polysomnographic findings of nystagmus caused by a midbrain hemorrhagic stroke

Umer Shoukat, MD¹; Danielle R. Glick, MD¹; Seemant Chaturvedi, MD²; Montserrat Diaz-Abad, MD³

¹University of Maryland Sleep Disorders Center, University of Maryland Medical Center, Baltimore, Maryland; ²Department of Neurology and Stroke Program, University of Maryland School of Medicine, Baltimore, Maryland; ³Department of Medicine, University of Maryland School of Medicine, Baltimore, Maryland

Brainstem strokes can present with an array of ophthalmologic findings depending on the location of the lesion. Eye movements are recorded on electrooculogram during polysomnography for sleep staging. We present the case of a patient with a dorsal midbrain hemorrhagic stroke and nystagmus with distinct findings on the electrooculogram during polysomnography. These eye movements from nystagmus differed in many aspects (frequency and amplitude) from the classic findings of other eye movements recorded during different stages of sleep. These polysomnography findings have not been reported in the setting of midbrain stroke. Future studies comparing nystagmus in multiple sleep stages in stroke patients would be of interest.

Keywords: nystagmus, polysomnography, stroke, dorsal midbrain syndrome, electrooculogram, hypersomnolence, narcolepsy

Citation: Shoukat U, Glick DR, Chaturvedi S, Diaz-Abad M. Images: Polysomnographic findings of nystagmus caused by a midbrain hemorrhagic stroke. *J Clin Sleep Med*. 2022;18(5):1479–1482.

BRIEF SUMMARY

Current Knowledge/Study Rationale: Eye movements are recorded on electrooculogram during polysomnography for sleep staging. Brainstem strokes can present with an array of ophthalmologic complications, including nystagmus.

Study Impact: Images are presented showing the characteristic findings of nystagmus on electrooculogram during polysomnography caused by a midbrain hemorrhagic stroke. Awareness of these characteristic findings on polysomnography may help in the detection of previously undiagnosed nystagmus.

INTRODUCTION

Sleep disturbances after stroke are common and, given the known co-occurrence of sleep-disordered breathing and stroke, polysomnography (PSG) is sometimes performed in these patients. Obstructive sleep apnea (OSA) is a common finding in stroke patients and all stroke patients should undergo evaluation for OSA as untreated OSA represents an independent risk factor for recurrent stroke. Stroke patients with OSA have worse prognosis and treatment can significantly improve cognitive and physical disabilities.¹ Occasionally, PSG can provide insight into other coexisting disorders, such as seizure or nystagmus.² We present the case of a patient post-hemorrhagic midbrain stroke with an interesting finding on electrooculogram (EOG) during PSG.

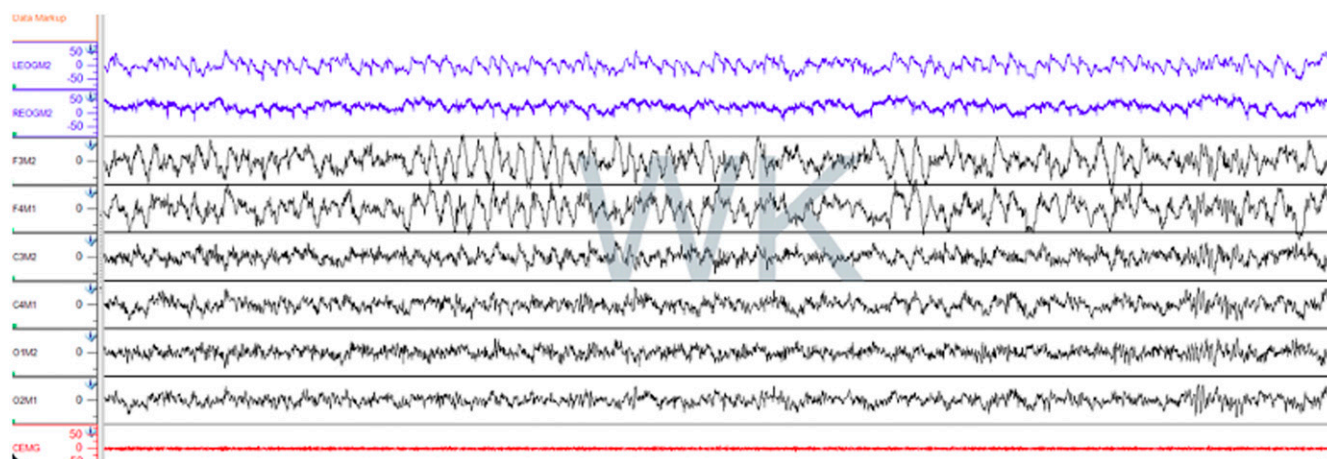
REPORT OF CASE

A 46-year-old male with a history of hyperlipidemia developed a hemorrhagic stroke of unclear etiology involving the left dorsal midbrain. His course was complicated by increased intracranial pressure requiring ventriculoperitoneal shunt placement and residual diplopia requiring the use of a right eye patch. On ophthalmologic examination 6 weeks poststroke, he was noted

to have dorsal midbrain syndrome with convergence-retraction nystagmus. The vertical nystagmus was pronounced in the right eye and persisted in all gaze positions, with a lateral nystagmus of the left eye that was intermittent.

The patient was referred by neurology to the sleep clinic 6 months poststroke due to severe and persistent hypersomnolence, which was new in onset following the stroke. Prior to this, he slept 8 hours per night, always felt refreshed when waking up, and denied daytime sleepiness or other sleep symptoms, except for snoring without witnessed apneas. Body mass index was 25.8 kg/m² and neck circumference was > 17 inches. The patient was able to resume a regular office desk job but required excessive amounts of caffeine (10 cups of coffee and energy drinks per day) to stay awake. Daily total sleep time was 15 hours and sleep was unrefreshing. The Epworth Sleepiness Scale³ score was 21/24 and STOP-BANG⁴ score was 4/8.

The patient underwent a level 3 home sleep apnea test with an estimated total sleep time > 10 hours, which revealed an apnea-hypopnea index (events/h) of 21.9 consistent with moderate OSA. He was subsequently started on home autotitrating continuous positive airway pressure therapy. Despite good compliance (use 80% of nights for an average of 5 hours and 42 minutes) and reduction of apnea-hypopnea index to near normal (6.0), there was no perceived improvement in excessive daytime sleepiness or sleep quality. Therefore, a baseline PSG

Figure 1—Nystagmus on stage W.

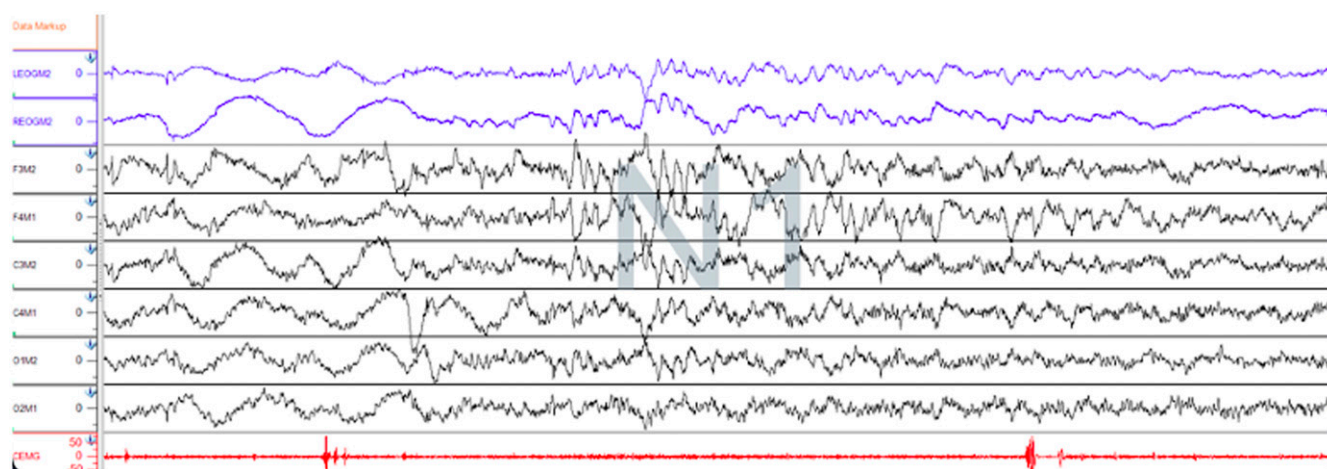
On PSG, EOG showing conjugate sharp vertical eye movements during stage W with frequency of 2.8 Hz, mean amplitude 60 μ V, and mean duration 0.36 s. Frequency is faster than eye blinks (0.5–2 Hz). The eye movements are transmitted to the F3-M2 and F4-M1 channels, represented by high amplitude waves. EOG = electrooculogram, PSG = polysomnography.

(while on continuous positive airway pressure) followed by a multiple sleep latency test was performed. The multiple sleep latency test showed mean sleep latency of 6 minutes and 49 seconds, Rapid eye movement (REM) latency of 2 minutes and 15 seconds with 2 sleep-onset REM sleep periods. Given a history of prior stroke and subsequent excessive sleepiness, the multiple sleep latency test was consistent with narcolepsy type 2 due to medical disorder. The sleep studies were performed in a fully accredited sleep laboratory and scored according to standardized criteria.⁵ During the PSG and multiple sleep latency test, unusual eye movements caused by his nystagmus were noted (**Figure 1**, **Figure 2**, and **Figure 3**).

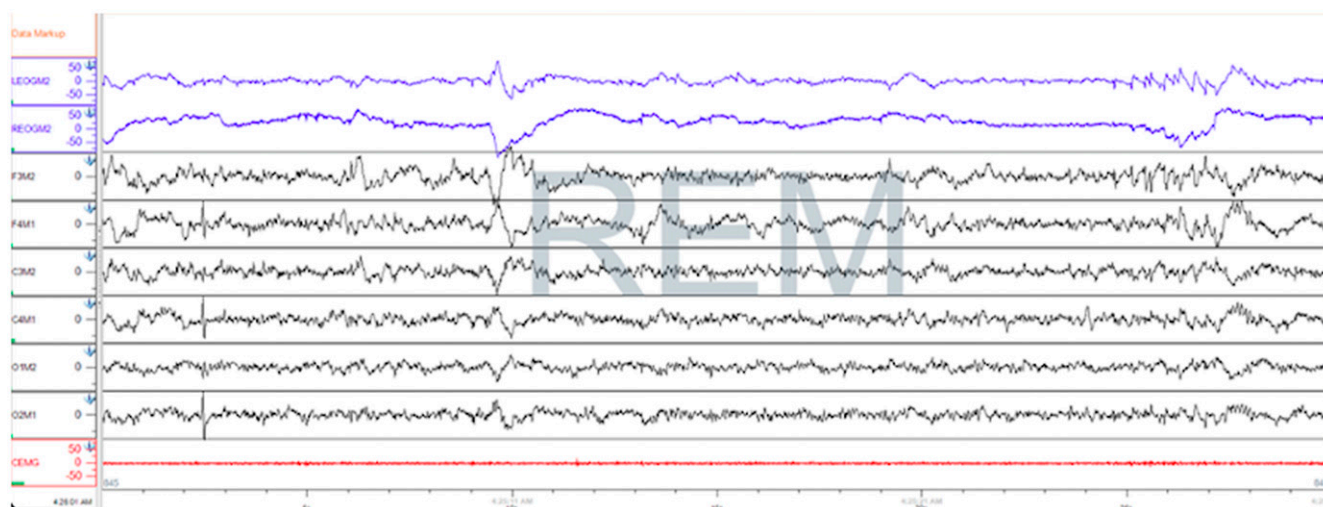
DISCUSSION

We present distinct images of nystagmus seen on EOG during PSG in a patient post–midbrain hemorrhagic stroke. The eye movements associated with nystagmus in our patient had very characteristic findings, distinct from other eye movements routinely seen on PSG.

Eye movements on PSG are recorded on the EOG due to the potential electrical difference across the eyeball, where the front (cornea) is positive and the back (retina) negative. Eye movement toward an electrode results in downward (positive)

Figure 2—Nystagmus on stage N1 sleep.

On PSG, EOG showing conjugate vertical lower frequency eye movements of 2.5 Hz during stage N1. Also noted are slow rolling eye movements in the first part of the epoch. The movements are transmitted to the F3-M2 and F4-M1 channels, represented by high amplitude waves. EOG = electrooculogram, PSG = polysomnography.

Figure 3—Nystagmus on REM stage sleep.

On PSG, EOG showing conjugate vertical sharp waves with frequency 3.5 Hz in REM stage in the second half of epoch. The waves are fast frequency-lower amplitude compared to the classic rapid eye movements of stage REM sleep seen in the first half of the epoch. EOG = electrooculogram, PSG = polysomnography, REM = rapid eye movement.

deflection and eye movement away from an electrode results in upward (negative) deflection.⁶

Previous studies have reported that the nystagmus associated with central nervous system disorders present while awake often disappears during sleep. However, it has been suggested that spontaneous neural activation may allow for nystagmus to episodically appear in REM sleep and can be present in healthy adults.^{7,8} Indeed, nystagmus in vegetative patients has been reported to persist in REM but disappears in non-REM sleep.⁹ In the present case, the very distinct pattern of rapid eye movements noted on EOG during wake persisted in non-REM and REM stage sleep. These vertical upward deflections were faster in frequency compared with eye blinks in the W (wake) stage. The deflections were sharp, with an acute angle, slowing in frequency in stages N1 and N2, with the highest frequency observed in REM. These eye movements were the result of rapid upward and adducting saccadic oscillations seen in convergence retraction nystagmus (**Figure 1**, **Figure 2**, and **Figure 3**).

The ophthalmologic manifestations of brainstem strokes depend on the location of the ischemic event. Strokes involving territories of dorsal midbrain (Parinaud syndrome) can cause dilated pupils, light near dissociation, lid retraction, lid ptosis, nystagmus (convergence retraction), and paralysis of upward and later downward gaze and accommodation.¹⁰ Due to a paucity of patients with brainstem syndromes undergoing PSG, findings of nystagmus can potentially be missed. The findings of positional nystagmus have been described in patients with benign paroxysmal positional vertigo but always in the W stage in association with positional maneuvers and tend to disappear as patients enter sleep stages.¹¹ Nystagmus associated with peripheral neuritis is absent during REM sleep.¹² To our knowledge, nystagmus has not been described in the context of stroke

and represents a finding of interest. Also, nystagmus previously reported in other case studies disappeared in non-REM sleep, but interestingly, persisted in our patient. Until more is understood about the persistence of nystagmus into sleep from wake, PSG should not be used as a screening or diagnostic tool, but rather attention should be paid to its presence, especially in the setting of stroke. Future studies comparing nystagmus during sleep stages in patients with midbrain lesions compared with other locations (pons, medulla) would be of interest.

ABBREVIATIONS

PSG, polysomnography
EOG, electrooculogram
OSA, obstructive sleep apnea
REM, rapid eye movement sleep stage

REFERENCES

1. Jehan S, Farag M, Zizi F, et al. Obstructive sleep apnea and stroke. *Sleep Med Disord*. 2018;2(5):120–125.
2. Bassetti CL, Hermann DM. Sleep and stroke. *Handb Clin Neurol*. 2011;99:1051–1072.
3. Johns MW. A new method for measuring daytime sleepiness: the Epworth sleepiness scale. *Sleep*. 1991;14(6):540–545.
4. Chung F, Yegneswaran B, Liao P, et al. STOP questionnaire: a tool to screen patients for obstructive sleep apnea. *Anesthesiology*. 2008;108(5):812–821.
5. Berry R, Quan S, Abreu A, et al; for the American Academy of Sleep Medicine. *The AASM Manual for the Scoring of Sleep and Associated Events: Rules, Terminology, and Technical Specifications*. Version 2.6. Darien, IL: American Academy of Sleep Medicine; 2020.
6. Kryger MH, Roth T, Dement WC. *Principles and Practice of Sleep Medicine*. 6th ed. Philadelphia, PA: Elsevier; 2017.

7. Tauber ES, Weitzman ED, Herman J, Pessah M. Absence of nystagmus during REM sleep in a patient with waking nystagmus and oscillopsia. *J Neurol Neurosurg Psychiatry*. 1973;36(5):833–838.
8. Kawahara R, Hazama H, Fukuhara T, Matsushita T, Makino H. Nystagmus and REM-density during sleep in patients with various brain lesions. *Waking Sleeping*. 1980;4(3):205–210.
9. Gordon CR, Oksenberg A. Spontaneous nystagmus across the sleep-wake cycle in vegetative state patients. *Electroencephalogr Clin Neurophysiol*. 1993;86(2):132–137.
10. Le N, Vickers A, Ugoh PM, et al. Ophthalmologic Manifestations of Brainstem Stroke Syndromes. *American Academy of Ophthalmology. EyeWiki*. November 8, 2020. https://eyewiki.org/Ophthalmologic_Manifestations_of_Brainstem_Stroke_Syndromes. Accessed June 6, 2021.
11. Valko Y, Werth E, Bockisch CJ, Valko PO, Weber KP. Polysomnography reveals nystagmus from benign paroxysmal positional vertigo. *Sleep Med*. 2014;15(7):840–842.
12. Eisensehr I, Noachtar S, Strupp M, von Lindeiner H, Brandt T, Büttner U. Absence of nystagmus during REM sleep in patients with vestibular neuritis. *J Neurol Neurosurg Psychiatry*. 2001;71(3):386–389.

ACKNOWLEDGMENTS

The authors thank Angela Dawson, RPSGT, for assistance with obtaining polysomnographic images.

SUBMISSION & CORRESPONDENCE INFORMATION

Submitted for publication June 4, 2021

Submitted in final revised form October 18, 2021

Accepted for publication January 11, 2022

Address correspondence to: Umer Shoukat, MD, University of Maryland Sleep Disorders Center, 100 North Greene Street 2nd Floor, Baltimore, MD 21201; Email: umershoukatmd@gmail.com

DISCLOSURE STATEMENT

All authors have seen and approved the manuscript. Work for this study was performed at the University of Maryland Medical Center, Baltimore, Maryland. The authors report no conflicts of interest.