

# Hyperdense Cerebral Lesion in Childhood Tuberos Sclerosis: Computed Tomographic Demonstration and Neuropathologic Analysis

M. Cecilia Pinto-Lord, MD\*†, Israel F. Abrams, MD\*†, and Thomas W. Smith, MD‡

A child with focal intractable seizures and electroencephalographic evidence of a highly epileptogenic focus was found to have a high-density, wedge-shaped lesion in the left parietal region on cerebral computed tomography. The lesion extended from the ventricular to the pial surfaces and did not enhance after contrast infusion. Biopsy confirmed the diagnosis of tuberous sclerosis. Atypical features of tuberous sclerosis on computed tomography are reviewed and the possible pathogenesis of the lesion is discussed.

Pinto-Lord MC, Abrams IF, Smith TW. Hyperdense cerebral lesion in childhood tuberous sclerosis: Computed tomographic demonstration and neuropathologic analysis. *Pediatr Neurol* 1986;2:245-8.

## Introduction

Since the advent of computed tomography (CT), radiologic confirmation of tuberous sclerosis (TS) is easy, noninvasive, and without patient risk [1-9]. The CT scan often reveals intracerebral calcifications which may not be visible on conventional skull radiographs [6,7]. The majority of these calcifications are periventricular, nonenhancing lesions that correspond to the "candle gutterings" seen on the walls of the

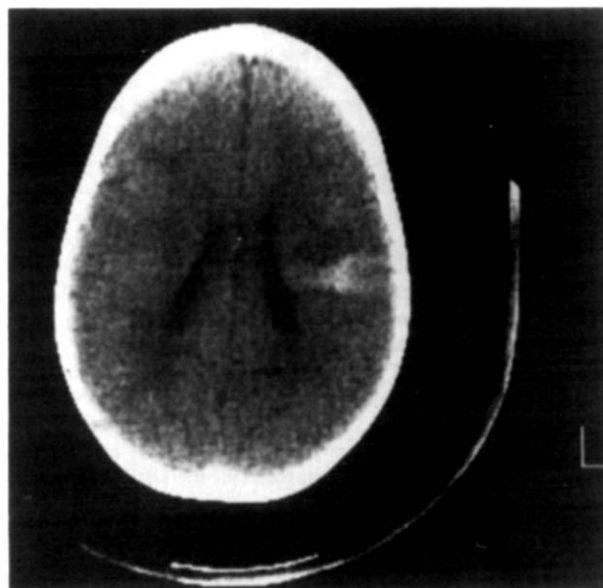


Figure 1. Unenhanced CT scan at age 17 months reveals the high density, wedge-shaped lesion in the left hemisphere extending from the pial to the ventricular surface.

lateral ventricles during neuropathologic examination. In 12% of patients with TS in the Mayo Clinic series, cortical calcifications were often found in the frontal lobes but always associated with calcifications in the periventricular region [6]. Occasionally, calcifications in the cerebellar cortex are found. Hypodense areas in the cerebral hemispheres, which correspond to the cortical tubers [7] or to diffuse demyelination in white matter [10], are seen less frequently on CT in TS. Ventricular enlargement, which is often asymmetric, is seen frequently [11]. Rarely, isodense enhancing tumor masses (subependymal giant cell astrocytoma) obstruct the foramen of Monro, producing hydrocephalus.

Apparently, an intracerebral hemispherical wedge-shaped, high-density lesion on CT has not been described previously in TS. We present a case of TS in which the apex of the wedge extended to the ventricular surface and the base extended to the pial surface. Biopsy of the lesion demonstrated histologic features consistent with a cortical tuber. The high-density lesion did not enhance with contrast material.

## Case Report

A 13-month-old white male experienced focal seizures and had an abnormal CT scan. He was born prematurely at 34 weeks gestation, weighing 2,000 grams. His Apgar score was 8 at both 1 and 5 minutes. Because of respiratory distress, he was transferred to the neonatal intensive care unit at 3 hours of age where he remained for a week. The diagnosis of transient tachypnea was made; he required oxygen for 12 hours. Frequent episodes of apnea and bradycardia

From the Departments of \*Pediatrics, †Neurology, and ‡Pathology (Neuropathology); University of Massachusetts Medical School; Worcester, Massachusetts.

Communications should be addressed to: Dr. Abrams; University of Massachusetts Medical School; 55 Lake Avenue, North; Worcester, MA 01605. Received March 7, 1986; accepted April 4, 1986.

were observed for which no cause was found. He also developed neonatal hyperbilirubinemia that was treated with phototherapy.

Although healthy at the time of discharge, he had several hospitalizations during the first year of life because of bronchitis and gastroenteritis. His developmental milestones were normal; he crawled at 6 months, cruised at 10 months, and walked at 14 months. His first words were at 8 months, and by 22 months he could use 3-word sentences.

At 12 months of age, he experienced seizures during which there was right arm extension at the side, associated with staring, head-nodding, and later bilateral eyelid fluttering that lasted 10-15 seconds. These symptoms occurred in clusters, 4-6 times daily.

His initial evaluation at age 13 months revealed a normal neurologic status, but 3 small achromic skin patches that enhanced with ultra-violet light, were seen on his trunk and limbs. No retinal phakomas were observed. An electroencephalogram (EEG) was abnormal; there were frequent bursts of focal spikes and 1-1.5 Hz multiple spike-and-slow-wave complexes in the left central region. Cranial CT revealed a wedge-shaped area of increased density (45-50 Hounsfield units) in the left parietal lobe; the apex was at the ventricular surface and base was at the pial surface. The area did not enhance with contrast medium and exerted no mass effect. The patient was treated initially with phenobarbital, but better seizure control was obtained later with carbamazepine and valproate. Figure 1 depicts the unchanged CT scan at 17 months of age.

The EEG had worsened 6 months later with the presence of independent right and left centrottemporal spike discharges which occasionally were synchronous. A third CT scan 10 months later was unchanged (Fig 2). A left carotid arteriogram demonstrated no definite abnormalities, and renal ultrasound studies were normal. Because of worsening seizures, the patient had a craniotomy and a biopsy of the left parietal lesion at age 30 months.

The cortical surface appeared and felt normal. Microscopic examination of the resected brain tissue revealed marked architectural disorganization and loss of normal lamination of the cerebral cortex. Large atypical neuronal and glial cells were scattered haphazardly throughout a densely gliotic neuropil (Fig 3). Included among the abnormal neurons were giant pyramidal-shaped cells having abundant Nissl bodies and well-developed, yet disoriented, neuritic processes. Astrocytes were increased in number, giving the lesion a

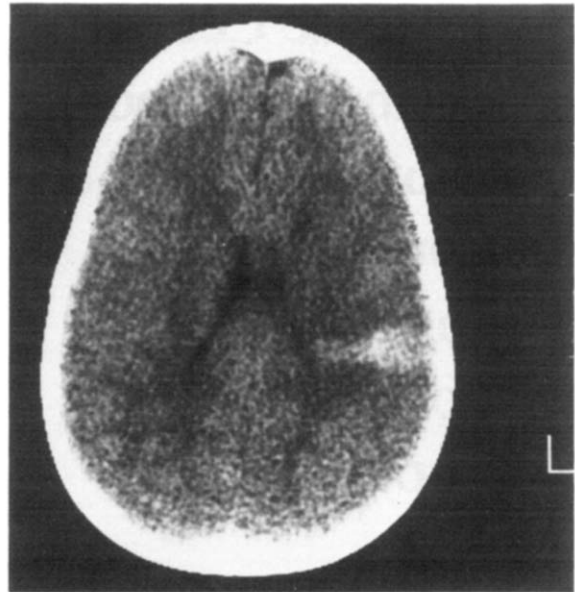


Figure 2. Repeat unenhanced CT scan at age 27 months depicts the lack of change in the wedge-shaped left hemispherical lesion.

hypercellular appearance. Many of the astrocytes had plump eosinophilic cytoplasm, and large, often multiple nuclei. Many gemistocytic forms were observed. Some regions contained large numbers of small concentrically-laminated calcospherites (Fig 4). These histologic features were interpreted as consistent with a cortical tuber.

An achromic patch of skin was biopsied as well as adjacent normal skin. Detailed examination, which included electron microscopy, revealed normal melanocytes that appeared somewhat smaller than usual in the "achromic" skin. The melanocytes in the normal skin were unremarkable. The skin biopsy findings were considered to be nonspecific.

Postoperatively, he did well. When 38-months-old, he averaged one absence seizure (5-second duration) per month. He remains left-

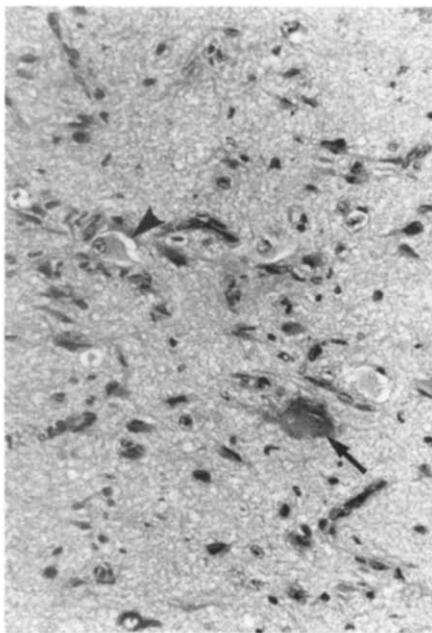


Figure 3. Section of resected cortex demonstrates large atypical neuron (arrow) and astrocyte (arrowhead) in a densely gliotic neuropil. Hematoxylin and eosin stain, x300.

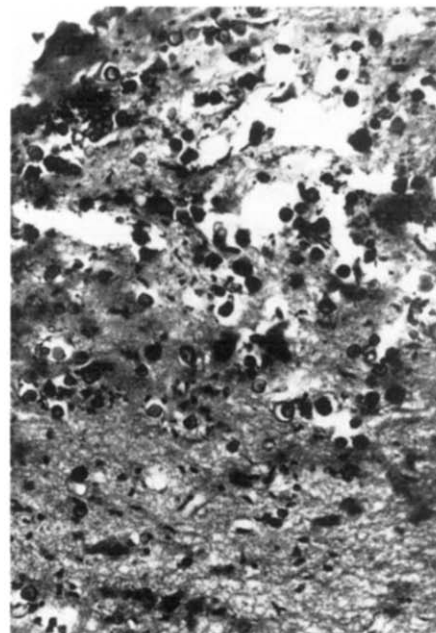


Figure 4. Large numbers of concentrically-laminated calcospherites in the abnormal cortex. Hematoxylin and eosin stain, x300.

handed as is his maternal grandmother. No facial adenoma sebaceum have appeared. He speaks in sentences of 6-8 words, runs well, climbs stairs unassisted by holding onto a railing, and is toilet trained. He continues to receive carbamazepine and valproate. His EEG is normal.

### Discussion

Tuberous sclerosis is a disease characterized clinically by adenoma sebaceum, mental deficiency, and seizures. Intracerebral calcifications are the most frequent radiographic feature of TS. The calcifications, better detected by CT than by skull radiography [3-7], are usually located in the subependymal nodules seen neuropathologically. Hypodense peripheral hemispherical lesions are found less frequently because they do not enhance [7]. They correspond to the cortical tubers that are found scattered throughout the cortex. The use of positron emission tomography (PET) scanning in the investigation of epileptic foci demonstrates the presence of hypometabolic areas that prove to be tubers upon resection [23]. In some cases, the tubers may manifest only as epileptic foci on EEG or clinically as seizures [23]. Diagnostic difficulties are encountered in some children who have neither cutaneous lesions nor subependymal calcifications [3,7].

Our patient presented with focal seizures and an atypical wedge-shaped, hyperdense lesion on CT which apparently has not been described previously in TS. Because of the patient's worsening clinical state, a cerebral biopsy was performed. Neuropathologic examination revealed findings consistent with a cortical tuber. The high content of calcium present within the lesion probably accounts for its appearance on CT scan. The well-circumscribed nonenhancing nature of this lesion tends to exclude heterotopia which would be more heterogeneous and poorly delineated. We do not consider the histologic features of the lesion in our patient to be typical of "focal cortical dysplasia", as described by Taylor et al. [24].

Several etiologic possibilities have been suggested to explain the pathogenesis of cortical tubers [1]:

(1) Disturbances of the local environment related to changes in the vasculature have been proposed, although no such abnormalities have been found in tubers [22]; and,

(2) The presence of genetic coding abnormalities in both the neuronal and glial populations with retention of mitotic potential [1,13,14]. This theory, however, contradicts some basic principles of neuronal formation and migration.

Recent studies regarding early developmental events such as cell lineage, acquisition of neuronal position, and the areal and laminar organization of the cortex are precise [15-17]. These principles may bring insight to the pathogenesis of the histology of TS.

Cortical neurons arise in the ventricular and subventricular zones [15]. All neurons must migrate to final positions in the cortex after final cell division,

along the elongated, radially arranged glial fibers [18,19]. Guidance mechanisms exist between the glial fibers and the migrating neurons [17,20,21]. Subsequent events indicate that neurons, which arise at a precise point along the ventricular surface, will register at a similar location in the cortex. The relationship between the cell precursors in the ventricular zone and their progeny in the cortex is maintained despite the expansion of the cerebral surface [15]. Thus, the ventricular cells contain a primordial map of the future cortex. The glial guidance system prevents mismatches and determines specific arrangements of topography in a columnar pattern. The hierarchical organization within each radial columnar unit is determined by temporal factors, such as the rate of cell proliferation and migration [17]. The radial glial fibers assure the columnar arrangement of the adult cortex and reduce the need for large amounts of genetic information necessary for proper neuronal migration and final position in cortex.

Disruption of the relationship between the glial fiber and the neuron migrating along it will cause an abnormally constructed cortex, as demonstrated in the mutant "Reeler" mouse [20,21]. In this strain, an abnormal neuron/glial interaction results in the disruption of the cortical neurons' contact with the axon-rich strata and therefore their final position in the future cortex. Consequently, the cell morphology and topology are altered, causing bizarre neuronal shapes to be dispersed within the cortex.

The morphology of the abnormal neurons within cortical tubers in TS [5,12-14] is reminiscent of those seen in the mutant "Reeler" mouse, having abnormal neuronal/glial interaction [18,19]. The basic defect in TS may be in the circumscribed areas of the glial cells in the ventricular zone where a mismatch of genetic codes occurs. This may cause cortical tubers to contain malformed neurons which use the genetically defective radial glial fibers and cells, as identified by immunocytochemical studies of glial fibrillary acidic protein (GFAP) [25]. Furthermore, part of the same glial population arrested in the ventricular zone would be the source of clusters of large glial cells forming the subependymal nodules ("candle gutterings") on the ventricular wall [26] which occur in almost all cases of TS. These lesions could be the result of disrupted genetic information in circumscribed populations of abnormal glial cells. Subependymal giant cell astrocytomas, located near the foramina of Monro, occur in about 10% of TS patients. They include cells that react with neuronal specific enolase and the 68Kd neurofilament subunit and are often negative for GFAP [27,28]. Perhaps the glial (or neuronal) cells, which originate presumably in the embryonic germinal matrix, are prevented from migrating to the cortex by the abnormal radial glial cells and later divide aberrantly to form tumors [29].

## References

- [1] **Fitz CR**, Harwood-Nash DCF, Thompson JR. Neuroradiology of tuberous sclerosis in children. *Radiology* 1974;110:635-42.
- [2] **Nagib MG**, Haines SJ, Erickson DL, Mastri AR. Tuberous sclerosis: A review for the neurosurgeon. *Neurosurgery* 1984;14:93-8.
- [3] **Lee BCP**, Gawler J. Tuberous sclerosis: Comparison of computed tomography and conventional neuroradiology. *Radiology* 1978;127:403-7.
- [4] **Newmark H, III**, Bhagwanani DG, Rishi US, Mellon WS, Jr, Hafeez M, Kant N. Tuberous sclerosis evaluated by computerized tomography. *Comput Radiol* 1982;6:287-93.
- [5] **Huttenlocher PR**, Heydemann PT. Fine structure of cortical tubers in tuberous sclerosis: A golgi study. *Ann Neurol* 1984;16:595-602.
- [6] **Gomez MR**, Mellinger JF, Reese DF. The use of computerized transaxial tomography in the diagnosis of tuberous sclerosis. *Mayo Clin Proc* 1975;50:553-6.
- [7] **Gardeur D**, Palmieri A, Mashaly R. Cranial computed tomography in phakomatoses. *Neuroradiology* 1983;25:293-304.
- [8] **Sharp D**, Robertson DM. Tuberous sclerosis in an infant of 28 weeks gestational age. *Can J Neurol Sci* 1983;10:59-62.
- [9] **Glass RBJ**, Mendelsohn DB, Hertzanu Y. Atypical findings on computed tomography in tuberous sclerosis. *S Afr Med J* 1984;66:145-6.
- [10] **Garrick R**, Gomez MR, Houser OW. Demyelination of the brain in tuberous sclerosis — Computed tomography evidence. *Mayo Clin Proc* 1979;54:685-9.
- [11] **Gomez MR**. Tuberous sclerosis. New York: Raven Press, 1979.
- [12] **Trombley IK**, Mirka SS. Ultrastructure of tuberous sclerosis: Cortical tuber and subependymal tumor. *Ann Neurol* 1981;9:174-81.
- [13] **Probst A**, Ohnacker H. Sclerose tubereuse de bourneville chez un premature. *Acta Neuropathol (Berl)* 1977;40:157-61.
- [14] **Arseni C**, Alexanu M, Horvat L, Alexianu D. Fine structure of atypical cells in tuberous sclerosis. *Acta Neuropathol (Berl)* 1972;21:185-93.
- [15] **Rakic P**, Goldman-Rakic PS. Development and modifiability of the cerebral cortex. *Neurosciences Res Prog Bull* 1982;20:433-61.
- [16] **Rakic P**. Genetic and epigenetic determinants of local neuronal circuits in the mammalian central nervous system. In: Schmitt FO, Worden FG, eds. *The neurosciences: Fourth study program*. Cambridge: MIT Press, 1979;102-27.
- [17] **Rakic P**. Developmental events leading to laminar and areal organization of the neocortex. In: Schmitt FO, Worden FB, Adelman G, Dennis SG, eds. *The organization of the cerebral cortex*. Cambridge: MIT Press, 1981;7-28.
- [18] **Schmechel DE**, Rakic P. A golgi study of radial glial cells in developing monkey telencephalon: Morphogenesis and transformation into astrocytes. *Anat Embryol* 1979;156:115-52.
- [19] **Levitt P**, Rakic P. Immunoperoxidase localization of glial fibrillary acid protein in radial glial cells and astrocytes of the developing rhesus monkey brain. *J Comp Neurol* 1980;193:417-48.
- [20] **Pinto-Lord MC**, Caviness, VS. Determinants of cell shape and orientation: A comparative golgi analysis of cell-axon interrelationships in the developing neocortex of normal and reeler mice. *J Comp Neurol* 1979;187:49-70.
- [21] **Pinto-Lord MC**, Evrard P, Caviness VS, Jr. Obstructed neuronal migration along radial glial fibers in the neocortex of the reeler mouse: A golgi-EM analysis. *Dev Brain Res* 1982;4:379-93.
- [22] **Ribadeau-Dumas JL**, Poirier J, Escourolle R. Etude ultrastructurale des lesions cerebrales de la sclerose tubereuse de Bourneville. *Acta Neuropathol (Berl)* 1973;25:259-70.
- [23] **Szelies B**, Herholz K, Heiss WD, et al. Hypometabolic cortical lesions in tuberous sclerosis with epilepsy: Demonstration by positron emission tomography. *J Comput Assist Tomogr* 1983;7:946-53.
- [24] **Taylor DC**, Falconer MA. Focal dysplasia of the cerebral cortex in epilepsy. *J Neurol Neurosurg Psychiatry* 1971;34:369-87.
- [25] **Nashimura M**, Takashima S, Takeshita K, Tanaka J. Immunocytochemical studies on a fetal brain of tuberous sclerosis. *Pediatr Neurol* 1985;1:245-8.
- [26] **Stefansson K**, Wollmann R. Distribution of glial fibrillary acidic protein in central nervous system lesions in tuberous sclerosis. *Acta Neuropathol (Berl)* 1980;52:135-40.
- [27] **Stefansson K**, Wollman R. Distribution of neuronal specific protein, 14-3-2, in central nervous system lesions of tuberous sclerosis. *Acta Neuropathol (Berl)* 1981;53:113-7.
- [28] **Bonnin JM**, Rubinstein LJ, Pappasozomenos S Ch, Marangos PJ. Subependymal giant cell astrocytoma: Significance and possible cytogenetic implications of an immunohistochemical study. *Acta Neuropathol (Berl)* 1984;62:185-93.
- [29] **Huttenlocher PR**. Tuberous sclerosis. In: Matthew WB, Glaser GH, eds. *Recent advances in clinical neurology (IV)*. New York: Churchill, 1984;281-98.