

# Late-Onset Vaccine-Induced Immune Thrombotic Thrombocytopenia (VITT) with Cerebral Venous Sinus Thrombosis

Maruan Saleh,<sup>a</sup> Julian Zimmermann, MD,<sup>a</sup> Nils C. Lehnen, MD,<sup>b,c</sup>  
Bernd Pötzsch, MD,<sup>d</sup> and Johannes M. Weller, MD<sup>a</sup>

---

**Objectives:** Vaccine-induced thrombotic thrombocytopenia (VITT) is a rare complication after adenoviral vector vaccination against COVID-19 reported up to 24 days after ChAdOx1 nCoV-19 (AZD1222) vaccination. This report describes a case with a significantly later onset of VITT with cerebral venous sinus thrombosis. **Case description:** We report a 42-year-old woman presenting to the emergency department 53 days after AZD1222 vaccination with sudden onset sensory aphasia and an 18-day history of headache. Cranial computed tomography (CT) showed acute intracranial hemorrhage and CT venogram demonstrated thrombosis of the left vein of Labbé and transverse and sigmoid sinus. D-dimers were elevated and despite a normal platelet count, platelet-activating anti-PF4 antibody testing was positive, confirming the diagnosis of VITT. The patient was treated with intravenous immunoglobulins and argatroban, and was discharged without any neurological deficit on day 12. **Conclusion:** Our report of VITT with symptom onset on day 35 and diagnosis of cerebral venous sinus thrombosis on day 53 after AZD1222 vaccination significantly enhances the time window during which VITT may occur.

**Key Words:** COVID-19—VITT—Cerebral venous sinus thrombosis—VIPIT—ChAdOx1 nCoV-19—PF4

© 2022 Elsevier Inc. All rights reserved.

---

## Case presentation

A previously healthy 42-year-old woman presented to the emergency department with acute onset fluent aphasia. Further clinical examination was unremarkable. Emergency computed tomography (CT) of the head showed two small intracranial hemorrhages of the left

temporal lobe and a hyperdense cerebral sinus. CT venogram confirmed cerebral venous sinus thrombosis (CVST) of the left vein of Labbé and sigmoid and transversal sinus (Fig. 1). As the paramedic reported ChAdOx1 nCoV-19 (AZD1222) vaccination 2 weeks before, vaccine-induced thrombotic thrombocytopenia (VITT) was suspected and the patient was treated with intravenous immunoglobulins (1 g/kg over 2 days) and argatroban.<sup>1</sup> Blood tests upon admission revealed elevated D-dimers of 0.96 mg/l but no thrombocytopenia (293.000 platelets/ $\mu$ l). Further work-up demonstrated platelet-activating antibodies against platelet factor 4 (PF4) without previous heparin exposure, confirming the diagnosis of VITT.<sup>2</sup> After remission of aphasia on day 2, the patient clarified that the vaccination has been performed 53 days before onset of aphasia and reported a 18-day history of headache, which has been managed conservatively as head CT 14 days prior to admission was deemed unremarkable. Platelet

---

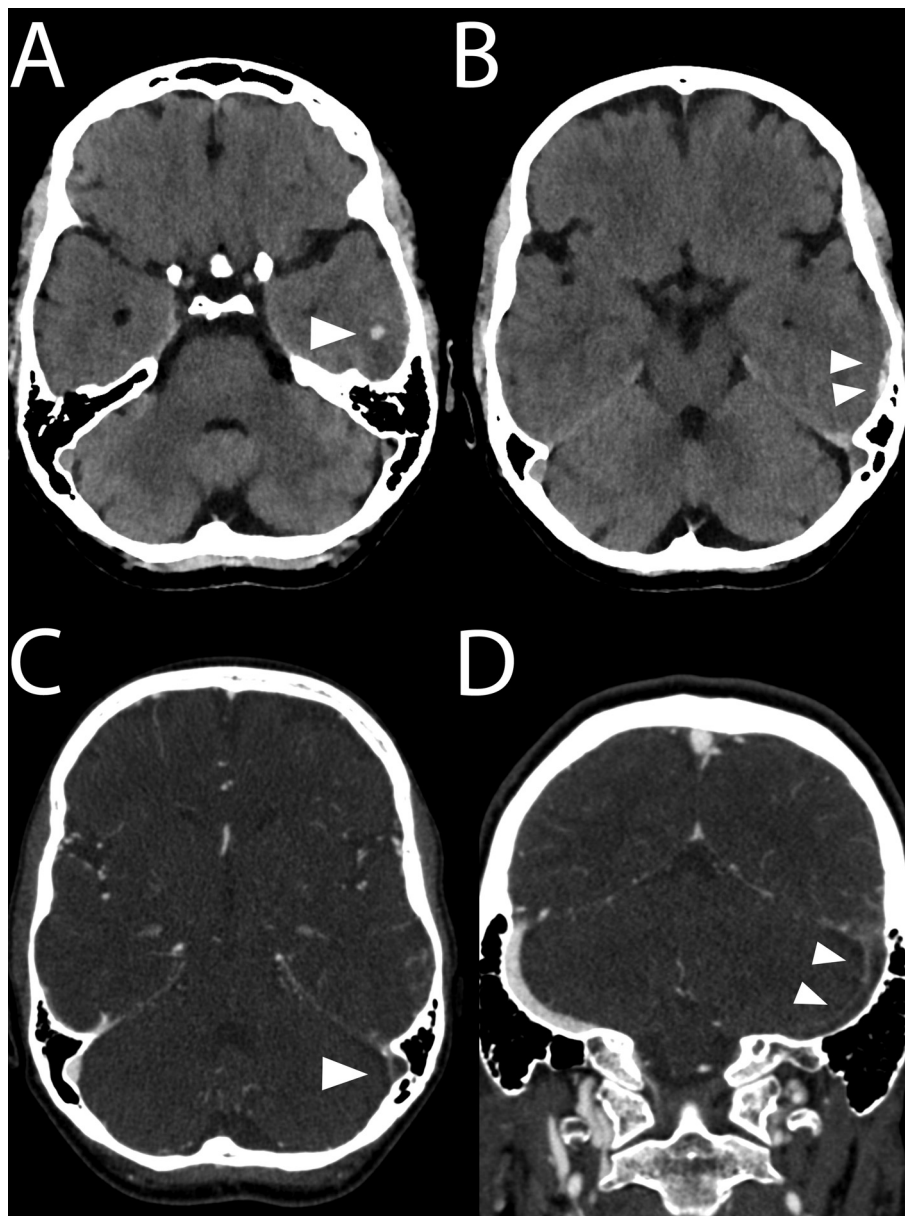
From the <sup>a</sup>Department of Neurology, University Hospital Bonn, Venusberg Campus 1, Bonn 53127, Germany; <sup>b</sup>Department of Neuro-radiology, University Hospital Bonn, Bonn, Germany; <sup>c</sup>Research Group Clinical Neuroimaging, German Center for Neurodegenerative Diseases, Bonn, Germany; and <sup>d</sup>Institute of Experimental Hematology and Transfusion Medicine, University of Bonn, Bonn, Germany.

Received August 9, 2021; revision received December 22, 2021; accepted January 6, 2022.

Corresponding author. E-mail: [Johannes.Weller@ukbonn.de](mailto:Johannes.Weller@ukbonn.de).  
1052-3057/\$ - see front matter

© 2022 Elsevier Inc. All rights reserved.

<https://doi.org/10.1016/j.jstrokecerebrovasdis.2022.106311>



**Fig. 1.** Cerebral imaging of a 42-year-old woman with headache and sudden onset sensory aphasia 53 days after ChAdOx1 nCoV-19 vaccination. (A,B) Cranial CT reveals intracranial hemorrhage of the left temporal lobe. (C,D) Contrast-enhanced CT venogram shows thrombosis of the left transverse and sigmoid sinus (arrowheads).

counts remained stable and within the normal range throughout hospitalisation. The patient continued to improve, was switched to oral anticoagulation with dabigatran (150mg bi-daily) after 1 week and discharged without any neurologic deficit on day 12. During monthly follow-up, decreasing activity of platelet-activating PF4 antibodies was detected, but due to residual CVST on MRI after 3 months, oral anticoagulation was continued for further 9 months.

### Discussion

During the ongoing global SARS-CoV-2 pandemic, several COVID-19 vaccines were developed. After adenoviral

vector-based vaccination against COVID-19, an increasing number of cases with thrombocytopenia and thrombosis at unusual sites, mostly cerebral or sinus vein thrombosis, have been reported.<sup>2–8</sup> To date, the reported time window of VITT symptom onset after AZD1222 vaccination ranges from 5 to 24 days after vaccination.<sup>2,4,8</sup> We report a case of CVST due to VITT after AZD1222 vaccination with a significantly later symptom onset, as headache started on day 35 after vaccination, and CVST was first diagnosed on day 53. Admittedly, diagnosis was facilitated by the initially incorrectly reported vaccination date. The good clinical outcome despite delayed diagnosis and the absence of thrombocytopenia upon diagnosis suggest

a less severe case of VITT in our patient, although transient thrombocytopenia before admission cannot be excluded.

Based on this report, patients presenting with symptoms suggestive for thrombotic events far beyond the previously reported time window of up to 24 days after AZD1222 vaccination should be urgently evaluated with laboratory tests (including platelet count, D-dimers and anti-PF4 platelet activating antibodies) and for presence of venous thromboses. Moreover, VITT may occur without thrombocytopenia, and population-based analyses of VITT might consider extended time frames beyond 28 days.<sup>9</sup>

### Informed consent

Written informed consent was provided by the patient.

### Declaration of Competing Interest

None

### References

1. Oldenburg J, Klamroth R, Langer F, et al. Diagnosis and management of vaccine-related thrombosis following AstraZeneca COVID-19 vaccination: guidance statement from the GTH. *Hamostaseologie* 2021;41:184-189.
2. Greinacher A, Thiele T, Warkentin TE, et al. Thrombotic thrombocytopenia after ChAdOx1 nCov-19 vaccination. *N Engl J Med* 2021;384:2092-2101.
3. Cines DB, Bussel JB. SARS-CoV-2 vaccine-induced immune thrombotic thrombocytopenia. *N Engl J Med* 2021;384:2254-2256.
4. Scully M, Singh D, Lown R, et al. Pathologic antibodies to platelet factor 4 after ChAdOx1 nCov-19 vaccination. *N Engl J Med* 2021;384:2202-2211.
5. Schulz JB, Berlit P, Diener HC, et al. COVID-19 vaccine-associated cerebral venous thrombosis in Germany. *Ann Neurol* 2021;90:627-936.
6. Gessler F, Schmitz AK, Dubinski D, et al. Neurosurgical considerations regarding decompressive craniectomy for intracerebral hemorrhage after SARS-CoV-2-vaccination in vaccine induced thrombotic thrombocytopenia-VITT. *J Clin Med* 2021;10:2777.
7. Krzywicka K, Heldner MR, Sánchez van Kammen M, et al. Post-SARS-CoV-2-vaccination cerebral venous sinus thrombosis: an analysis of cases notified to the European medicines agency. *Eur J Neurol* 2021;28:3656-3662.
8. Tiede A, Sachs UJ, Czwalinna A, et al. Prothrombotic immune thrombocytopenia after COVID-19 vaccine. *Blood* 2021;138:350-353.
9. Pottgård A, Lund LC, Karlstad Ø, et al. Arterial events, venous thromboembolism, thrombocytopenia, and bleeding after vaccination with Oxford-AstraZeneca ChAdOx1-S in Denmark and Norway: population based cohort study. *BMJ* 2021;373:n1114.