
Comments, Opinions, and Reviews

Late-Life Migraine Accompaniments — Further Experience

C.M. FISHER, M.D

SUMMARY In 1980, 120 cases with late-life migrainous accompaniments resembling transient ischemic attacks were presented. In the present paper, 85 further cases examined in the past five years are analyzed. The findings support the concept advanced previously. In general, the cases are divided into the same categories: visual — 21 cases, visual and paresthesias — 6, visual and speech disturbance — 2, visual, paresthesias and speech disturbance — 3, visual, paresthesias, speech disturbance, and weakness — 20, visual and brainstem symptoms — 3, and cases without visual symptoms — 32. The ages ranged from 40 to 73 years. Headache occurred in association with the episodes in only 40% of cases. There was a history of recurrent headache in 65%. The condition can justifiably be regarded as benign. Migrainous accompaniments account for some of the cases of transient ischemia with normal angiograms. Knowledge of the condition helps in the planning of rational management.

Stroke Vol 17, No 5, 1986

IN 1980, the proposition was tentatively advanced that transient migrainous accompaniments — scintillating scotomas, numbness, aphasia, dysarthria, motor weakness, etc. — may occur for the first time after the age of 45 years and complicate the interpretation of TIAs of cerebrovascular origin.¹ From a series of 121 cases, 35 case histories were presented in some detail as examples of the phenomenon. Often there was no accompanying headache and no past history of migraine or significant headache. The principal evidence that the spells were migrainous was that they closely resembled the auras of young migraineurs. Since only clinical proof of the concept could be mustered, it was necessary to exercise caution in drawing conclusions and inferences. The category, late-life migrainous accompaniments, provided a diagnostic niche for many cases with a remarkably atypical variegated symptomatology that almost defied placing them in the vascular category.

The present paper, which may be considered a progress report, contains an analysis of 85 additional cases encountered in the five years since the last report. Our further experience clearly supports the general concept, although again only clinical evidence can be brought forward.

As already mentioned, cases of this type are difficult to classify into a limited number of well-delineated categories. In the previous report, the 120 cases were arranged in 9 categories according to the type of accompaniments: visual (blindness, homonymous hemianopia and blurred vision); visual and paresthesias;

visual and speech disturbance (aphasia, and/or dysarthria); visual and brainstem symptoms; visual, paresthesias and speech disturbance; visual, paresthesias, speech disturbance and weakness; only non-visual accompaniments (paresthesias, speech disturbance, weakness, etc.); recurrence of old stroke deficits; and miscellaneous. This classification emphasizes the frequency with which visual symptoms provide the clue to the migrainous nature of the cases. When visual accompaniments are missing, the measure of uncertainty with which the diagnosis of migraine is entertained increases greatly.

The main criteria supporting the diagnosis of late-life migrainous accompaniments may be briefly recapitulated as follows: 1. The presence of visual symptoms — scintillating scotoma, etc. provides an important clue. 2. A gradual “build-up,” expansion and migration of the scintillating display, a phenomenon which does not occur in cerebrovascular disease. 3. A “march” of paresthesias, a feature which does not occur in cerebrovascular disease. 4. The serial progression from one accompaniment to another, for example, from visual to paresthesias to dysphasia, a course that does not occur in cerebrovascular disease. 5. The occurrence of 2 or more identical spells, an event that helps to exclude embolism. When there has been only one spell, cerebral embolism is a possibility and the diagnosis must then be based on the presence of unequivocal specific migrainous features. 6. Headache in association with the spell (50% of cases). 7. A duration of the episode in the range of 15 to 25 minutes whereas 90% of TIAs associated with carotid or basilar artery disease last less than 15 minutes. 8. The occurrence of a “flurry” of accompaniments, generally in the 50–60 year old age group is in keeping with our experience thus far. 9. A generally benign course without permanent sequelae. 10. Exclusion of cerebral thrombosis, embolism, dissection, subclavian steal, epilepsy, thrombocythemia, polycythemia, hyperviscosity syndromes, and lupus anticoagulant. 11. Normal an-

From the Neurology Service of the Massachusetts General Hospital, Boston, Massachusetts 02114.

This study was supported by a grant from the Freed Foundation, Washington, D.C. Presented at the Academy of Medicine, Toronto, Canada, December 4, 1984.

Address correspondence to: C.M. Fisher, M.D., Neurological Service, Massachusetts General Hospital, Fruit Street, Boston, MA 02114 U.S.A.

Received October 18, 1985; accepted April 8, 1986.

giography. This excludes thrombosis of arteries greater than 1.5 mm in diameter. And 12. recurrence of essentially identical spells over a period of 5 to 10 years. It is unlikely that arteriosclerotic thrombosis would have such a prolonged course.

The New Series

In all, 85 new cases have been enrolled for analysis. The degree of confidence with which the cases were selected varied greatly but generally they had to fulfill the majority of the criteria already outlined.

Males accounted for 60% of the cases, females for 40%. The distribution by age was as follows: 40–49 years, 23%; 50–59 years, 40%, 60–69 years, 20%; and 70 years and over, 16%.

The number of spells was as follows: only one spell, 27%; 2 spells, 12%; 3–10 spells, 33%; and more than 10, 28%. Headache was associated with the episodes in 40% of the cases. There was a history of recurrent headaches in the past in 65% of cases.

The rule that migrainous accompaniments last on the average 15–25 minutes is an oversimplification as shown in table 1 which demonstrates that spells are as brief as one minute or as long as 3 days or more.

The Classification

The classification in the present paper is much the same as that used previously and although far from ideal because of the great variability of the cases, it at least conveys a general idea of the types of case and their distribution (table 2). Again, patients who had only recurrent scintillating scotomas were excluded whereas when scintillations were associated with other accompaniments, they assumed almost diagnostic importance. The cases with blindness were totally blind or almost so for up to 8 minutes. In the group with homonymous hemianopia, the patient suddenly saw only one-half of the visual field, usually without accompanying scintillations or other luminous display. Some patients had homonymous hemianopia in some spells and total blindness in other spells suggesting that blindness was due to bilateral homonymous hemianopia. In some cases the visual deficits took the form of bilateral superior or inferior altitudinal quadranopia. Patients in the category, blurred vision, had difficulty focussing or objects were seen as if under water or through water on a windshield or through heat waves

TABLE 1 Duration of the Migrainous Episodes

| Duration of Spells | |
|--------------------|-----|
| 1 min or less | 4% |
| 1–5 min | 25% |
| 6–15 min | 20% |
| 16–30 min | 18% |
| ½–1 hr | 4% |
| 1–4 hrs | 11% |
| 5–24 hrs | 10% |
| 24–72 hrs | 3% |
| >72 hrs | 3% |

TABLE 2 Classification of Patients in the Two Series with Frequency Distribution

| Classification of Patients with Migrainous Accompaniments | Initial Series | Present Series |
|---|----------------|----------------|
| Visual (excluding scintillating scotoma) | | |
| Blindness | 14 | 3 |
| Homonymous hemianopia | 5 | 7 |
| Blurred vision, difficulty focussing | 6 | 9 |
| Visual and paresthesias | 18 | 6 |
| Visual and speech disturbance (dysarthria or aphasia) | 7 | 2 |
| Visual, paresthesias and speech disturbance | 7 | 3 |
| Visual, paresthesias, speech disturbance and paresis | 7 | 20 |
| Visual and brain stem symptoms | 14 | 3 |
| No visual accompaniments — only paresthesias, speech disturbance, paresis, etc. | 25 | 32 |
| Totals | 103 | 85 |

over a hot pavement. At least some of these patients qualified for the category "spasm of accommodation."

Cases of benign transient monocular blindness occurring in the absence of detectable cerebrovascular disease, although widely accepted as "migrainous" are not included in the present series. This is not to diminish their potential importance as a migrainous phenomenon. Unaccompanied visual symptoms were at one time regarded as evidence of basilar artery ischemia but it continues to be our experience that this is rarely so and late-life migraine is a much more common cause.

The patients in the next five categories had *visual manifestations* as the main feature to which were added other accompaniments in increasing complexity. The most common visual display was the scintillating scotoma, but in addition there was a phantasmagoria of visual effects almost beyond description and which might not be easily recognized as migrainous. While often brilliant, they were at times rather faint, apt to be disregarded by the patient and elicited only by direct questioning. The visual symptoms did not always occur at the same time as the other accompaniments but could precede or follow by a few hours or days or there was increased visual activity in the background during the period in which accompaniments were occurring.

Paresthesias (tingling, pins-and-needles, numbness, etc.) were next in frequency to visual symptoms as a migrainous accompaniment. The variations in site of onset, rapidity of march, parts involved, duration, severity, frequency of recurrence, and relationship to other accompaniments were almost limitless. When numbness occurred by itself the differential diagnosis included pure sensory TIAs resulting from transient lacunar ischemia in the thalamus.² In typical migraine, the march is slower than in sensory seizures in which it is a matter of seconds.

The *speech disturbance* could be a dysphasia or a dysarthria. The latter may be the result of numbness, sensory loss, or weakness of the tongue and throat.

Dysphasia, which occurred in 19 of the present cases, has not been precisely characterized. The descriptions included: difficulty finding words, words come out other than those in my mind; unable to say what I wanted to; gibberish; jargon aphasia; unintended words come out; unable to understand what was said to me; difficulty naming objects; difficulty getting words out; reading made jargon in my mind; and difficulty speaking and understanding.

Weakness or paralysis, particularly brief episodes, is in the minds of clinicians a manifestation not readily associated with migraine. Despite a reluctance to include such cases in the migraine ranks, it is becoming more certain as experience grows that spells of weakness or paralysis do occur in the late-life migraine group often in a setting of other accompaniments that clearly stamps the whole episode as migrainous. (The prolonged paralysis of young familial hemiplegic migraineurs is well known as is the alternating migrainous hemiplegia of infants and children, but these are not under discussion here.) In some cases, numbness of a limb is so marked the patient claims the part cannot be moved, possibly a correct assertion since a profound sensory deficit can cause a paralysis which can be overcome by visual cues and special effort. Sagging of one side of the face always reflects weakness even in the presence of severe sensory loss, at least sensory loss has not been shown to cause facial weakness. In support of the concept of migrainous weakness, it is reassuring to find instances of dramatic transient weakness in *young* migraineurs as illustrated in the following cases.

Case Studies

Case 1

A healthy man, aged 30, for 10 years had recurrent high intensity throbbing headaches across the forehead lasting up to 3 hours, associated with nausea and photophobia. The headaches were ushered in by the development of tunnel vision and tiny circles of light moving about in central vision. There was a 5 minute build-up and headache began after 20 minutes; the total duration of the visual display was up to 60 minutes.

One morning the patient got up at 5:30 a.m. to go to the bathroom and while there, began to shiver and feel extremely cold. As he got back into bed he was suddenly seized with a most peculiar and alarming sensation deep in his head associated with a feeling he would black out or his body would fly apart. He was kneeling on all fours on the bed when in a flash he developed numbness and paralysis of the left side and toppled over on that side. He thought he was lying on a baseball bat or something similar and found it was his totally paralyzed arm lying twisted beneath him. The left side of the face was numb. The jaw hung down and speech was slurred. He retained his mental acuity and told his wife to call for an ambulance. Movement of the toes soon returned. He could move the arm to some extent after 30 minutes and at the end of 3 hours was back to normal. Two and one half hours from the onset he experienced a sharp pain in the right occiput

and developed blurred vision in the left visual field much like that in his ordinary migraine spells. Two days later the patient awakened with numbness of the left hand which slowly spread up the arm and onto the face. He recalled that 6 years before while playing hockey he felt cold and suddenly the left hand and arm became numb and hung helplessly at his side; speech was slurred. He thought recovery had occurred in 30 seconds.

Case 2

A girl aged 13 while sitting in her classroom suddenly was unable to see to the right side. This lasted 15 minutes when a left sided headache began associated with vomiting. As the headache developed, the patient noted tingling of her right hand and arm lasting 30 minutes. In the subsequent 4 weeks she had 4 or 5 further spells of weakness of the right hand and arm lasting 20 minutes without associated visual disturbance or headache. She then had a spell of numbness lasting 24 hours.

Thirty-one patients of the new series had weakness in some degree. At times the paralysis came on so suddenly it was difficult to conceive of an underlying mechanism encompassed by present-day concepts of migraine. In several instances, it was said the arm hung limply at the side.

The following case is an unusual example of bilateral paralysis.

Case 3

A woman, aged 60, for 11 years had one or two spells each year in which a visual display preceded literally total paralysis of her body. The spells started with sparkling lights in her vision and increasing blurriness until sight was lost except for light and form. After 10 or 15 minutes her speech became slurred, her arms and legs became progressively weaker and in 15 to 20 minutes she was totally limp and paralyzed. She lay immobile unable to speak or make a sound. Vision was blotted out by the display of lights. Her eyes remained open, eye movements were present and breathing was satisfactory. Occasionally there was numbness of the face or face and hand on one side. She remained paralyzed for 1 to 2 hours and in about 3 hours was almost completely recovered. Headache was slight or absent.

The category of *brainstem symptoms* included patients with diplopia, a feeling of misalignment of the eyeballs, dizziness, tinnitus, oscillopsia or nystagmus. Patients with ordinary scintillating scotoma or other visual displays were not included in this group. In the present series only 3 patients were placed in this category mainly because of the predominance of additional accompaniments which qualified them for other categories.

In the category *no visual accompaniments* candidates were scrutinized with special care before being included reflecting as already emphasized the central importance of visual symptoms to the diagnosis. In the

new series almost 45% of cases were placed in this category.

Illustrative Case Histories

Case 4 Visual

A man aged 56 had 6 spells of visual obscuration lasting 15 to 30 minutes. The first and second were 5 and 4 months before admission respectively. The last 4 occurred in the week before admission. The first 5 consisted of the appearance that printing he was looking at was underwater, distorted, slightly moving, and difficult to bring into focus. He also described it as "like a failing fluorescent light in which the luminous gas column goes back and forth horizontally creating a distortion" and "like waves coming in from the ocean." In one spell, he noted that at times the last two letters of words were missing. In the last spell, the obscuration was only far temporally in the left eye. There was no scintillation, flickering, or sparkling. There was no build-up. After each spell there was a mild bitemporal headache with slight nausea. On closing his eyes, he was unaware of any abnormality.

Case 5 Visual and Paresthesias

A woman aged 45 after carrying out aerobic exercises developed blurred vision followed first by the appearance of looking through shattered glass, then a streaming of horizontal bright lines from left to right, and finally a visual display resembling a jigsaw puzzle with pieces coming and going producing a changing pattern of vision and non-vision. The visual phenomena lasted about 20 minutes. During the next 30 minutes the right cheek became numb, "like novocain wearing off" and there was a feeling of fullness in the right ear. Slight numbness persisted for several hours. There was no headache.

Case 6 Visual and Speech Disturbance

A woman aged 57 while eating noted a bright uncolored "pinwheel" display revolving before her eyes at a distance of 10 inches and a rate of 3/sec. The left half of the face of the person opposite her was missing. The patient felt light-headed, hazy, "spaced-out," dreamy, unable to concentrate, and she began to have trouble getting her sentences out despite trying repeatedly. The words were wrong but not garbled and she was surprised that the words coming out were not those that she had intended to say. After 35 minutes all symptoms ceased and she had a dull headache across the forehead for 30 minutes. She had literally never had a headache in the past.

Case 7 Visual, Paresthesias, and Speech Disturbance

A woman aged 54 for the first time in her life suddenly developed very bright flickering jagged lights in her visual field off to one side. They lasted 5 to 10 minutes and as they faded numbness began around the right breast and axilla and in the next 8 minutes slowly spread down the arm past the elbow to the wrist, hand and fingers following which it appeared on the right side of the tongue, the right side of both lips and the

adjacent cheek. The numbness resolved in about 20 minutes whereupon she began to speak gibberish although she thought the words in her mind were correct. The speech disturbance lasted 30 minutes following which she developed a severe throbbing headache in the left forehead. Six spells occurred in 5 days. In the past she had had a mild headache about once a month.

Case 8 Visual, Paresthesias, and Speech Disturbance

A woman aged 54 while at work suddenly developed blurred vision without buildup. She could not make out printing but could see faces. There was no scintillation or flickering. For several seconds, a bar of brightness 2 to 3 mm wide extended horizontally across the upper part of vision in the right eye. After 15 minutes while vision was still blurred she developed numbness of her left cheek starting just below the eye and spreading medially to the side of the nose and laterally onto the cheek and down to the rim of the jaw and the corner of the mouth. The tongue was not involved. After several minutes she began to have difficulty expressing herself and unintended words came out. She felt confused. The visual symptoms lasted 30 minutes, the speech disturbance 20 minutes and the numbness about 4 hours. At the end of one hour she developed a moderately severe bilateral throbbing headache. In the past she had had periodic throbbing headaches but had had none for the previous five years.

Case 9 Visual, Paresthesias, Speech Disturbance and Weakness

A vigorous man aged 56 at 1315 was working under his car looking up when he became dizzy with everything moving, but not spinning. He sat up, and his head cleared. After 15 minutes he walked steadily. He slept for 1½ hours. Two hours from the onset he experienced 2 distinct 1 second twinges of numbness of the lips. One minute later there was tingling of the left cheek and corner of the mouth. He kept trying to talk but could not. The left fingers 1, 2, and 3 were totally numb and there was no power in the left hand. Keys dropped from his hand. This all occurred in 1 minute. Speech improved in 1 to 2 minutes, the fingers began to improve in 5 to 10 minutes and in 4 hours recovery was complete, numbness of the cheek clearing last. There was a slight pressure ache at the left temple and shaking his head evoked a jolt headache. He came to the Emergency Ward and while lying dozing at 2100 the *right* side of the face became numb, starting at the corner of the mouth and spreading outwards to the cheek. Speech was not perfect. The entire right 5th finger became totally numb and prickling. He then developed a steady pressure at the right temple. The numbness of the finger was still present 1 hour later when he fell asleep. He was examined by a neurologist during the second spell and there was no weakness of the face or limbs. Next morning he was asymptomatic. The patient gave the history that 2 years before while driving along he became dizzy and experienced a visual display of bright jagged colored lights like a sun-

burst, yellow, blue, etc. He had 2 further such spells all similar, starting small and building to a crescendo and lasting 10 minutes. There was no associated headache, numbness or speech disturbance. Three vessel cerebral angiography was normal. The patient had had business worries for 7 months but the day of the spell was the first day he had felt relaxed and happy.

Case 10 Visual, Paresthesias, Speech Disturbance and Weakness

A man aged 71 had 3 similar spells in 30 hrs. In the first at 0730 one morning he became aware of numbness of the thumb, index, and middle fingers on the right side extending on to the lateral part of the hand, palm and dorsum and the distal $\frac{2}{3}$ of the medial forearm. At the same time the right cheek was numb, speech was slurred and the right side of the face sagged. There was a peculiar feeling on the right side of the throat associated with difficulty speaking. He carefully selected his words. The numbness cleared in 10 minutes and slurred speech in 30 minutes. In the Emergency Ward 1 hour later there was a right facial weakness. Heparin was started intravenously. Next morning at 7:30 a similar spell occurred with numbness and tingling of the index and middle fingers and the same odd feeling in the throat associated with slurred speech. The duration was about 10 minutes. Six hours later there was a similar episode in which he said the right side of the face was wooden. He received a bolus of heparin and had no further spells. The patient reported that during the period of symptoms and for a few days afterwards he had noticed a small blind spot to the right of the center of his vision involving 4 or 5 letters of a word occurring intermittently. At times instead of being an empty spot the letters in the spot were thicker than normal as if italicized. There was no shimmering. A left carotid angiogram 48 hours from the onset was normal as were an EEG and CT scan. There were no further symptoms in the following 2 years.

Case 11 Visual, Paresthesias, Speech Disturbance and Weakness

A hypertensive man aged 55 in the week before admission had 4, 20-minute spells of numbness and weakness of the right hand, dysarthria and aphasia. In the first episode, there was a visual disturbance, either blindness in the left eye or a hemianopia. On the day after admission he became increasingly dysphasic while being examined finally making no sense at all whereupon he became agitated and "went berserk." The right fingers were both numb and weak. Carotid angiography during a spell was normal. There was no headache.

Case 12 Visual, Paresthesias, Speech Disturbance and Weakness

A man aged 59 had 13 episodes in 8 months. Eight months before admission while driving his car he experienced a severe jab of pain in the left occipital region, felt dizzy and in a flash became totally blind.

He slumped over the steering wheel and was apparently unconscious. On regaining consciousness, the left eye was still blind and speech was incoherent. In two hours he had returned to normal. All tests including four-vessel cerebral angiography and a CT scan were normal. Four months later in one day he had 2 further spells of blindness, paralysis of the right arm and leg, slurred speech, and difficulty in getting his words out. Each episode lasted 20 minutes and they were separated by 20 minutes. Two months before admission he had a fourth spell lasting about 30 minutes and in the month before admission he experienced 9 spells lasting 1 to 2 hours. In the last two he did not lose his vision but there was numbness around the mouth in addition to a right hemiplegia. He was started on long-term Coumadin therapy and was free of spells when examined 2½ months later.

Case 13 Visual, Paresthesias, Speech Disturbance and Weakness

A man aged 41 while doing carpentry noted a "spongy" feeling around the right knee. Within minutes the right arm was weak and the right side of the face felt heavy. He was unable to get his words out. On the way to the hospital the right arm and leg became immobile. The whole right side felt "dead" including the mouth. The paralysis cleared briefly but returned a second time and lasted 15 minutes.

For one week the patient daily had had a throbbing headache, something unusual for him. In the previous 6 months he had had periods of blurred vision lasting several minutes. In the past year on at least 6 occasions the right leg had felt spongy and given way.

On the second day in hospital the right side became numb and speech showed paraphasic errors. The limbs were not weak. The right plantar response was extensor. In 20 minutes he had recovered whereupon he developed a right facial weakness and slow, slurred speech. In 15 minutes he had again recovered. Bilateral carotid angiography was normal.

Case 14 Visual, Paresthesias, Speech Disturbance and Weakness

A man aged 60 had classical ophthalmic migraine for 31 years, occurring once or twice a year. The scintillations characteristically showed gradual build-up, expansion, and migration to the temporal field. 13 months before admission, the patient had the first of some 30 to 40 similar spells. These spells were heralded by a cataclysmic feeling in the head that something terrible was going to happen. He was light-headed, his body felt drained of strength, and both legs felt heavy. They did not buckle but he had to sit down. He had a floating, undulating feeling. The spells lasted 3 to 4 minutes and he remained fully aware. The feeling was so alarming that anxiety was prominent. He felt weak for up to one hour afterwards. In some spells, only the left leg was affected in which case, it felt numb up to the knee. The leg was definitely weak and he had to sit down. He estimated that he had some 7 major spells in all, and some 25 minor spells. In the first spell he was

seated and turned his head to speak to the person beside him. He had the impression that turning his neck played a prominent part in the spell. Scintillations never occurred at the time of such a spell and there was no associated headache. Three days before admission, the patient had a typical spell lasting about 30 seconds after which he resumed his activities but 5 minutes later the episode recurred with the feeling that he was going to lose consciousness, the left leg was heavy, and he sat down. The second spell lasted 4 to 5 minutes and he had the impression that he had difficulty speaking and had to search for words. Eight months before admission the patient had awakened from sleep to find that the left corner of the mouth and adjacent lips were numb along with the middle one third of the left side of the tongue extending over the lateral edge onto the base of the tongue. This numbness was persistent and faded in the next six months. It waxed and waned and seemed to be evoked by tenseness. On two occasions the patient awakened afterwards with the entire tongue numb. Beginning at the time of the onset of numbness of the tongue, his typical scintillating scotomas increased briefly in frequency to 2 or 3 times a week and were not accompanied by headache; sneezing and coughing, however, produced a jolt headache in an area $1\frac{1}{4}$ inches in diameter about 1 inch above the lateral part of the eyebrow on the right side. About one year before, the patient had had numbness of the entire left arm from fingertips to shoulder. He recalled that it started with numbness of the fingers which spread upwards to the shoulder taking 5 to 8 minutes. It remained at a peak for 8 minutes and then gradually receded clearing from the arm and forearm first in a pattern just the reverse of the onset. The entire episode lasted $\frac{1}{2}$ hour. On other occasions, the patient noted marked numbness of one or other individual finger on either hand. He recalled the middle finger being especially affected on each hand, although not at the same time. There was a family history of migraine. CT scan, EEG, and intravenous digital subtraction angiogram were essentially normal.

Case 15 Non-visual

A man aged 58 suddenly experienced darkening of vision for 1 second. At the same time the right leg became numb and weak followed by numbness of the right arm, then the right cheek and right half of the tongue. Speech was slurred, swallowing was impaired and the patient noted diplopia. Recovery occurred in 10 minutes. Later in the day he had dizziness, vertical diplopia, and transient tinnitus in the left ear for a few minutes. Spells of dysarthria and numbness continued to occur in the next 2 weeks. While under observation he had 5 attacks of numbness, sometimes involving the right side, sometimes the left side. They increased to 2 or 3 each day and finally to 5 or 6 attacks daily. Heparin was administered intravenously. Four vessel cerebral angiography was normal. In the spells the numbness always marched from one part to another. It could start in leg or hand or face and spread to the other parts in 3 minutes. When the face was involved first, the

numbness started in a small area and gradually spread to the cheek and tongue. At the height of the spells the limbs were weak but could be moved. There had never been headache or scintillation.

Case 16 Non-visual

A man aged 65 developed weakness of the right hand and arm at 0700 while shaving. It lasted about 3 minutes. At lunch weakness returned for about 5 minutes. Next day at 1115 while he was writing he developed tingling in the right forearm and arm which spread to the right side of the trunk and the right thigh and lasted 15 minutes. During the next night he awakened with marked weakness of the right arm. He fell asleep and on awakening one hour later, strength was normal. That evening at 1915 prickling began in the right forearm and spread in the next 10 minutes to the shoulder, ear, angle of the jaw, and down to the inner aspect of the right thigh and lasted 12 minutes. 24 hours later while receiving heparin intravenously his right forearm became numb again followed in the next 20 minutes by hand, fingers, shoulder, cheek, side of tongue, and right inner thigh. There was a slight headache afterwards. A left carotid angiogram 10 hours after the spell was entirely normal. There was no recurrence in the following 5 years.

Case 17 Non-visual

A woman aged 72 experienced approximately 50 episodes of numbness in 5 months, occurring once or twice a week, sometimes every day. There was a remarkable march of numbness over a period of 15 minutes. First she felt the lower lip droop following which she noted numbness of the right side of the tongue spreading to the lips, cheek, fleshy part of the ear and neck taking several minutes. There followed numbness of the right thumb followed in the next 5 minutes by numbness spreading to the index, middle, ring and little fingers, ascending to the hand, forearm, arm, shoulder, chest, abdomen and on one occasion the buttock. Numbness lasted about 30 minutes and cleared in the reverse order. There was no weakness, speech disturbance, scintillations or headache. Cerebral angiography was normal. The left internal carotid artery in the neck showed 40% stenosis for which endarterectomy was performed without effect. Heparin also was ineffective.

Case 18 Non-visual

A woman aged 47 had scattered attacks of ophthalmic migraine over a period of many years associated with only a suspicion of a slight temporal headache. One day she had a 45-minute episode of numbness and tingling on the left side of the chin just below the lip in an area about $\frac{3}{4}$ of an inch wide and of the distal $\frac{1}{2}$ inch of the tongue on the left side. There may also have been numbness of the ball of the cheek.

Case 19 Non-visual

A man aged 65 late at night suddenly began to stutter, used wrong words, and finally could not talk for a

few minutes. A left carotid angiogram was normal. The patient had migraine all his life and 2 days before his episode of dysphasia he had had a spell of scintillating scotoma.

Case 20 Non-visual

A man had two spells of paralysis of the left hand at the ages of 53 and 64 respectively. In the first while raking the lawn the arm suddenly hung at his side totally paralyzed and lacking in feeling. It felt as if it were not part of him. That spell lasted about 12 hours. In the second one, on answering the telephone it fell from his hand and the left hand had no grip. Severe weakness lasted about 30 minutes and recovery was complete in 3 hours. All tests short of angiography were normal. For about one year he had noticed that the fingers of the left hand fell asleep intermittently for 1½ to 2 minutes at a time. There was no recurrence of the paralysis in the following six years.

Case 21 Non-visual

A man had 3 identical spells at the ages of 30, 45, and 65 years respectively. In each he suddenly awakened from a deep sleep, jumped up and developed weakness of the right side of the mouth and right hand and inability to speak properly for about 10 minutes. All tests short of angiography were normal.

Case 22 Non-visual

A man aged 64 suddenly experienced a bad taste on the inner side of the left cheek "like an abscessed tooth." Within one minute the tongue became increasingly numb until the left side felt swollen to "12 times its normal size." Slurring made speech almost unintelligible. Food had no taste. After 30 minutes, numbness had spread to the right side of the tongue and continued to spread in all, for about 45 minutes. Four and a half hours from the onset the numbness had decreased to about 80%. In 12 hours he was 90% recovered but taste was still impaired. Full recovery took another 24 hours. The patient reported that 3 to 6 times in the previous year he had had episodes of blurred vision with difficulty focusing.

Two Special Cases

Acute Cerebral Vasospasm versus Benign Arteritis. In the type of case to be described, the patient, usually a woman, develops a severe headache in association with persistent hemispheric signs — hemiparesis, aphasia, hemianopia, etc. Cerebral angiography discloses irregular segmental constrictions and dilatations of the cerebral arteries resembling the picture of cerebral angiitis or the cerebral vasospasm of subarachnoid hemorrhage. The CSF is usually normal. Recovery occurs in 4 to 6 weeks sometimes with a residual neurologic deficit.

Case 23

A diabetic hypertensive woman aged 51 watched as two of her favorite horses were taken away to a glue factory. Suddenly she developed a high intensity

throbbing occipital headache of such severity that she lay on the floor holding her head until she was driven to the hospital. The blood pressure was 170/100. An LP, EEG, and CT scan were normal. The headache faded in 48 hours and she was discharged on day 3. On day 5, 4 days from the time of the first headache, she had several 10 minute episodes in which she used wrong words and could not understand what was said to her. Severe generalized headache worse on the left side returned and she was readmitted on day 6 and was unable to answer questions, name objects or write. The right plantar response was extensor. A CT scan on day 7 showed low density areas in the left frontal region and the right posterior frontal region. Angiography on day 9 showed multiple segmental narrowings (at least 10), most advanced in the left frontal speech area (fig. 1). High-dose steroid therapy was begun on day 14 and the aphasia cleared in the next 10 days. Angiography two weeks later showed a decrease in the arterial abnormality. A repeat CT scan was normal.

Snyder and McClelland³ described such a case which they interpreted as isolated benign cerebral vasculitis. Serdaru et al⁴ raised the possibility of migrainous vasospasm in their case in which a biopsy of an involved segment of a superficial temporal artery showed no abnormality. The patients in these cases developed their neurologic deficits acutely on a background of good health, there was no fever, the CSF was normal and the eventual outcome was good, all features that weigh against the diagnosis of vasculitis.

The following case may be relevant in this matter. It concerns a young migraineur whose cerebral angiogram performed during a dysphasic episode showed segmental irregularities resembling those found in the cases just referred to.

Case 24

A young man aged 25 had recurrent severe headaches for about 12 days before admission related mainly to doing calisthenics such as sit ups, push-ups, and skipping rope. The headaches, which lasted about one

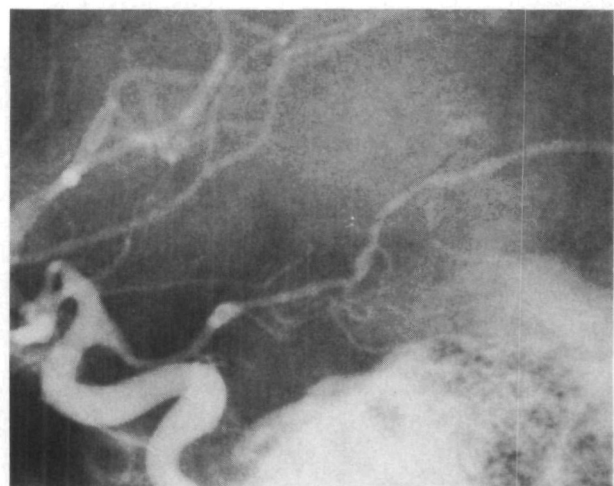

FIGURE 1. Case 23. Left carotid angiogram showing arterial constriction and dilatation in posterior cerebral artery.

hour, were moderately severe and throbbing and were situated behind the forehead bilaterally extending down behind the eyes. On the day of admission, he awoke with a pressure behind both eyes which gradually increased in severity until he was obliged to lie quietly, pale and shivering, with photophobia, blurred vision, and cold hands. He mentioned that his hands were numb and had been like this on previous days. "If I could only get the feeling back in my hands." When he began to vomit at about 10 AM he was taken to the hospital and was able to sign his name. Within a few minutes he had difficulty thinking of names and finding words, he used wrong words and this progressed until he became mute and vague and could not understand what was said to him or seemed not to listen. Neurologic examination disclosed aphasia and slight weakness of the right arm and right handgrip and diminished sensation to pin prick in the right hand and arm. An LP yielded clear spinal fluid at a pressure of 140 mm and containing 2 WBCs. On leaving his room to go for a CT scan (which was normal) at 12:30 PM about 2½ hours from the onset, he simply made a victory sign. A left carotid angiogram at 15:00 (by Dr. Julius E. Cimbroniewicz at Augusta General Hospital, Augusta, Maine) showed segmental constrictions and dilatations of the arteries in the left parieto-occipital region (fig. 2). A sedimentation rate was 10 mm in one hour. An echocardiogram was normal. The patient's speech returned to normal in 18 hours while headache continued for a few more days. There was a personal history of ordinary headaches about once a month relieved by taking 2 aspirin and lying down. There was no family history of migraine or accompaniments.

There were no further neurological episodes in the next six years and the patient has remained well. The events in this illness (headache, bilateral numbness and transient aphasia) are consistent with the diagnosis of migraine. Segmental arterial constrictions and dilatations are probably not an adequate basis for comparing this case with the previous one but there is a link in

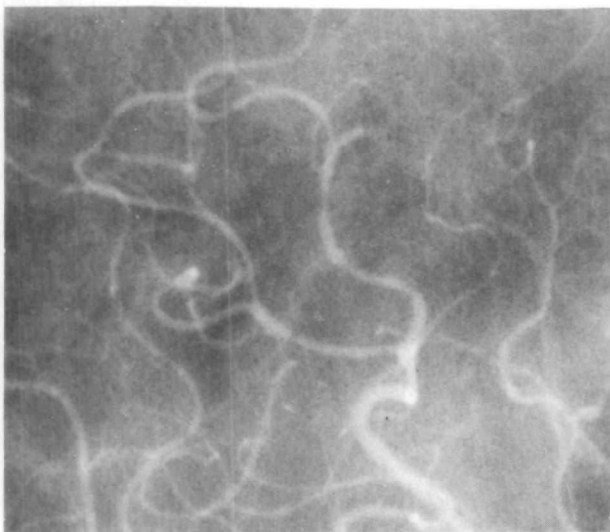


FIGURE 2. Case 24. Left carotid angiogram showing arterial irregularities in the parieto-occipital region.

this case between migraine and isolated benign cerebral vasculitis and support is provided for the view of Serdaru et al⁴ that the process is migrainous. On the other hand, there are closely similar cases in young women with headache and prolonged hemispheric deficits in whom angiograms during the period of neurologic deficit are normal or at least show no segmental arterial abnormality raising the unlikely possibility that the arterial changes are epiphenomena rather than a primary process causing cerebral ischemia.

If these cases are accepted as migrainous, they demonstrate the occurrence in migraine of alterations in the caliber of the cerebral arteries, perhaps allied to vasospasm, a change that has been postulated for more than 100 years as the cause of migraine accompaniments but which has been rarely documented. In this regard the cases are of considerable importance, particularly case 24 in which angiography was performed approximately 5 hours after the onset of aphasia. In the angiograms the narrowing and the widening of the cerebral arteries both were pathological or abnormal, a combination consonant with modern theories of biphasic vascular changes in migraine and illustrating the presence of vasoconstriction and vasodilatation in neighboring segments of the same artery, offering evidence that the two states are closely coupled. It would be a welcome step forward if it could be demonstrated that vasoconstriction is consistently responsible for any aspect of migraine.

Some Additional Observations

Review of this series of cases has brought to the fore more clearly some clinical features which although already known, had not been fully appreciated.

1. Diplopia

The frequency with which diplopia occurred was surprising, 10 patients reporting it quite definitely while in several others it was a questionable symptom. It was always episodic, lasted a few seconds to a few minutes and could be either horizontal or vertical. The patient sometimes noted a feeling that the eyes were drawn out of alignment or that one eye deviated medially. This experience underlines the prominence of diplopia as a symptom of migraine. Because of the brief duration of the diplopia, it has been difficult to characterize. Localization of the deficit is uncertain but a site within the brain stem either supranuclear or infranuclear would seem most likely. Third nerve diplopia may arise as a result of ischemia in the territory of the posterior cerebral artery, the central focus of migraine accompaniments.

2. Numbness of the Tongue

Of 50 patients with numbness of various parts of the body, the tongue was involved in no fewer than 20. This frequency seems to be much greater than in hemispheric and thalamic transient ischemic numb attacks but this is a point on which further data are required. When transient numbness is the only symptom and involves the tongue, migraine is a prime consideration.

Transient isolated numbness of the chin on one side may have the same connotation. In case 14, the patient awakened from sleep with numbness of the left corner of the mouth, the adjacent lips and the left side of the tongue. In that case it took 6 months to fade away.

3. The Remarkably Focal Distribution of Numbness

It is striking to find that numbness may be limited to one finger or one toe, the distal half of a digit, the chin on one side, the tip of the tongue or a small patch on the cheek. Such events suggest that a migrainous process might be considered in the case of other transient symptoms of a puzzling nature.

4. The Evanescence of Numbness

How brief can migrainous numbness be? Several patients were quite certain that numbness of a finger or a hand or a lip lasted 1 to 10 seconds. This brevity of an accompaniment is consistent with reports of patients that visual accompaniments and tinnitus last less than 30 seconds.

5. Tinnitus, a Sound in the Ear or Head

In one patient's spell, a roaring or rushing sound in the right ear was followed immediately by moving triangular patterns in the left visual field; in case 15, tinnitus occurred for a few moments in some episodes; in one case buzzing occurred in both ears and in another there was a feeling of fullness in one ear. Some patients with strokes in the territory of the posterior cerebral artery have noted tinnitus at the onset, a localization that would explain the combination of visual symptoms and tinnitus in migraine.

6. Sudden Severe Pain in the Head or Neck Immediately Preceding the Onset of Blindness, Blurred Vision, or Numbness

This unusual complaint was described dramatically as "struck with a sledgehammer," "top of the skull driven backward," and "sudden piercing pain in the back of the head." The occurrence of sudden excruciating alarming pain at the onset of a migraine accompaniment has been prominent in the syndrome termed "catastrophic migraine" in which permanent sequelae are frequent.⁵ The complaint is also part of so-called "crash migraine."⁶

7. A Feeling of Faintness or Presyncope

Five patients of the group complained of faintness or presyncope at the onset of the spell but hypotension was probably not the correct explanation since lying down brought no relief. It is possible that alarm and anxiety cause the feeling, but it is more likely that they are secondary to a strange, unpleasant, disconcerting head sensation. In our experience, the complaint is closely linked to involvement of the non-dominant hemisphere (left-sided symptoms) and probably represents a complex somesthetic disturbance of sensory areas representing the head.

8. "Triggers"

The conditions or events which precipitate accompaniments are always of interest to those studying migrainous phenomena. Two patients developed accompaniments on being awakened abruptly in the morning by the telephone ringing. Another had three episodes on suddenly awakening and jumping to his feet. Emotional factors were reported several times — a patient's favorite horse was being taken away to a glue factory, worry over a seemingly unsolvable professional situation, overwork at income tax time, and an outburst of anger. However, in most cases no such trigger circumstance existed and the emotional circumstances may be fortuitous. Depression was not evident. One patient felt particularly well after having been through a period of worry. Another patient had his spells 36 hours after renouncing his chronic alcoholic habit. In this regard, some patients have used a small alcoholic drink to abbreviate their scintillations.

Of the known extraneous factors that act as triggers in migraine, the most frequent by far is angiographic contrast material. In the present series, angiography precipitated scintillations in two patients and marching numbness in two others. Overall, visual symptoms are reported much more frequently underlining the special importance of the visual system in migraine. The effect of contrast material on the calcarine region must contain a clue to the triggering mechanism and suggests that a circulating agent acts locally rather than by way of a central mechanism. In this group there were no instances of the acute amaurosis-amnesia syndrome (7) that occasionally follows angiography. It is of interest that in that syndrome, which probably results from medial temporal and calcarine involvement, scintillations do not occur suggesting that scintillations may be generated from the intact hemisphere.

Discussion

The findings in this review of our experience of the past five years with cases of late-life migrainous accompaniments bear out the findings and support the conclusions reached in the previous paper. The diagnosis is now being made with greater confidence. However, an important aspect that requires emphasis in this discussion is the uncertainty that surrounds the diagnosis in all cases except the most classical. Diagnosis by exclusion is still the most judicious approach. What is needed, of course, is a specific diagnostic test for migraine, but such seems nowhere in sight at the present time.

It is scarcely credible that so few variables can be combined into such a heterogeneity of clinical pictures. The cases do not lend themselves to generalizations and the accumulation of cases seems not to build an experience that readily allows recognition of a syndrome.

The practical value of recognizing these cases is that investigative procedures and therapeutic measures can be tailored accordingly, ensuring a rational plan of action.

References

1. Fisher CM: Late-life migraine accompaniments as a cause of unexplained transient ischemic attacks. *The Canadian Journal of Neurological Sciences* **7**: 9-17, 1980
2. Fisher CM: Pure sensory stroke and allied conditions. *Stroke* **13**: 434-447, 1982
3. Snyder BD, McClelland RR: Isolated benign cerebral vasculitis. *Arch Neurol* **35**: 612-614, 1978
4. Serdaru M, Chiras J, Cujas M, Lhermitte F: Isolated benign cerebral vasculitis or migrainous vasospasm? *J Neurol Neurosurg & Psychiat* **47**: 73-76, 1984
5. Fisher CM: Presented in the JL Silversides Lecture, Academy of Medicine, Toronto, Canada, June 13, 1985
6. Fisher CM: Painful states: A neurological commentary. *Clinical Neurosurgery* **31**: 32-53, p 50, 1984
7. Studdard WE, Davis DO, Young SW: Cortical blindness after cerebral angiography. Case Report. *J Neurosurg* **54**: 240-244, 1981

Late-life migraine accompaniments--further experience.
C M Fisher

Stroke. 1986;17:1033-1042

doi: 10.1161/01.STR.17.5.1033

Stroke is published by the American Heart Association, 7272 Greenville Avenue, Dallas, TX 75231

Copyright © 1986 American Heart Association, Inc. All rights reserved.

Print ISSN: 0039-2499. Online ISSN: 1524-4628

The online version of this article, along with updated information and services, is located on the
World Wide Web at:

<http://stroke.ahajournals.org/content/17/5/1033>

Permissions: Requests for permissions to reproduce figures, tables, or portions of articles originally published in *Stroke* can be obtained via RightsLink, a service of the Copyright Clearance Center, not the Editorial Office. Once the online version of the published article for which permission is being requested is located, click Request Permissions in the middle column of the Web page under Services. Further information about this process is available in the [Permissions and Rights Question and Answer](#) document.

Reprints: Information about reprints can be found online at:
<http://www.lww.com/reprints>

Subscriptions: Information about subscribing to *Stroke* is online at:
<http://stroke.ahajournals.org/subscriptions/>