

Cerebral infarction in term neonates: diagnosis by cerebral ultrasound

H. Bode*, H. M. Straßburg, W. Pringsheim, and W. Künzer

Universitäts-Kinderklinik, Mathildenstrasse 1, D-7800 Freiburg i. Br., Federal Republic of Germany

Abstract. Cranial ultrasound (US) through the newborn's open fontanelle can diagnose not only intracerebral hemorrhages but also diffuse and localized hypoxic-ischemic encephalopathies. Sonographically, it was possible to distinguish between different courses of cerebral ischemia in seven neonates: (1) ischemic infarction, usually in the area of the middle cerebral artery; (2) borderline infarction; (3) transient ischemia. The patients showed lateralized seizures during the first days of life with a corresponding focus in the electroencephalogram (EEG). Computed tomography showed areas of partially reduced density corresponding to the regions of increased echogenicity in ultrasound. The course was various; prognosis was good except in one patient. Etiologically, embolism, thromboses or hypoxemia were responsible for cerebral infarction. In some cases secondary bleeding ensued. The prognostic value of cerebral lesions was dependent on the involved area, gestational age, and any concurrent hypoxic cerebral damage.

Key words: Neonates – Infarction – Hypoxic-ischemic encephalopathy – Ultrasound.

In the last few years intracranial bleeding of the newborn, especially of the premature, has been of increasing interest. This is particularly due to the new techniques of cranial CT and cerebral ultrasonography (US). Only lately has the possibility of diagnosing hypoxic-ischemic changes of the newborn's brain been reported [6, 9, 14, 15, 20].

Generalized and localized lesions should be distinguished. In the term newborn, the latter present as ischemic infarction, usually in the area of the middle cerebral artery, often with a typical clinical course, and parasagittal borderline infarction [6, 10]. Periventricular leucomalacia is the typical feature of the premature [5, 7]. Clinical course and prognosis in the two groups seem to be different. This paper does not deal with the latter.

Materials and methods

We used two mechanical real-time sector scanners (ATL Mark 5 and ATL Mark 100) with a 5 MHz transducer for the examination of the newborn via the open fontanelle. Sedation was not needed. Pictures were taken in different coronal and in the sagittal, and different parasagittal planes. CT was done by a General Electric 8800 without contrast medium. EEGs were recorded with an 8-channel EEG machine (Siemens mingograf 10). Electrode placement was according to the international 10–20 system.

Case reports

Patient 1

This boy was born on 23 August 1984 by normal vaginal delivery in week 39 and weighed at birth 3,450 g. Apgar scores were 9-10-10 after 1-5-10 min. At 30 h after birth he had a tonic seizure and showed opisthotonus. Serum electrolytes, blood sugar, pH status, screening for amino acids and organic aciduria and serology for perinatal infections were normal. Cranial US on day 2 demonstrated increased echogenicity of the right precentral subcortical area with finger-shaped reflexions laterally (Fig. 1). There were no differences in vascular pulsations between the sides. The EEG on day 11 demonstrated a right precentrotemporal epileptic focus. The CT on day 14 revealed a right frontal hypodense area, no necrosis, and no bleeding (Fig. 1). Under treatment with phenobarbitone no seizures occurred after day 4. At 5 weeks, the right ventricle was larger than the left one; at 3 months small cystic areas of necrosis were seen in US (like patient 2, Fig. 2). At 8 months the child showed slightly asymmetric movements (better on the left side) with an otherwise normal development.

Patient 2

This boy was born on 9 January 1984 by emergency caesarian section in week 32 and weighed 1,940 g. The mother had toxemia of pregnancy. Apgar scores were 4-10-10 after 1-5-10 min. At the age of 5 weeks the boy developed severe hypernatremic toxicosis with epileptic seizures. CT showed diffuse frontal areas of low density with additional diminished density in the right precentral area. The EEG revealed epileptic activity in the same area. Cranial US demonstrated a wedge-shaped area of increased echoes with the apex at the foramen of Monro and the base near the left cortex. A small cystic area of necrosis developed within 2 months, which gained connection to the slightly enlarged ventricles after another 2 months (Fig. 2). No more seizures were seen under treatment with phenobarbitone. At 6 months the child showed slight coordination problems.

* To whom offprint requests should be addressed

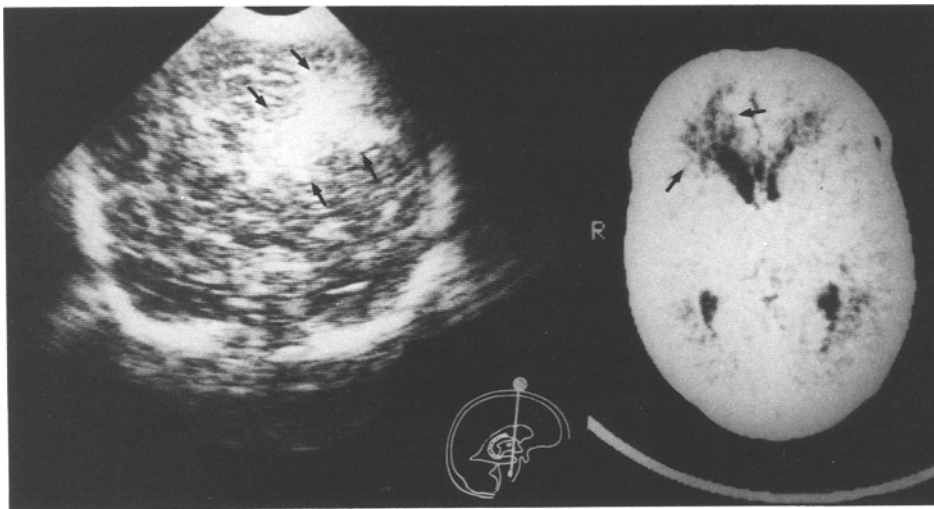


Fig. 1. *Patient 1.* Ultrasound on day 2 (*left*): increased echogenicity of the right precentral area. Computerized tomogram on day 14 (*right*): right frontal hypodense area

Patient 3

This boy was born on 23 April 1984 and weighed 2,460 g. He was delivered by caesarean section in week 38 because of severe variable cardiac decelerations due to premature separation of the placenta. Apgar scores were 4-6-9 after 1-5-10 min. On day 2 right-sided seizures occurred. The EEG showed an epileptic focus in the left temporoparietal area. Cranial US demonstrated a left-sided horseshoe-shaped area of decreased echoes. The echoes increased at its border during the next 2 days; a porencephalic defect developed within 3 weeks. CT on day 4 had revealed a fresh hematoma in the same area (Fig. 3.) The EEG showed a corresponding epileptic focus. No more seizures occurred under phenobarbitone. At 4 months the child showed moderate right-sided muscular hypertonia. The porencephalic defect persisted. The histology of the placenta revealed an intervillous thrombus and older infarction (Institute of Pathology, University of Freiburg, no. 8590/1984).

Patient 4

This girl was born on 20 May 1980 at term to a mother with toxemia of pregnancy, the baby weighed 3,440 g. Uncomplicated delivery and Apgar scores of 9-10-10 after 1-5-10 min were noted. Serum electrolytes, blood sugar, pH status, screening for amino acids and organic aciduria and serology for perinatal infections were normal. Within 24 h she developed right-sided tonic-clonic seizures with a corresponding epileptic focus in the left precentral area in the EEG. By US an increased echogenicity in the left central subcortical area was detected. CT was negative. Fourteen days later CT showed a hypodense area in the left temporopolar region. Clinical findings and US were normal after another 2 weeks. At 1 year the child was still normal.

Patient 5

This girl was born on 26 May 1981 at term after a normal pregnancy and delivery; she weighed 3,120 g. Apgar scores were 9-10-10 after 1-5-10 min. On day 5 right-sided seizures appeared. Serum electrolytes, blood sugar, pH status, screening for amino acids and organic aciduria and serology for perinatal infections were normal. US on day 7 revealed increased echoes lateral to both ventricles predominantly left-sided and reaching the cortex. The EEG under phenobarbitone on day 9 showed no pathologic

features. CT on day 10 demonstrated diffuse areas of low density in the subcortical area of both hemispheres. The child appeared clinically normal at 3.3 years apart from speech retardation.

Patient 6

This boy weighed 2,600 g and was born at term on 6 May 1980 after a normal pregnancy. During labor, variable cardiac decelerations due to the umbilical cord encircling the neck were recorded. Apgar scores were 8-10-10 after 1-5-10 min. On day 3 right-sided tonic-clonic seizures appeared. Serum electrolytes, blood sugar, pH status, screening for amino acids and organic aciduria and serology for perinatal infections were normal. The EEG on day 6 showed an epileptic focus in the left temporoparietal area. CT examination on days 6 and 15 revealed diffuse, mainly frontocerebral edema. US on day 13 revealed increased echoes in the left lateral fissure of Sylvius, which were no longer visible 10 days later. The child was clinically normal at 3 and 6 months as was his EEG.

Patient 7

This baby was born on 31 December 1982, weighed 1,740 g, and was small for the date of birth. Caesarean section was undertaken because of placental insufficiency in week 37. Apgar scores were 2-7-10 after 1-5-10 min. Mechanical ventilation was necessary for 3 days because of the severe respiratory distress syndrome. On day 3 generalized seizures were seen. US indicated generalized cerebral edema; 3 days later there were zones of high echodensity frontobasally, precentrotemporally, and in the areas of the lateral fissures (Fig. 4). Three weeks later porencephalic defects were seen in these areas, which could no longer be detected 8 months later. This child developed cerebral palsy and epilepsy.

Discussion

In addition to intracranial hemorrhage, hypoxic-ischemic injury may cause brain damage in the perinatal period [1, 8]. Generalized and localized changes can be distinguished. In term neonate transitory ischemia and complete cerebral infarction, usually in the region supplied by the middle cerebral arteries [6, 10], and borderline

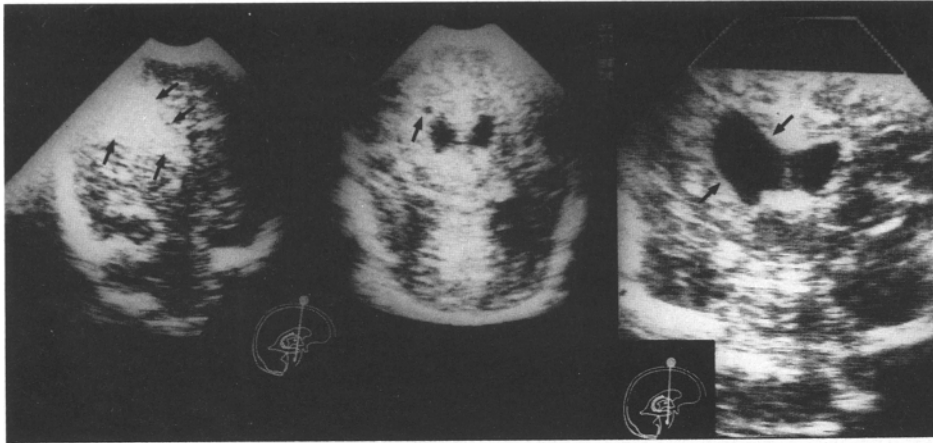


Fig. 2. Patient 2. Ultrasound at the age of 5 weeks: left wedge-shaped area of increased echos with the apex at the foramen of Monro and the base near the left cortex. Three months: small cystic area of necrosis; 5 months: asymmetry of the slightly enlarged ventricles (*left to right*)

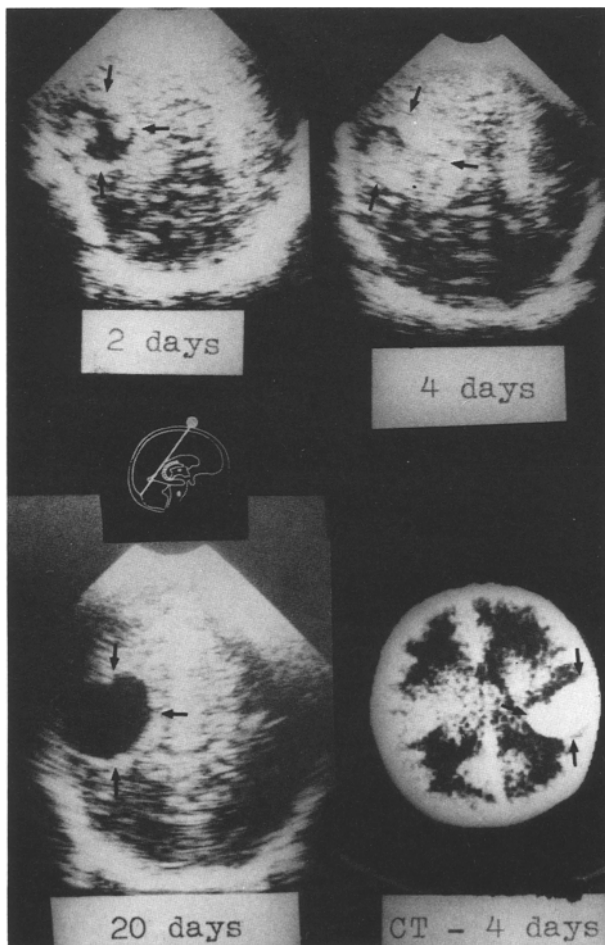


Fig. 3. Patient 3. Ultrasound: left sided horseshoe-shaped area of decreased echos (day 2) with increasing echos at its border (day 4). Development of a porencephalic defect (day 20). Computed tomography (day 4): fresh hematoma in the same area

infarction [20] can be differentiated. The typical pattern in the premature infant is periventricular leucomalacia [5, 7]. The latter condition will not be considered further in this paper.

Pathologically, infarction is defined as a local necrosis of part of an organ due to a localized disturbance of

Table 1. Causes of cerebral infarction in neonates

Hypoxemia	
	perinatal hypoxia
	severe anemia
	failure of oxygenation (e.g., respiratory distress syndrome, persistent fetal circulation)
Ischemia	
	postintraventricular hemorrhage
	thrombosis
	traumatic vascular damage
	polycythemia ^a
	stasis/shock
	meningitis/encephalitis ^a
	tumors and malformations
	consumption coagulopathy
	hypernatremic toxicosis
embolization	
	placental tissue/vessel thrombus
	twin-to-twin transfusion syndrome
	patent ductus arteriosus and foramen ovale
	congenital heart disease
Arterial hypotonia	

^a Venous circulation more commonly affected

perfusion [4]. Barmada [2] described an incidence of cerebral infarcts following arterial occlusion of 17% in term infants. Anomalies of circulation in perinatal conditions may explain the high incidence in autopsy material [19]. Hemorrhagic infarcts were predominant with a peak manifestation at 2–3 weeks after birth [11]. Histologically, white spots with accumulation of macrophages containing lipid in areas of gliosis were seen. Central liquefaction and cyst formation and proliferation or congestion of small vessels resulted soon in larger zones of hemorrhagic infarction [3]. The localization of infarcts in the term neonate follows from the special vascular architecture of its brain, which is quite different from that of the premature infant [18].

Causes of hypoxia in newborn brains are (alone or in combination) ischemia, hypoxemia and arterial hypotonia. Table 1 shows the possible causes of cerebral infarction in

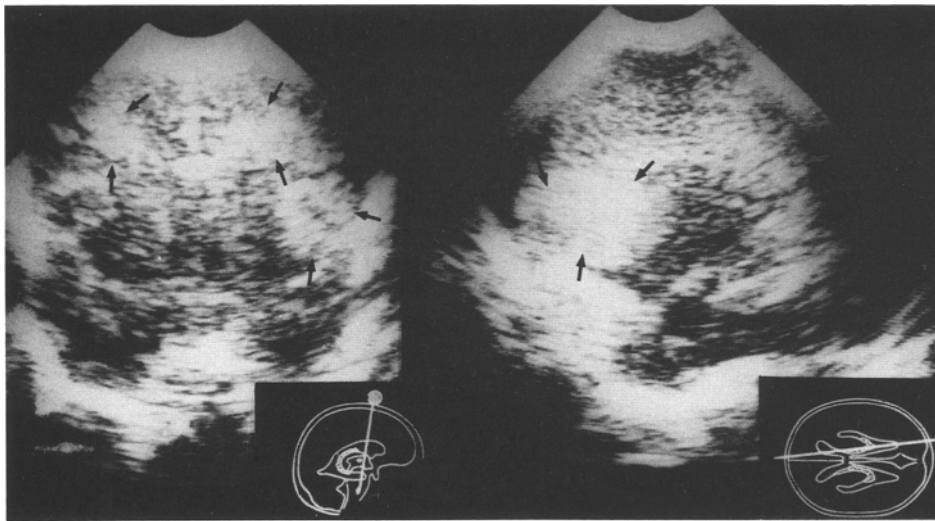


Fig. 4. Patient 7. Ultrasound: zones of high echodensity frontobasally, pre-centrotemporally and in the areas of the lateral fissures

Table 2. Diagnosis, cause, outcome of cerebral infarction in our patients

Patient	Diagnosis	Cause	Outcome
1	Ischemic infarct of right m.c.a. ^a	Not known	Slight asymmetry
2	Ischemic infarct of left m.c.a. ^a	Hypernatremic toxicosis	Slight central coordination problems
3	Prenatal infarct of left m.c.a. ^a with secondary intraparenchymal hemorrhage	Placental embolus	Muscular hypertonus
4	Ischemic infarct of left m.c.a. ^a	Not known	Normal
5	Transient ischemia of left and right m.c.a. ^a	Not known	Normal
6	Transient ischemia of left m.c.a. ^a	Hypoxia	Normal
7	Borderline infarcts with secondary intraparenchymal hemorrhage	Perinatal hypoxia	Spastic cerebral palsy, epilepsy

^a m.c.a., middle cerebral artery

neonates. They can, however, also be observed after a totally uneventful perinatal period (patient 1). Infarcts of intrauterine origin can be seen at birth. Embolization of a placental thrombus through the ductus arteriosus or foramen ovale may be a major pathogenic mechanism (patient 3). For causes of cerebral infarction in our patients see Table 2. Lesions may be unilateral (patients 1–4, 6), bilateral (patient 5), or at multiple sites (patient 7).

One should consider local cerebral ischemia if a newborn shows symptoms like early apnea and especially focal, nonmetabolic fits within the first days of life (patient 1–7). Hemiparesis was not seen in this age group.

Until lately, localized cerebral ischemia has rarely been demonstrated in the newborn period. Cranial US and CT especially have improved diagnostic facilities. The particular value of the latter shall not be discussed in detail further. As a result of local ischemia, wedge-shaped regions of increased echoes are found in the US of the full-term neonate [9]. Their causes are not yet fully understood [6]. Changed impedance due to extracel-

lular edema, incorporation of water or lipids into the cytoplasm and the enlarged intracellular bodies, the development of necrosis, capillary congestion and extravasation of blood corpuscles have been thought responsible [15]. Sometimes the increased echos may even represent sonographic artifacts.

The differentiation between infarction and vascular congestion or hemorrhagic and nonhemorrhagic infarction by US alone is not always possible. Intracerebral bleeding may be distinguished from hemorrhagic infarction by an even greater increase of echogenicity, stronger expansive tendency or localization. Porencephaly is more common and more coarse following hemorrhagic tissue lesions (patient 3). Pure ischemia results more often in small cystic lesions (patients 1 and 2). Small defects can disappear with time (patient 7). Glial proliferation and calcification are seen only after lesions of older children.

Postmortem correlation studies with the results of US are still rare [5, 11, 13, 16]. We could not carry any out either, because none of our patients died. Yet it is known

that confirmed (postmortem) cerebral edema can be diagnosed in US by the diffusely increased echogenicity of the brain parenchyma with ventricular compression and loss of the interhemispheric fissure. One should expect analogous changes in localized ischemia.

So far, the final diagnosis can only be made by repeated observations and the additional use of other techniques such as EEG and CT, with and without contrast medium. Further information may come from cerebral scintigraphy, which should remain negative in the 1st week after infarction [12] as well as digital intravenous angiography [19] and positron-emission tomography [18], Doppler sonography [15], and magnetic resonance tomography. The different techniques may lead to different results and variously localized alterations at synchronous investigations and in the course of observation. Early examinations are important for comparison; pathological results beyond the 1st week are of greater prognostic relevance than earlier ones. For example, the CT often remains negative in the 1st week after cerebral infarction or only shows generalized cerebral edema. A localized reduction of density in the CT scan corresponding to the region of increased echogenicity in US is detected only later [9]. This supports the differential diagnosis between hemorrhagic and ischemic infarction. The EEG frequently shows epileptic discharges (patients 1–4, 6) corresponding to the localization of the infarct.

The prognosis of pure ischemia in the newborn as suggested by our experience and the literature [9] seems to be good. So far, therapeutic considerations have not been forthcoming. Undoubtedly, prophylaxis is important in elimination of risk factors [20]. Unfortunately, follow-up studies of larger groups are still awaited. Etiologically unexplained mild hemiparesis, focal fits, porencephalic defects, focal atrophies, and unilateral ventricular asymmetry may be the sequelae of infarction in the neonatal period [9].

Finally, cerebral ischemia and intracranial hemorrhage must not be considered as isolated entities. In the US of some patients, we detected ischemic lesions as well as hemorrhages of various extent. Using Doppler sonography, we saw decreased blood flow in the hemisphere ipsilateral to the bleeding. This fact was already known from positron-emission tomography [18]. Cerebral hemorrhage may even be a marker for underlying generalized or localized hypoxia. Transitional stages are possible; their extent is variable as can be seen in the transient ischemias of patients 5 and 6.

The prognostic value of a single result of only one method is limited. Thus, the prognosis of a sonographically detected cerebral hemorrhage very much depends on the simultaneous hypoxic-ischemic injury, which can only be estimated by considering all available data and taking into account the clinical course, the case history, and the result of further diagnostic procedures.

References

1. Babcock DS, Ball W (1983) Postasphyxial encephalopathy in fullterm infants: ultrasound diagnosis. *Pediatr Radiol* 14: 417–423
2. Barmada MA, Moosy J, Shumann RM (1979) Cerebral infarction with arterial occlusion in neonates. *Ann Neurol* 6:495–502
3. Donn SM, Bowerman RA (1982) Neonatal posthemorrhagic porencephaly. *Am J Dis Child* 136:707–709
4. Eder M, Gedigk P (1974) *Lehrbuch der allgemeinen Pathologie und der pathologischen Anatomie*. Springer, Berlin Heidelberg New York
5. Hill A, Melson GL, Clark HB, Volpe JJ (1982) Hemorrhagic periventricular leukomalacia: diagnosis by real time ultrasound and correlation with autopsy findings. *Pediatrics* 69: 282–284
6. Hill A, Martin DJ, Daneman A, Fitz CR (1983) Focal ischemic cerebral injury in the newborn: diagnosis by ultrasound and correlation with computed tomographic scan. *Pediatrics* 71:790–793
7. Levene MI, Wigglesworth JS, Dubowitz V (1983) Hemorrhagic periventricular leukomalacia in the neonate: a real-time ultrasound study. *Pediatrics* 71:794–797
8. Lütschig J, Hänggeli C, Huber P (1983) The evolution of cerebral hemispheric lesions due to pre-or perinatal asphyxia (clinical and neuroradiological correlation). *Helv Paediatr Acta* 38:245–254
9. Mannino FL, Trauner DA (1983) Stroke in neonates. *J Pediatr* 102:605–609
10. Mantovani JF, Gerber GJ (1984) "Idiopathic" neonatal cerebral infarction. *Am J Dis Child* 138:359–362
11. Nwasei CG, Pape KE, Martin DJ, Becker LE, Fitz CR (1984) Periventricular infarction diagnosed by ultrasound: a post-mortem correlation. *J Pediatr* 105:106–110
12. O'Brien MJ, Ash JM, Gildy DL (1979) Radionuclide brain scanning in perinatal hypoxia-ischemia. *Dev Med Child Neurol* 21:161
13. Pape KE, Bennett-Britton S, Szymonowicz W, Martin DJ, Fitz CR, Becker L (1983) Diagnostic accuracy of neonatal brain imaging: a postmortem correlation of computer tomography and ultrasound scans. *J Pediatr* 102:275–280
14. Slovis TL, Shankaran S (1984) Ultrasound in the evaluation of hypoxic-ischemic injury and intracranial hemorrhage in neonates: the state of the art. *Pediatr Radiol* 14:67–75
15. Straßburg HM, Pringsheim W, Bohlender R (1983) Diagnostik generalisierter und fokaler Hirnödemie mittels der Duplex-Scan Technik beim Neugeborenen. In: Dudenhausen J, Saling E (eds) *Perinatal medicine*, vol 9. Thieme, Stuttgart, pp 343–344
16. Szymonowicz W, Schafner K, Cussen LJ, Yu VYH (1984) Ultrasound and necropsy study of periventricular haemorrhage in preterm infants. *Arch Dis Child* 59:637–642
17. Volpe JJ (1981) *Neurology of the newborn*. Saunders, Philadelphia
18. Volpe JJ, Herscovitch P, Perlman JM, Raichle ME (1983) Positron emission tomography in the newborn: extensive impairment of regional cerebral blood flow with intraventricular hemorrhage and hemorrhagic intracerebral involvement. *Pediatrics* 72:589–601
19. Voorhies TM, Lipper EG, Lee BCP, Vanucci RC, Auld PAM (1984) Occlusive vascular disease in asphyxiated newborn infants. *J Pediatr* 105:92–96
20. Wörle H, Vermold H (1984) Hypoxisch-ischämische Encephalopathie. *Klinische Voraussetzungen*. *Pädiatr Pädol* 19: 355–364