

Akinetic Mutism in a Bone Marrow Transplant Recipient Following Total-Body Irradiation and Amphotericin B Chemoprophylaxis

A Positron Emission Tomographic and Neuropathologic Study

Orin Devinsky, MD; Walter Lemann, MD; Alan C. Evans, PhD; James R. Moeller, PhD; David A. Rottenberg, MD

● We describe a case of akinetic mutism associated with diffuse cerebral leukoencephalopathy, which developed in a bone marrow transplant recipient following total-body irradiation and amphotericin B chemoprophylaxis. A trial of high-dose bromocriptine did not stimulate purposeful verbal or motor activity. Fluorine 18-fluorodeoxyglucose/positron emission tomographic studies, performed before and during bromocriptine therapy, demonstrated cerebral hypometabolism and treatment-related decreases in regional cerebral blood volume. We conclude that whole-brain or total-body irradiation may increase blood-brain barrier permeability to polyene antibiotics, and that high-dose therapy with dopamine agonists is unlikely to benefit patients with akinetic mutism due to diffuse white-matter lesions.

(*Arch Neurol* 1987;44:414-417)

Akinetic mutism was originally described by Cairns et al¹ as a condition in which the patient appears to be awake and may follow

the examiner with his eyes, but spontaneous motor and verbal responses are lacking; he is doubly incontinent and responds incompletely to noxious stimuli. Akinetic mutism following bilateral damage to the frontal lobes (including cingulate and orbital gyri and the septal area)^{2,4} and small lesions of the paramedian reticular formation in the diencephalon and midbrain has been described.^{5,7}

This article describes the clinical history of a bone marrow transplant recipient in whom the rapid onset of akinetic mutism in the setting of amphotericin chemoprophylaxis for systemic fungal infections was associated with widespread demyelination of cerebral white matter. Fluorine 18-fluorodeoxyglucose (¹⁸FDG)/positron emission tomographic (PET) scans were performed before and during a therapeutic trial of bromocriptine to study the effect of this direct dopamine agonist on regional cerebral metabolic rate for glucose (rCMRglu).

REPORT OF A CASE

A 23-year-old right-handed man was admitted to Memorial Sloan-Kettering Cancer Center (MSKCC), New York, in August 1985, for evaluation of aplastic anemia. Results of a neurologic examination on admission were normal. After pretreatment with cyclophosphamide and 1500 rad (15 Gy) total-body irradiation, bone marrow transplantation was successfully performed in mid-November, and he

was discharged from the hospital in early January 1986, having been afebrile for two weeks. At the time of discharge, he was fully ambulatory, and his mental status was normal. During his five-month hospitalization he received multiple antibiotics, including intravenously administered cefotaxime sodium, ticarcillin disodium, tobramycin sulfate, vancomycin hydrochloride, acyclovir, and amphotericin B (total dose, 5.67 g).

Seven days after hospital discharge, his family reported aggressive behavior, confusion, and lethargy. When readmitted to the hospital five days later, his vital signs were normal, and his neck was supple. There was little spontaneous verbal or motor activity, his affect was flat, and his responses to questions were often delayed. Although language function appeared intact, he was confused and disoriented. His gait was slow and shuffling. Within a week after admission, he was unable to follow verbal commands; however, sleep-wake cycles were present, and visual fixation and following movements were retained. Three weeks after admission, he was akinetic and mute, with marked hypertonia, prominent grasp and snout reflexes, hyperactive deep tendon reflexes, and a right extensor plantar response. Brain-stem reflexes were intact, and he would intermittently blink to visual threat. Noxious stimuli prompted slow and incomplete withdrawal.

Results of admission laboratory studies were normal, and a screen for intoxicants (ethanol, narcotics, barbiturates, and benzodiazepines) were negative. Serial platelet counts and coagulograms were within normal limits. Neither acute nor convalescent serum titers for herpes simplex virus

Accepted for publication Jan 9, 1987.

From the Department of Neurology, Memorial Sloan-Kettering Cancer Center (Drs Lemann, Moeller, and Rottenberg), the Department of Neurology, Cornell University Medical College (Dr Devinsky), New York, and the Brain Imaging Center, Montreal Neurological Institute and Hospital, Montreal (Dr Evans).

Reprint requests to Department of Neurology, Memorial Sloan-Kettering Cancer Center, 1275 York Ave, New York, NY 10021 (Dr Rottenberg).

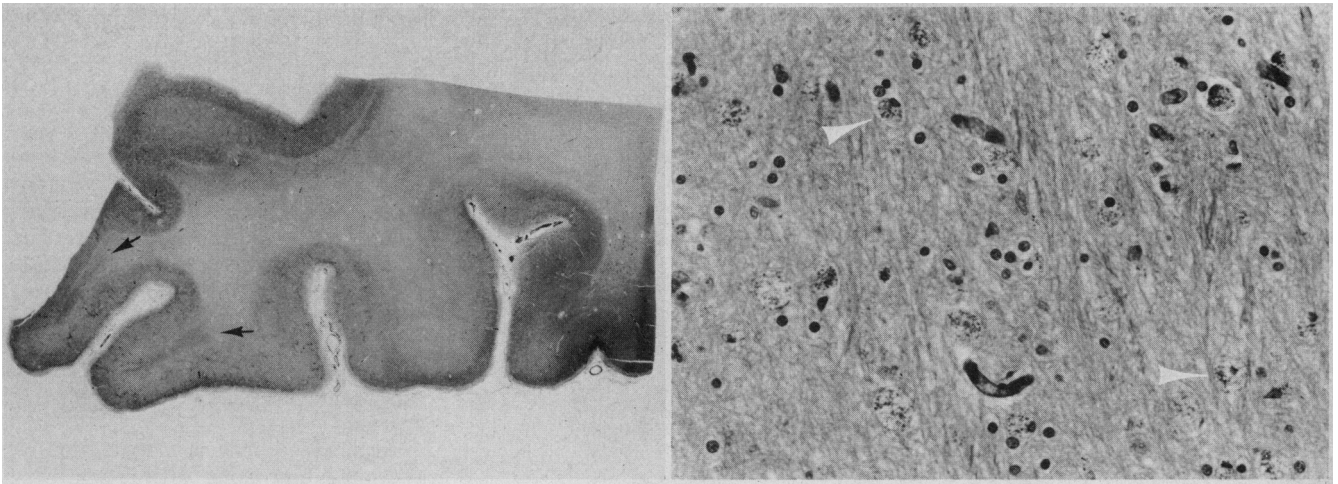


Fig 1.—Left, Section of cerebrum stained for myelin with Luxol Fast Blue-periodic acid-Schiff reagent. Except for two small tongues of intragryal myelin (arrows), there is virtual total myelin loss, including subcortical U fibers. Right, High-magnification view of cerebral white matter illustrating marked vacuolation and infiltration by lipid-laden macrophages with dark granular cytoplasm (arrowheads) (X100).

(HSV) or cytomegalovirus (CMV) were significantly elevated. The results of four lumbar punctures were as follows: opening pressures ranged between 90 and 180 mm of cerebrospinal fluid (CSF); there were mononuclear cells, 4 to 9/mm³ (4 to 9 × 10⁶/L); protein, 11 to 52 mg/dL (0.61 to 2.9 mmol/L); and glucose, 62 to 90 mg/dL (0.62 to 0.90 g/L). Cerebrospinal fluid cultures for virus, bacteria, and fungi, as well as VDRL and CSF cytology were negative. Cerebrospinal fluid titers for coxsackievirus, HSV, CMV, cryptococcal antigen, and *Toxoplasma* (immunofluorescent antibody and IgM) were all less than 1:16. Computed tomographic scanning with and without iodinated contrast was normal on admission and again 12 days later. Magnetic resonance imaging revealed areas of white matter hyperintensity on T2-weighted images, especially in the frontal lobes, but also in the temporal and parietal lobes.

One month after admission, bromocriptine was started at a dose of 2.5 mg administered orally every eight hours and increased, over a nine-day period, to 30 mg every six hours. There was no change in the patient's mental status during treatment. When the total daily dose exceeded 80 mg, orofacial and upper-body dyskinesias developed. These side effects ultimately led to a discontinuation of treatment after three weeks. Prolactin and growth hormone levels decreased dramatically during therapy: prolactin fell from 9.8 ng/mL to nondetectable, and growth hormone fell from 10.1 to 0.4 ng/mL. Fluorine 18-fluorodeoxyglucose/PET scans were performed before bromocriptine therapy and after two weeks of therapy when the patient's daily dose was 80 mg.

Two months after admission the patient developed aspiration pneumonia, followed by progressive respiratory deterioration. He died on April 19, three months after the onset of his neurologic illness.

¹⁸FDG/PET Measurements of Regional Cerebral Blood Volume (rCBV) and Metabolic Rate for Glucose (rCMRGlu) Before and During a Trial of High-Dose Bromocriptine (80 mg/d)*

Region of Interest	Before Treatment		During Treatment	
	rCBV	rCMRGlu	rCBV†	rCMRGlu‡
L Cerebellum	5.93	4.80	3.58	4.03
R Cerebellum	6.26	5.09	4.27	3.93
Medulla/pons	6.22	3.96	2.73	2.33
Midbrain	6.78	3.03	5.45	2.71
L basal ganglia	4.34	3.89	3.62	3.93
R basal ganglia	3.86	3.19	3.80	3.81
L thalamus	4.20	4.08	2.61	2.63
R thalamus	3.39	3.09	2.83	2.91
L hippocampus	3.60	4.52	2.79	2.79
R hippocampus	5.72	4.14	2.90	3.44
L lateral temporal cortex	4.26	3.39	3.73	2.76
R lateral temporal cortex	4.37	3.02	3.98	3.47
L opercular cortex	5.85	4.90	5.10	4.71
R opercular cortex	7.10	3.47	3.52	4.43
L posterior temporal cortex	4.73	3.94	2.69	3.96
R posterior temporal cortex	3.52	3.46	2.69	2.92
L medial frontal cortex	5.03	3.39	2.83	2.84
R medial frontal cortex	3.80	2.94	3.30	2.87
L lateral frontal cortex	3.78	3.36	2.65	2.85
R lateral frontal cortex	4.10	3.43	2.73	2.96
L calcarine cortex	5.16	4.11	3.09	2.60
R calcarine cortex	4.15	3.55	2.86	2.71
L cuneus	4.64	3.30	3.02	3.41
R cuneus	4.32	3.41	2.71	2.75
L inferior parietal cortex	4.60	4.58	3.33	4.40
R inferior parietal cortex	4.71	4.79	3.70	4.59
L paracentral cortex	3.44	4.16	3.92	3.57
R paracentral cortex	6.28	4.32	3.66	3.38
Mean	4.79	3.83	3.36	3.35
L centrum semiovale	2.08	1.36	1.17	1.72
R centrum semiovale	2.28	1.92	1.82	2.16

*¹⁸FDG/PET indicates fluorine 18-fluorodeoxyglucose/positron emission tomography. Values are expressed as follows: rCBV, milliliters per 100 g; rCMRGlu, milligrams per minute per 100 g.

†P < .001 vs before treatment.

‡P < .005 vs before treatment.

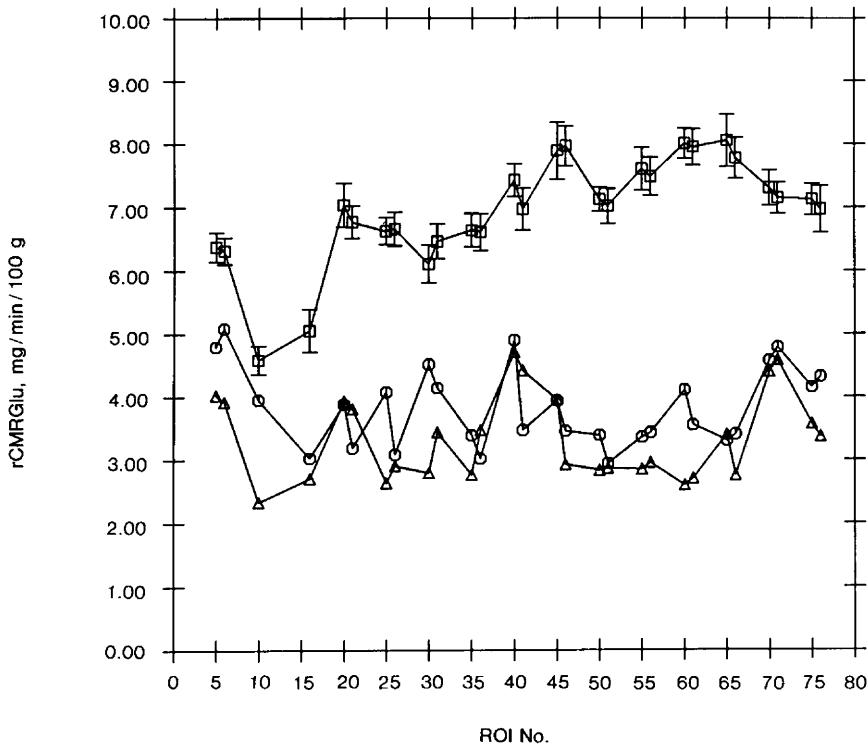


Fig 2.—Metabolic profiles for “before” (circles) and “during” (triangles) bromocriptine fluorine 18–fluorodeoxyglucose/positron emission tomographic studies compared with mean profile for 18 normal controls (squares); error bars on control profile represent standard error of the mean. Regional cerebral metabolic rate for glucose (rCMRGlucose, milligrams per minute per 100 g) on ordinate is plotted against anatomical region on abscissa, coded as follows: 5, cerebellum; 10, brain stem; 15, midbrain; 20, basal ganglia; 25, thalamus; 30, hippocampus; 35, lateral temporal cortex; 40, opercular cortex; 45, posterior temporal cortex; 50, medial frontal cortex; 55, lateral frontal cortex; 60, calcarine cortex; 65, cuneus; 70, inferior parietal cortex; 75, paracentral cortex. Closely spaced data points refer to left and right, respectively. ROI indicates region of interest.

RESULTS

Neuropathologic Findings

Gross examination of the formaldehyde-fixed brain disclosed mild cortical atrophy. Microscopically, the cerebral cortex and deep gray structures were normal. Examination of the white matter revealed myelin pallor, vacuolation, diffuse infiltration with lipid-laden macrophages, and marked reactive fibrillary astrocytosis (Fig 1). These changes were less prominent in infratentorial white matter. Relative preservation of axons was demonstrated by Bodian staining. No viral inclusions or microorganisms were identified, and immunostaining for HSV, herpes zoster, CMV, and *Toxoplasma* was negative.

Positron Emission Tomography

Informed consent for the ^{18}F FDG/PET studies was obtained from the patient's next of kin. The ^{18}F FDG, produced by a modification of Tewson's synthesis,⁸ was greater than 97% radiochemically pure. Serial PET images were acquired with a positron camera⁹ (PC 4600) following the injection of tracer (5 mCi), while the sub-

ject lay quietly in the scanner gantry with eyes patched, listening to light music through acoustically isolated earphones. The time course of plasma fluorine 18 radioactivity was determined by sampling radial arterial blood and counting aliquots of plasma in a scintillation well detector.

Region-of-interest (ROI) analysis was performed on 128×128 PET reconstructions that were corrected for random coincidences, tissue attenuation (transmission scan), and electronic deadtime; a single scalar correction was used to compensate for scatter effects in transmission, cross-calibration, and emission scans. Twenty-four (12 per hemisphere) standardized cortical and subcortical ROIs were outlined on reconstructed PET brain slices with reference to coplanar CT scans; two cerebellar, two brain-stem, and two white-matter ROIs were also defined (Table).

Compartmental rate constants (k_1 , k_2 , k_3) and regional cerebral blood volume (rCBV) were estimated from the time course of blood and regional brain radioactivity.¹⁰ Regional cere-

bral metabolic rate for glucose was then calculated directly as:

$$C_p/LC \cdot k_1 k_3 / (k_2 + k_3),$$

where LC is Sokoloff's lumped constant,¹¹ and C_p is plasma glucose concentration. A thresholding strategy was used to obtain mean ROI radioactivity concentration as a function of time for rate constant determination: the upper 15% of ROI pixel values were highlighted on the last ten-minute scan, and the corresponding pixel coordinates were then stored and “replayed” on the entire set of 21 frames.

Accurate patient repositioning (within 1 mm along with Z-axis) was facilitated by means of a custom-molded polyurethane headholder-immobilizer (Smithers Medical Products, Hudson, Ohio) and crossed lasers. Regional cerebral blood volume and rCMRGlucose values derived from the same gray-matter and white-matter ROIs on pre- and post-treatment ^{18}F FDG/PET studies (Table) were compared using the signed-rank test.¹² The observed decreases in rCBV and rCMRGlucose, although highly statistically significant ($P < .001$ and $P < .005$, respectively), most likely reflect a global reduction in cerebral metabolic rate. “Before”-“during” ratios (BDRs) were computed using the rCBV and rCMRGlucose data in the Table. Regional BDRs were then compared with their corresponding mean (across regions) BDR. Only one regional BDR (medulla; pons; Table) in each dataset deviated from its corresponding mean BDR by more than two SDs.

Figure 2 depicts metabolic profiles for the “before” and “during” ^{18}F FDG/PET studies compared with the mean profile for 18 normal volunteer subjects aged 27 ± 5 years (mean \pm SD), who had no history of recent medical illness, neurologic or psychiatric disease, developmental disorder, or substance abuse. All control subjects underwent a complete neurologic examination and neuropsychologic evaluation prior to FDG/PET scanning. In comparison with normal controls, rCMRGlucose in both patient studies is markedly reduced, and the corresponding metabolic profiles are noticeably altered; the depression of frontal, posterior temporal, and occipital rCMRGlucose (ROIs 45 to 65) is especially striking in the scan performed during treatment.

COMMENT

In our patient, akinetic mutism was associated with global cerebral hy-

pometabolism and widespread lesions in cerebral and cerebellar white matter. Administration of high-dose bromocriptine mesylate, a dopamine agonist that stimulates D2 (nonadenyl cyclase-linked) receptors,¹³ was not clinically beneficial and was associated with severe dyskinesias and reduced rCBV and rCMRglu.

The following features of our patient's illness are consistent with previous descriptions of akinetic mutism: (1) absence of prior stupor or coma; (2) lack of spontaneous verbal and motor responses; (3) minimal response to noxious stimuli; (4) lack of primary motor or sensory deficits to account for akinesia; (5) inability to signal yes or no in response to simple questions with voluntary eye movements; (6) preservation of sleep-wake cycles; and (7) intermittent, seemingly purposeful, conjugate eye movements ("following movements"). Neuropathologic examination disclosed widespread destruction of cerebral and cerebellar white matter, most severe in the frontal lobes. This localization is consistent with previous reports of akinetic mutism with bilateral frontal damage extending into adjacent limbic and neocortical regions.

The recent report by Ellis et al¹⁴ of leukoencephalopathy in patients treated with amphotericin B methyl ester, a more soluble anionic form of amphotericin B, suggests that radiation-induced enhancement of blood-brain barrier permeability to amphotericin B was responsible for our patient's neurologic deterioration. Ellis et al¹⁴ described 14 patients with mycotic infections who were treated with intravenously and/or intrathe-

cally administered amphotericin B methylester; all seven patients who received more than 9.8 g of intravenous amphotericin B methyl ester administered intravenously developed severe neurologic disorders, including dementia and akinetic mutism. The role of amphotericin B in producing this neurologic/neuropathologic syndrome remains unproved,¹⁵ but the similarities between the clinical and pathologic features of our patient and the patients reported by Ellis et al are striking indeed. In our patient, amphotericin B was the only medication administered during the two weeks prior to the onset of his neurologic illness. The lack of previous reports of akinetic mutism and leukoencephalopathy complicating amphotericin B treatment is noteworthy, suggesting that increased blood-brain barrier permeability to amphotericin—in this case, as a result of total-body irradiation—may be a necessary precondition to the development of irreversible neurotoxicity.

Ross and Stewart¹⁶ successfully treated a patient with akinetic mutism secondary to postsurgical anterior hypothalamic damage. Stuporous postoperatively, their patient evolved after two weeks into an akinetic mute state. After treatment with lergotril mesylate, a direct dopamine agonist, and bromocriptine mesylate (up to 110 mg daily), he could converse and ambulate without assistance. In our patient, treatment with bromocriptine in doses up to 120 mg daily had no therapeutic effect, but resulted in dose-dependent orofacial and upper-body dyskinesias. The therapeutic success of direct dopa-

mine agonists in Ross and Stewart's patient and the failure of bromocriptine in our patient suggests that the location of the lesion producing akinetic mutism may be important in determining therapeutic response.

Levodopa and the dopamine agonists pibedil and apomorphine affect cerebral hemodynamics and metabolism in baboons and in man; widespread increases in cerebral blood flow, cerebral metabolic rate for oxygen, and cerebral metabolic rate for glucose have been reported.¹⁷⁻²⁰ These experimental results, and the results of PET studies of patients with Parkinson's disease^{21,22} led us to anticipate an increase in rCMRglu during bromocriptine therapy. However, the results of our "before" and "during" ¹⁸F-DG/PET studies indicate that (in an akinetic mute patient) high-dose bromocriptine does not stimulate cerebral glucose metabolism and may even produce marked regional reductions in rCMRglu. We have no explanation for our finding of reduced rCBV during bromocriptine therapy, although it may reflect a proportional decrease in rCBF, coupled to the observed decrease in rCMRglu.

A fuller understanding of the cerebral hemodynamic and metabolic consequences of bromocriptine therapy awaits serial PET measurements of rCBV, rCBF, and rCMRglu in normal volunteer subjects and in patients with Parkinson's disease and altered consciousness.

This work was supported by grants NS-03346 and NS-23473 from the National Institutes of Health, Bethesda, Md.

We wish to thank Maria Sergi for assistance with data analysis and Adele Ahronheim for manuscript preparation.

References

1. Cairns H, Oldfield RC, Pennybacker JB, et al: Akinetic mutism with an epidermoid cyst of the third ventricle. *Brain* 1941;64:273-290.
2. Nielsen JM, Jacobs LL: Bilateral lesions of the anterior cingulate gyri. *Bull Los Angeles Neurol Soc* 1951;16:231-234.
3. Barris RW, Schuman HR: Bilateral anterior cingulate gyrus lesions. *Neurology* 1953;3:44-52.
4. Freeman FR: Akinetic mutism and bilateral anterior cerebral artery occlusion. *J Neurol Neurosurg Psychiatry* 1971;34:693-698.
5. Cravioto H, Silberman J, Feigin I: A clinical and pathologic study of akinetic mutism. *Neurology* 1960;10:10-21.
6. Kemper TL, Romanul FCA: State resembling akinetic mutism in basilar artery occlusion. *Neurology* 1967;17:74-80.
7. Skultety FM: Clinical and experimental aspects of akinetic mutism. *Arch Neurol* 1968;19:1-14.
8. Tewson TJ: Synthesis of no-carrier-added fluorine-18 2-fluoro-2-deoxyglucose. *J Nucl Med* 1983;24:718-721.
9. Kearfott KJ, Carroll LR: Evaluation of the performance characteristics of the PC 4600 Positron Emission Tomograph. *J Comput Assist Tomogr* 1984;8:502-513.
10. Evans AC, Diksic M, Yamamoto YL, et al: Effect of vascular activity in the determination of rate constants for the uptake of ¹⁸F-labelled 2-fluoro-2-deoxy-D-glucose: Error analysis and normal values in older subjects. *J Cereb Blood Flow Metab* 1986;6:724-738.
11. Reivich M, Alavi A, Wolf A, et al: Glucose metabolic rate kinetic model parameter determination in humans: The lumped constants and rate constants for [¹⁸F]fluorodeoxyglucose and [¹⁴C]-deoxyglucose. *J Cereb Blood Flow Metab* 1985; 5:178-192.
12. Snedecor GW, Cochran WG: *Statistical Methods*, ed 7. Ames, The Iowa State University Press, 1980.
13. Lieberman AN, Goldstein M: Bromocriptine and Parkinson's disease. *Pharmacol Rev* 1985;37:217-227.
14. Ellis WG, Sobel RA, Nielsen FL: Leukoencephalopathy in patients treated with amphotericin B methyl ester. *J Infect Dis* 1982;146:125-137.
15. Hoeprich PD: Amphotericin B methyl ester and leukoencephalopathy: The other side of the coin. *J Infect Dis* 1982;146:173-176.
16. Ross ED, Stewart RM: Akinetic mutism from hypothalamic damage: Successful treatment with dopamine agonists. *Neurology* 1981; 31:1435-1439.
17. Teasdale G, McCullough J: Effect of stimulation of dopaminergic receptors upon local cerebral blood flow. *Acta Neurol Scand* 1977;56:98-99.
18. McCullough J, Harper AM: Dopaminergic systems and the cerebral circulation. *Acta Neurol Scand* 1977;54:100-101.
19. McCullough J, Edvinsson L: Cerebral circulatory metabolic effects of pibedil. *Eur J Pharmacol* 1980;66:327-337.
20. Guell A, Geraud G, Jauzac PH, et al: Effects of a dopaminergic agonist (pibedil) on cerebral blood flow in man. *J Cereb Blood Flow Metab* 1982;2:255-257.
21. Leenders KL, Wolfson L, Jones T: Cerebral blood flow and oxygen metabolism measurement with positron emission tomography in Parkinson's disease. *Monogr Neurol Sci* 1984;11:180-186.
22. Wolfson LI, Leenders KL, Brown LL, et al: Alterations of regional cerebral blood flow and oxygen metabolism in Parkinson's disease. *Neurology* 1985;35:1399-1405.