

## Case Report

**Relapsing MOG-IgG-associated diseases coexisting with anti-NMDAR encephalitis: a case report and literature review**Mengmeng Wang<sup>1</sup>, Jing Tan<sup>1</sup>, Ziyang Zhou<sup>1</sup>, Yihan Wang<sup>1</sup>, Samira Yerima Bako<sup>2</sup>, Yaoqiang Yang<sup>3</sup>, Yongzhong Lin<sup>1,\*</sup><sup>1</sup>Department of Neurology, The Second Hospital of Dalian Medical University, 116027 Dalian, Liaoning, China<sup>2</sup>Department of Cardiology, The Second Hospital of Dalian Medical University, 116027 Dalian, Liaoning, China<sup>3</sup>Department of Neurosurgery, Yantian District People's Hospital, 518000 Shenzhen, Guangdong, China\*Correspondence: [lin19671024@163.com](mailto:lin19671024@163.com) (Yongzhong Lin)

Academic Editor: Mauro Silvestrini

Submitted: 25 April 2021 Revised: 10 May 2021 Accepted: 22 July 2021 Published: 11 April 2022

**Abstract**

**Background:** In recent years, an overlapping syndrome, MNOS, of MOG encephalomyelitis and NMDARE has been clinically identified. In these diseases, both MOG-Ab and NMDAR-Ab are positive. Previous studies were almost case reports and incomprehensive which focused on this kind of overlapping syndrome in adults. **Methods:** We reported a rare case of MNOS. In addition, we reviewed the clinical characteristics, diagnosis, and treatment of MNOS in adults by consulting relevant literature. **Results:** The patient initially presented with CNS demyelination symptoms followed by recurrent encephalitis, concomitant anti-MOG, and NMDAR antibodies. His symptoms improved significantly after initiating hormonal therapy. We searched previous MNOS case reports and 17 adult MNOS cases were retrieved. The previous history of all patients was unremarkable. Most of these patients (72.2%, 13/18) first developed NMDR encephalitis-related symptoms, such as cognitive behavior abnormalities, cognitive decline, and epilepsy. Some patients (16.7%, 3/18) first developed MOG-related demyelinating symptoms, such as visual deterioration, walking instability, and dizziness. The most common site of new brain lesions was the supratentorial region. In the acute phase, MNOS patients were sensitive to hormone therapy. During the follow-up, 72.2% (13/18) of the patients relapsed, with a median interval of 12.25 months. Immunotherapy was still effective after recurrence, and no deaths were reported. **Conclusions:** (1) The clinical manifestations of MNOS are atypical, sometimes like MOG encephalomyelitis, sometimes like NMDARE, sometimes both of the characteristic clinical manifestations are present. (2) Immunotherapy is the primary treatment of patients with MNOS. (3) MNOS are prone to recurrence, and serum MOG and tumor markers should be monitored.

**Keywords:** Myelin oligodendrocyte glycoprotein (MOG); N-methyl-D-aspartate receptor (NMDAR); Anti-N-methyl-D-aspartate receptor; Autoimmune encephalitis (AIE)

**1. Introduction**

In 2007, O'Connor *et al.* [1] described anti-Myelin Oligodendrocyte Glycoprotein (anti-MOG) antibodies in children with Acute Disseminated Encephalomyelitis (ADEM) by tetramer radioimmunoassay for the first time. Research results in recent years indicate that MOG-IgG-associated diseases may be an independent disease, different from Multiple Sclerosis (MS), ADEM, and AQP4-IgG-positive Neuromyelitis Optica Spectrum Disorder (NMOSD) [2]. The clinical features of MOG-IgG-associated diseases in adults were mainly optic nerve damage, spinal cord damage and lenient reoccurrence [2]. MOG encephalomyelitis rarely presents the following symptoms: mental behavior abnormalities, epilepsy, and cognitive impairment, which manifest in N-Methyl-D-Aspartate Receptor (NMDAR) encephalitis [3]. The immune coexistence of MOG and NMDAR antibodies is not common. In recent years, several cases have been reported. And the overlapping syndrome of MOG-Ab disease and anti-NMDAR encephalitis (NMDARE) was

abbreviated as MNOS [4]. We report a patient who initially presented with Central Nervous System (CNS) demyelination symptoms followed by recurrent encephalitis, concomitant anti-MOG, and NMDAR antibodies. Furthermore, we analyzed the clinical features of MNOS in adults.

**2. Case report**

A 36-year-old male developed a headache in late December 2018. Seven days later, he experienced left facial numbness and slurred speech (Table 1). Neurological examination revealed slurred speech, stiff neck, and decreased left facial perception. Magnetic Resonance Imaging (MRI) revealed a fluid attenuation inversion recovery (FLAIR) high-intensity lesion involving the left pontine and cerebral peduncle, and the boundaries were unclear with a range of about 20 × 11 mm (Fig. 1A,B). The pressure of the Cerebrospinal Fluid (CSF) was 205 mmH<sub>2</sub>O. And the CSF examination revealed elevated leukocytes (170/μL; 34% mononuclear). Herpes Simplex Virus (HSV) DNA,



Japanese encephalitis virus nucleic acid, Cytomegalovirus (CMV) DNA, and Varicella-Zoster Virus (VZV) nucleic acid and were all negative in CSF. Virus antibodies (HSV I, II, EB, CMV, and rubella virus) were tested in serum and only IgG antibodies against HSV I, CMV, and Epstein–Barr (EB) virus were positive. There were no apparent abnormalities in the 24-hour video electroencephalogram (VEEG). Cervical spine MRI, macular Optical Coherence Tomography (OCT), visual evoked potentials, auditory brainstem response, and somatosensory evoked potentials were normal. He was treated empirically with intravenous acyclovir for 2 days without any amelioration. Furthermore, the CNS demyelinating antibody test, serum and CSF MOG-Abs were positive (cell-based assays: CBAs). CSF and serum Aquaporin-4 (AQP4) antibodies, Myelin Basic Protein (MBP) were all negative. We also detected positive anti-NMDAR antibodies in serum with a titer of 1:10, followed by negative anti-NMDAR antibodies in CSF. Due to the high sensitivity and specificity of CSF testing for NMDAR encephalitis [5–8], the patient was diagnosed with MOG-IgG-associated diseases instead of anti-NMDAR encephalitis and treated with intravenous dexamethasone (10 mg/day) during the first episode. The symptoms of headache, left facial numbness and slurred speech were quickly relieved. Prior to patient discharge, dexamethasone was switched to oral prednisone on gradual tapering. On the 17th day, he was discharged without any sequela. On check-ups following discharge, we noted a significant diminishment of the CNS demyelinating lesion on MRI (Fig. 1C,D). Repeated examinations of serum MOG antibodies were still positive (3/1/2019, 19/2/2019, 6/5/2019, 28/2/2020). In March 2019, the patient was non-compliant with the steroids.

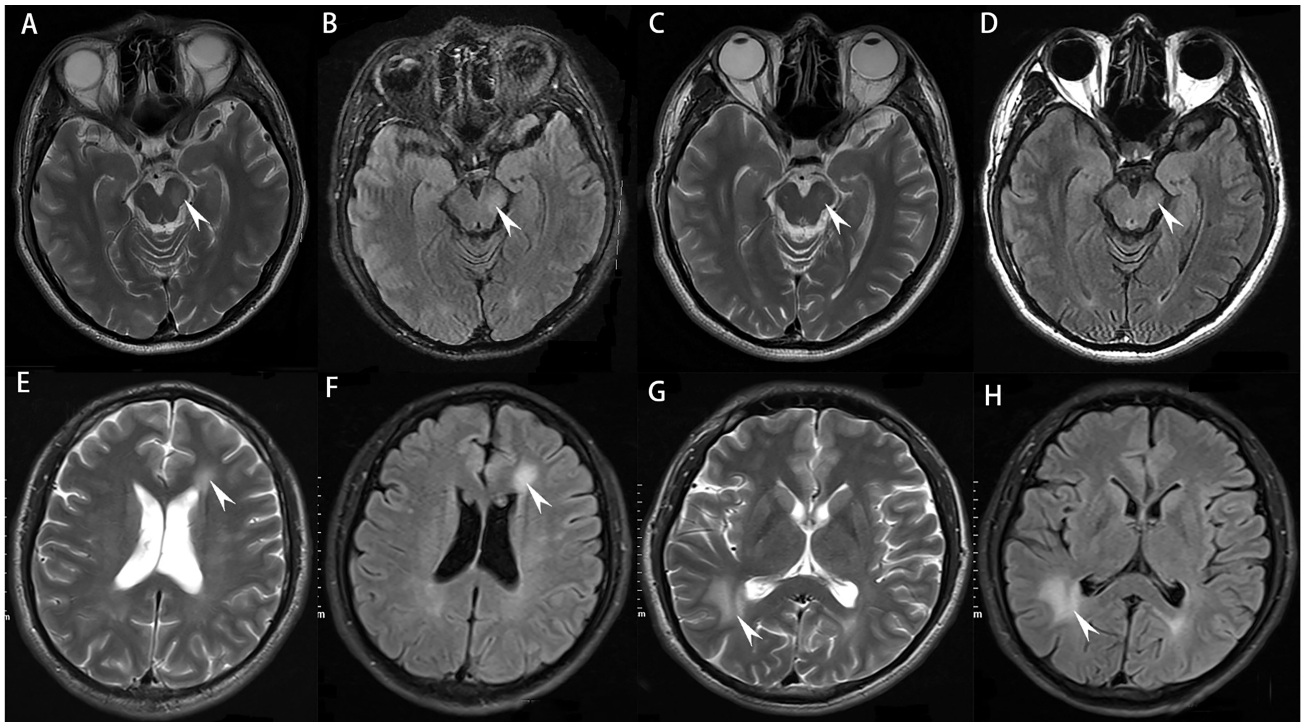
In late February 2020, the patient fell and had a fracture of the left humerus. A week later, he developed behavioral changes and psychosis. Dominant symptoms were mental excitement, speaking too much, and forgetting his general knowledge of objects. Neurological examination revealed finger agnosia, acalculia and left-right disorientation. MRI demonstrated deep white matter demyelination lesions in the left lateral ventricle frontal and right lateral ventricle occipital angles (Fig. 1E–H). Cervical and thoracic MRI showed no abnormality. CSF biochemistry was normal. The serum MOG antibody and CSF NMDAR antibody, which were re-examined in the same laboratory as previous tests (Table 1), were both positive. Other antibodies related to autoimmune encephalitis and paraneoplastic syndrome in serum and CSF were negative. Blood tests for other systematic autoimmune diseases were normal. Furthermore, serum tumor markers were negative and the abdominal CT scan revealed no underlying neoplasm (not shown). This time positive NMDAR antibodies in the CSF were found. Therefore, High Dose Methylprednisolone pulse Therapy (HDMT) and oral mycophenolate mofetil therapy were added. His symptoms improved sig-

nificantly after therapy. Throughout his one year follow-up, no recurrence was observed. Assays for serum and CSF MOG-Ab, MBP-Ab, NMDAR-Ab, LGI1-Ab, CASPR2-Ab, AMPAR1/R2-Ab, and GABAB R-Ab were carried out at Beijing Hightrust diagnostic Medical Diagnostics Laboratory (Beijing Hightrust Diagnostics, Co., Ltd) by cell-based Indirect Immune-Fluorescence Test (IIFT) employing BIOCHIPS. An AQP4-Ab was carried out by Enzyme-Linked Immunosorbent Assay (ELISA). Written informed consent for publication was obtained from the patient. The Medical Ethics Committee approved the study of the Second Hospital of Dalian Medical University.

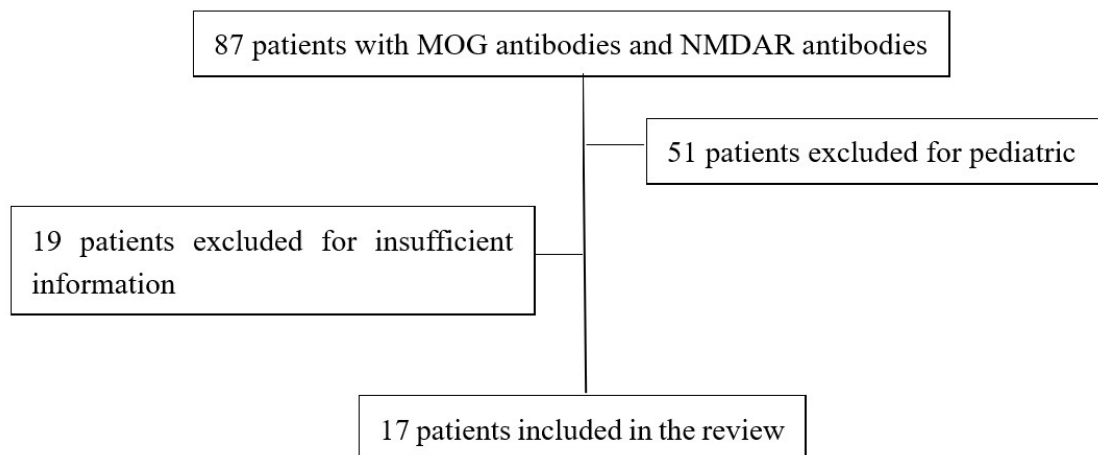
### 3. Results of the literature review

We searched PubMed (Medline) through May 11, 2021, for articles published in any language with the search string (“Receptors, *N*-Methyl-D-Aspartate” [MeSH Terms] OR “*N*-Methyl-D-Aspartate” OR “NMDA”) AND (“Myelin Oligodendrocyte Glycoprotein” [MeSH Terms] OR “MOG”). Furthermore, we also searched the references for related published articles. We examined studies that have presented the cases of overlapping MOG-Ab disease and NMDARE. Our review identified 87 patients with overlapping MOG Ab-associated disorders and anti-NMDAR encephalitis. We excluded 51 pediatric cases because MNOS patients can behave very differently by age spectrum. A further 9 patients were excluded due to insufficient information. Finally, 18 patients (including our case) were included in the review (Fig. 2). All patients fulfilled the diagnostic criteria for definite anti-NMDAR encephalitis and MOG-IgG-associated diseases [2,9].

Of these patients, 7 were female and 11 were male (Table 2 Ref. [4,10–20] and Table 3). The median age at presentation was 30.5 years for adults (range, 18–54). The previous history of all patients was unremarkable, and none had tumors. Most of these patients (72.2%, 13/18) first developed NMDR encephalitis-related symptoms, such as cognitive behavior abnormalities, cognitive decline, and epilepsy. Some patients (16.7%, 3/18) first developed MOG-related demyelinating symptoms, such as visual deterioration, walking instability, and dizziness. During the course of the disease, 44.4% of patients had blurred vision, 61.1% of the patients showed abnormal mental behavior, such as paroxysmal irritability, moodiness, 38.9% of the patients had seizures, 27.8% of the patients showed a cognitive decline, manifested as deterioration of the memory, 22.2% of the patients had speech disorders, manifested as silence aphasia, 27.8% of the patients showed movement disorders, including facial, tongue, and limb movement disorders, 27.8% of the patients showed paresthesia, as numbness, and 38.9% of the patients showed dizziness and walking instability (Tables 2,3). Imaging found that 16/18 (88.9%) of brain MRI showed new lesions during the acute attack. The most common site of new brain lesions was the supratentorial region. In the acute phase,



**Fig. 1. MRI presentations during different episodes.** (A,B) T2-weighted images (T2WI) and fluid-attenuated inversion recovery (Flair) images showed the left pontine and cerebral feet, and the boundaries are unclear with a range of about  $20 \times 11$  mm, in the first episode. (C,D) The follow-up MRI Flair demyelinating lesion diminished significantly: The maximum capacity of MRI at 1 month after discharge is about  $8 \times 6$  mm; (E–H) MRI Flair images during the second episode: Lesions located at left lateral ventricle frontal angle and right lateral ventricular occipital angle.



**Fig. 2. Review flow-chart.**

MNOS patients were sensitive to hormone therapy and most of the patients improved after receiving HDMT. Some patients with severe conditions were treated with Intravenous Immunoglobulin (IVIG) (0.4 g/kg-day, 5 days) or Plasmapheresis (PE). After acute treatment, some patients were treated with oral prednisone (initial 60 mg/day, tapered to 5 mg every 2 weeks). And some were treated with Mycophenolate Mofetil (MMF) (500 mg/day), Ritux-

imab (RTX), Azathioprine (AZA) (100–150 mg/day), Cyclophosphamide (CTX), natalizumab, etc. [10–12]. During the follow-up, 72.2% (13/18) of the patients relapsed, with a median interval of 12.25 months (Tables 2,3). Immunotherapy was still effective after recurrence, and no deaths were reported.

**Table 1. The summary of our patient clinical episodes, treatments and immunological examination outcomes.**

	2019-1	2019-2	2019-4	2020-2
Clinical manifestation	Headache, left facial numbness and slurred speech	normal	normal	Behavioral change and psychosis
Inducement	Caught a cold 1 week ago	na	na	Fracture of left upper limb
Neurological examination	Slurred speech, stiff-neck, left facial perception	normal	normal	Finger agnosia, acalculia, left-right disorientation
CSF	205 mm H <sub>2</sub> O Leucocytes: 170/ $\mu$ L, 34% mononuclear Pandy's test ( $\pm$ )	na	na	normal
Serum MOG-Ab	pos	pos	pos	pos
CSF MOG-Ab	pos	na	na	pos
CSF and serum MBP-Ab, AQP4-Ab	neg	na	na	neg
Serum NMDAR-Ab	pos 1: 10	na	na	pos 1: 10
CSF NMDAR-Ab	neg	na	na	pos 1: 3.2
Autoimmune encephalitis associated antibodies (AMPA1, AMPAR2, CASPR2, GABAR, LGI1)	neg	na	na	neg
Paraneoplastic nerve syndrome associated antibodies (Anti-Hu, Anti-Yo, Anti-Ri, Anti-CV2, Anti-Amphiphysin, Anti-ANNA-3, Anti-Tr, Anti-PCA-2, Anti-GAD, Anti-Ma2)	neg	na	na	neg
Therapy	Dexamethasone (10 mg/day, for 5 days), later prednisone (initial 60 mg/day and decreased 5 mg every 2 weeks)	Prednisone (20 mg/day)	Stop steroid without permission for 1 month	HDMT (1000 mg/day, for 5 days) and MMF (500 mg/day)

MOG, myelin oligodendrocyte glycoprotein; MMF, Mycophenolate Mofetil; NMDAR, *N*-methyl-D-aspartate receptor; AQP4, aquaporin 4; MBP, myelin basic protein; AMPAR, anti-alpha-amino-3-hydroxy-5-methyl-4-isoxazolepropionic acid receptor; CASPR2, contactin-associated protein-like 2; GABAR, anti- $\gamma$ -aminobutyric acid receptor; HDMT, high dose methylprednisolone pulse therapy; LGI1, leucine-rich glioma-inactivated 1; CSF, cerebrospinal fluid; neg, negative; pos, positive; na, not applicable.

**Table 2. Demographic, clinical, and MRI findings in 17 MNOS patients.**

Source	Age at onset, year	Sex	MOG-vs NMDARE-like episodes	MRI findings (Brain/Spine)	Immunotherapy	Disease course	Interval months
Titulaer <i>et al.</i> (2014) [12]							
Case 1	18	F	NMDARE-like episodes	Normal	Steroid, IVIG, PE, CTX, RTX	MONO	0.8
Case 2	45	F	NMDARE-like episodes	Normal	Steroid	MONO	1.8
Kaneko <i>et al.</i> (2014) [14]	28	F	NMDARE-like episodes	In the cerebral deep gray matter and white matter.	HDMP, PRED	RR	-
Zhou <i>et al.</i> (2017) [11]	31	M	NMDARE-like episodes; MOG-like episodes; both	Right side of the cerebral cortex; left medulla oblongata; brainstem	DXMS; IVIG, AZA; HDMP, later MMF	RR	6; 2
Fan <i>et al.</i> (2018) [4]							
Case 1	23	M	NMDARE-like episodes; both;	Right cerebral peduncle; left posterior cerebral cortex; extensive cortical lesion	HDMP, orally corticosteroids treatment; IVIG, MMF	RR	24; 20
Case 2	25	M	NMDARE-like episodes	The cortex of right hemisphere.	HDMP, orally corticosteroids treatment	MONO	-
Zhou <i>et al.</i> (2018) [15]	54	M	NMDARE-like episodes	Dorsal brainstem, the brain parenchyma surrounding the third and fourth ventricles	HDMP, IVIG, PRED, RTX	MONO	-
Nagata <i>et al.</i> (2018) [16]	20	F	Both	Frontal cortex, cingulate gyRus	HDMP, IVIG, PE	MONO	-
Rojc <i>et al.</i> (2019) [17]	47	M	MOG-like episodes; NMDARE-like episodes	Left optic nerve; right front parietal white matter	HDMP	RR	18 (1, 1, 1, 2, 4, 8 year)
Ren <i>et al.</i> (2019) [10]							
Case 1	31.5, 27–43	F(2); M(2)	NMDARE-like episodes; MOG-like episodes	Abnormal swelling of the left hippocampus; both right and hippocampal region	HDMP, orally corticosteroids treatment	RR	6.5 (0.5–12 months)
Case 2			NMDARE-like episodes; MOG-like episodes	Callosum and around the ventricle; centrum semiovale; the left optical nerve	HDMP, IVIG, natalizumab infusions (600 mg), MMF; later MMF (500 mg/day)	RR	
Case 3			MOG-like episodes	Extensive intracranial lesions; right cerebellar hemisphere and posterior horn of lateral ventricle	HDMP, orally corticosteroids treatment, MMF; AZA	RR	
Case 4			NMDARE-like episodes; MOG-like episodes	Midbrain, C7-T1/T7-T12 spinal cord plane; right pons and aqueduct of sylvius	HDMP, orally corticosteroids treatment, AZA; later AZA (150 mg/day)	RR	
Aoe <i>et al.</i> (2019) [18]	36	F	NMDARE-like episodes	Frontal lobes; basal ganglia, temporal lobe, cerebellar hemisphere.	HDMP, IVIG	RR	420
Perez <i>et al.</i> (2020) [13]	29	M	Both; MOG-like episodes	Temporal lobe; thalamus, medulla, optic nerve	Oral corticosteroids; PE, later RTX	RR	1
Cherian <i>et al.</i> (2020) [19]	30	M	NMDARE-like episodes	Cingulate gyri, limbic lobe, bilateral pulvinar, brainstem, cerebellar	HDMP, later MMF	MONO	-
Fujimori <i>et al.</i> (2020) [20]	39	M	NMDARE-like episodes	Frontal cortex and cingulate gyrus	IVIG, later PRED	RR	39; 50

AZA, Azathioprine; CTX, cyclophosphamide; DXMS, Dexamethasone; F, female; IVIg, intravenous immunoglobulin; HDMP, high dose methylprednisolone pulse therapy; M, male; MMF, mycophenolate mofetil; MOG, myelin oligodendrocyte glycoprotein; MONO, Monophasic; mo., months; MRI, magnetic resonance imaging; NMDARE, anti-N-methyl-D-aspartate receptor encephalitis; PE, Plasma exchange; PRED, Prednisone; RR, Relapsing remitting; RTX, rituximab.

**Table 3. Summary of demographic, clinical, and MRI Findings of 18 (including our patient) MNOS patients.**

Clinical characteristics	Number of cases	Percentage/%
Gender		
Male	11	61.1
Female	7	38.9
Presenting manifestations		
Seizures	7	38.9
Abnormal mental behavior	11	61.1
Cognitive decline	5	27.8
Speech disorders	4	22.2
Dyskinesia	5	27.8
ON	8	44.4
ABS	7	38.9
Numbness	5	27.8
Disturbance of consciousness	1	5.6
MRI findings		
Optical nerve	3	16.7
Cortical	10	55.6
White matter	8	44.4
Deep gray matter	3	16.7
Brainstem	8	44.4
Cerebellum	5	27.8
Spinal cord	1	5.6
Normal	2	11.1
Immunotherapy		
Steroid	18	100
IVIG	8	44.4
PE	5	27.8
MMF	6	33.3
RTX	3	16.7
AZA	3	16.7
CTX	1	5.6
Natalizumab	1	5.6
Disease course		
RR	13	72.2
MONO	5	27.8

ABS, acute brainstem syndrome; AZA, Azathioprine; CTX, cyclophosphamide; IVIG, intravenous immunoglobulin; MMF, mycophenolate mofetil; MOG, myelin oligodendrocyte glycoprotein; MONO, Monophasic; MRI, magnetic resonance imaging; PE, Plasma exchange; RR, Relapsing remitting; RTX, rituximab.

## 4. Discussion

Myelin oligodendrocyte glycoprotein (MOG) is a glycoprotein, which is expressed explicitly on oligodendrocytes' surface in the CNS at the myelin's outermost layer sheath. MOG participates in myelin adhesion and maintains the myelin sheath of oligodendrocyte microtubules [21]. MOG-Ab can be divided into non-pathogenic antibodies (linear glycoproteins) and pathogenic antibodies (folded glycoproteins). Currently, cell-based assay (CBA) is the most commonly used method for detecting pathogenic MOG-IgG [22]. MOG encephalomyelitis has clinical man-

ifestations of vision loss, walking instability, dizziness, etc. [2]. In 2005, Vitaliani *et al.* [23] first reported anti-NMDAR encephalitis, and later Dalmau *et al.* [24] subsequently confirmed its pathogenic target antigen NMDAR. Anti-NMDA receptor encephalitis (NMDARE) is a kind of autoimmune encephalitis caused by neuron surface antibodies against the NMDA receptor GluN1 subunit. Patients often show abnormal mental behavior, seizures, involuntary movement, consciousness alterations, and autonomic nervous system dysfunction [25].

In recent years, an overlapping syndrome, MNOS, of MOG encephalomyelitis and NMDARE has been clinically identified. In these diseases, both MOG-Ab and NMDAR-Ab are positive. The clinical manifestations of MNOS are atypical, sometimes like MOG encephalomyelitis, sometimes like NMDARE; sometimes both of the characteristic clinical manifestations are present. However, the clinical manifestations of the overlapping syndrome were milder than those of NMDARE alone [12]. Therefore, we need to be vigilant when patients with NMDAR encephalitis develop optic neuritis, myelitis, or other demyelinating diseases inconsistent with autoimmune encephalitis and should be evaluated for serological antibodies associated with demyelinating diseases. Similarly, coexisting immune-mediated encephalitis should be suspected when patients with MOG encephalomyelitis or other demyelinating diseases have atypical symptoms, such as psychosis or seizures.

At present, the mechanism of the simultaneous appearance of these two antibodies is not exact. In our case, the patient was exhausted, and he stayed up late with heavy work pressure before the disease. Furthermore, the patient's first symptom was headache. The pathological mechanism may be as follows. Firstly, the patient may be invaded by the virus (Considering it is not a common virus, no obvious abnormality was observed in the virus spectrum). The Blood-Brain Barrier (BBB) was damaged, and the MOG-Ags of the CNS were exposed and the corresponding antibodies were produced, which led to the aggravation of the BBB damage and the exposure of NMDAR-Ags and the generation of NMDAR-Abs. Secondly, it is worth noting that oligodendrocytes can express NMDA receptors [12], so oligodendrocyte damage associated with MOG antibody disease may lead to secondary damage to NMDA receptors [13]. These hypothesis could explain why our patients were positive for NMDAR-Abs even without tumors, and perhaps why serum NMDAR-Abs were positive before CSF was positive. Castillo-Gómez *et al.* [26] showed that all circulating NMDAR antibodies could cause disease in the presence of increased BBB permeability. Therefore, when the serum NMDAR antibody is positive but CSF is negative, we need to be alert and measure CSF and serum NMDAR antibody again.

Immunotherapy is the primary treatment of patients with MNOS. The first-line treatment mainly includes

steroids, IVIG, and PE. Most MNOS patients responded well to first-line therapy in the acute phase [4]. Previous studies have shown that most patients received High-Dose Methylprednisolone pulse Therapy (HDMT) as a steroid regimen. However, in this case, the patient was treated with dexamethasone 10 mg, and the curative effect was also significant. Therefore, it is possible that these diseases may also be treated with routine doses of hormones rather than high-dose hormonal pulse therapy. However, this case is an isolated case, which will require extensive clinical trials in the future. In addition to first-line treatment, some patients received second-line treatment such as MMF, RTX, AZA, CTX, natalizumab. After the acute phase, some patients relapsed during or after oral prednisolone reduction therapy [10,13]. This was especially the case in patients who did not receive second-line treatment at the time of the first attack. The timing and scheme of starting second-line therapy might be a future research direction.

Prior to the second episode (spontaneous discontinuation of prednisone), the patient fell and fractured his arm. We analyzed whether this fall event might have been related to vertigo, limb weakness, epileptic seizure, or gait instability caused by MNOS recurrence. Of course, it is not excluded that the patient may have accidentally tripped, and this accidental fall resulted in disease recurrence. To reduce the risk of future recurrence, we decided to add mycophenolate mofetil treatment to this patient. According to the literature review [27], the recurrence rate of anti-NMDAR encephalitis was between 4% and 26% [28,29], while the recurrence rate of MOG antibody disease is between 60% and 90% [30–33]. Of the 18 patients in this group, 13 had a recurrence and was closer to the recurrence rate of MOG antibody disease. Therefore, MOG antibodies might play an important role in the recurrence of MNOS. Serum MOG antibody monitoring is essential in future follow-ups. Another study [34] suggested that some patients with anti-NMDAR encephalitis relapse due to concurrent tumors. Therefore, this study will continue tumor screening during the follow-up period.

To sum up, MNOS is still in the exploratory stage. And the mechanism and treatment are not yet perfect. It is hoped that this article can provide some modest help for future expert guidelines or consensus to guide the diagnosis and treatment of MNOS.

## Abbreviations

ADEM, acute disseminated encephalomyelitis; AIE, autoimmune encephalitis; anti-NMDAR-Abs, anti-N-Methyl-D-aspartate receptor antibodies; anti-MOG, anti-myelin oligodendrocyte glycoprotein; AQP4, Aquaporin-4; AZA, azathioprine; BBB, blood-brain barrier; CBA, cell-based assay; CMV, cytomegalovirus; CSF, cerebrospinal fluid; CTX, cyclophosphamide; EB, Epstein-Barr; ELISA, enzyme-linked immunosorbent assay; FLAIR, fluid attenuation inversion recovery; HDMT, high-dose methylpred-

nisolone pulse therapy; HSV, herpes simplex virus; IIFT, indirect immune-fluorescence test; IVIG, intravenous immunoglobulin; MBP, myelin basic protein; MMF, mycophenolate mofetil; MNOS, MOG antibody disease and NMDARE overlapping syndrome; MOG, myelin oligodendrocyte glycoprotein; MOG-Abs, myelin oligodendrocyte glycoprotein-antibodies; MRI, magnetic resonance imaging; MS, multiple sclerosis; NMDAR, N-methyl-D-aspartate receptor; NMDARE, anti-NMDAR encephalitis; NMOSD, neuromyelitis optica spectrum disorder; OCT, optical coherence tomography; PE, plasmapheresis; RTX, rituximab; VEEG, video electroencephalogram; VZV, varicella-zoster virus.

## Author contributions

YL, MW, and JT provided assistance and advice on patient diagnosis and treatment. MW, ZZ, YW, YY and SYB collected relevant literature and data. MW, JT and SYB wrote the paper.

## Ethics approval and consent to participate

The case report was approved by the Ethics Committee of the Second Hospital of Dalian Medical University (No. 2021-064).

## Acknowledgment

We sincerely thank the patient and his family for their invaluable participation and cooperation.

## Funding

This study was supported by grants from the Science and Technology Innovation Foundation of Dalian City (No. 2020JJ26SN054) and United Fund of the Second Hospital of Dalian Medical University and Dalian Institute of Chemical Physics, Chinese Academy of Sciences (No. UF-QN-202002).

## Conflict of interest

The authors declare no conflict of interest.

## References

- [1] O'Connor KC, McLaughlin KA, De Jager PL, Chitnis T, Bettelli E, Xu C, *et al.* Self-antigen tetramers discriminate between myelin autoantibodies to native or denatured protein. *Nature Medicine*. 2007; 13: 211–217.
- [2] Jarius S, Paul F, Aktas O, Asgari N, Dale RC, de Seze J, *et al.* MOG encephalomyelitis: international recommendations on diagnosis and antibody testing. *Journal of Neuroinflammation*. 2018; 15: 134.
- [3] Titulaer MJ, Höftberger R, Iizuka T, Leypoldt F, McCracken L, Cellucci T, *et al.* Overlapping demyelinating syndromes and anti-N-methyl-D-aspartate receptor encephalitis. *Annals of Neurology*. 2014; 75: 411–428.
- [4] Fan S, Xu Y, Ren H, Guan H, Feng F, Gao X, *et al.* Comparison of myelin oligodendrocyte glycoprotein (MOG)-antibody disease and AQP4-IgG-positive neuromyelitis optica spectrum disorder (NMOSD) when they co-exist with anti-NMDA (N-

- methyl-D-aspartate) receptor encephalitis. *Multiple Sclerosis and Related Disorders*. 2018; 20: 144–152.
- [5] Dalmau J. NMDA receptor encephalitis and other antibody-mediated disorders of the synapse. *Neurology*. 2016; 87: 2471–2482.
  - [6] Malviya M, Barman S, Golombek KS, Planagumà J, Manara F, Strutz-Seebohm N, *et al.* NMDAR encephalitis: passive transfer from man to mouse by a recombinant antibody. *Annals of Clinical and Translational Neurology*. 2017; 4: 768–783.
  - [7] Hara M, Martinez-Hernandez E, Arino H, Armangue T, Spatola M, Petit-Pedrol M, *et al.* Clinical and pathogenic significance of IgG, IgA, and IgM antibodies against the NMDA receptor. *Neurology*. 2018; 90: e1386–e1394.
  - [8] Ehrenreich H. Autoantibodies against N-methyl-d-aspartate receptor 1 in health and disease. *Current Opinion in Neurology*. 2018; 31: 306–312.
  - [9] Graus F, Titulaer MJ, Balu R, Benseler S, Bien CG, Cellucci T, *et al.* A clinical approach to diagnosis of autoimmune encephalitis. *Lancet Neurology*. 2016; 15: 391–404.
  - [10] Ren Y, Chen X, He Q, Wang R, Lu W. Co-occurrence of Anti-N-Methyl-D-Aspartate Receptor Encephalitis and Anti-myelin Oligodendrocyte Glycoprotein Inflammatory Demyelinating Diseases: A Clinical Phenomenon to Be Taken Seriously. *Frontiers in Neurology*. 2019; 10: 1271.
  - [11] Zhou L, Zhang Bao J, Li H, Li X, Huang Y, Wang M, *et al.* Cerebral cortical encephalitis followed by recurrent CNS demyelination in a patient with concomitant anti-MOG and anti-NMDA receptor antibodies. *Multiple Sclerosis and Related Disorders*. 2017; 18: 90–92.
  - [12] Titulaer MJ, Höftberger R, Iizuka T, Leypoldt F, McCracken L, Cellucci T, *et al.* Overlapping demyelinating syndromes and anti-N-methyl-D-aspartate receptor encephalitis. *Annals of Neurology*. 2014; 75: 411–428.
  - [13] Pérez CA, Agyei P, Gogia B, Harrison R, Samudralwar R. Overlapping autoimmune syndrome: a case of concomitant anti-NMDAR encephalitis and myelin oligodendrocyte glycoprotein (MOG) antibody disease. *Journal of Neuroimmunology*. 2020; 339: 577124.
  - [14] Kaneko K, Sato DK, Misu TA, Kurosawa K, Nakashima I, Fujihara K, *et al.* Overlapping demyelinating syndromes and anti-N-methyl-D-aspartate receptor encephalitis. *Annals of Neurology*. 2014; 75: 411–428.
  - [15] Zhou J, Tan W, Tan SE, Hu J, Chen Z, Wang K. An unusual case of anti-MOG CNS demyelination with concomitant mild anti-NMDAR encephalitis. *Journal of Neuroimmunology*. 2018; 320: 107–110.
  - [16] Nagata S, Nishimura Y, Mitsuo K. A case of anti-myelin oligodendrocyte glycoprotein (MOG) and anti-N-methyl-D-aspartate (NMDA) receptor antibody-positive encephalitis with optic neuritis. *Rinsho Shinkeigaku*. 2018; 58: 636–641.
  - [17] Rojc B, Podnar B, Graus F. A case of recurrent MOG antibody positive bilateral optic neuritis and anti-NMDAR encephalitis: Different biological evolution of the two associated antibodies. *Journal of Neuroimmunology*. 2019; 328: 86–88.
  - [18] Aoe S, Kokudo Y, Takata T, Kobara H, Yamamoto M, Touge T, *et al.* Repeated anti-N-methyl-D-aspartate receptor encephalitis coexisting with anti-myelin oligodendrocyte glycoprotein antibody-associated diseases: a case report. *Multiple Sclerosis and Related Disorders*. 2019; 35: 182–184.
  - [19] Cherian A, Divya KP, Shetty SC, Kannoth S, Thomas B. Coexistent MOG, NMDAR, CASPR2 antibody positivity: Triumph over the triumvirate. *Multiple Sclerosis and Related Disorders*. 2020; 46: 102468.
  - [20] Fujimori J, Takahashi T, Kaneko K, Atobe Y, Nakashima I. Anti-NMDAR encephalitis may develop concurrently with anti-MOG antibody-associated bilateral medial frontal cerebral cortical encephalitis and relapse with elevated CSF IL-6 and CXCL13. *Multiple Sclerosis and Related Disorders*. 2020; 47: 102611.
  - [21] Mathey E, Breithaupt C, Schubart A, Linington C. Commentary: Sorting the wheat from the chaff: identifying demyelinating components of the myelin oligodendrocyte glycoprotein (MOG)-specific autoantibody repertoire. *European Journal of Immunology*. 2004; 34: 2065–2071.
  - [22] Reindl M, Schanda K, Woodhall M, Tea F, Ramanathan S, Sagen J, *et al.* International multicenter examination of MOG antibody assays. *Neurology Neuroimmunology & Neuroinflammation*. 2020; 7: e674.
  - [23] Vitaliani R, Mason W, Ances B, Zwerdling T, Jiang Z, Dalmau J. Paraneoplastic encephalitis, psychiatric symptoms, and hypoventilation in ovarian teratoma. *Annals of Neurology*. 2005; 58: 594–604.
  - [24] Dalmau J, Tüzün E, Wu H, Masjuan J, Rossi JE, Voloschin A, *et al.* Paraneoplastic anti-N-methyl-D-aspartate receptor encephalitis associated with ovarian teratoma. *Annals of Neurology*. 2007; 61: 25–36.
  - [25] Dalmau J, Gleichman AJ, Hughes EG, Rossi JE, Peng X, Lai M, *et al.* Anti-NMDA-receptor encephalitis: case series and analysis of the effects of antibodies. *Lancet Neurology*. 2008; 7: 1091–1098.
  - [26] Castillo-Gómez E, Oliveira B, Tapken D, Bertrand S, Klein-Schmidt C, Pan H, *et al.* All naturally occurring autoantibodies against the NMDA receptor subunit NR1 have pathogenic potential irrespective of epitope and immunoglobulin class. *Molecular Psychiatry*. 2017; 22: 1776–1784.
  - [27] Gong S, Zhang W H, Ren H T, Li J W, Zhou J, Cheng H, *et al.* Clinical observation on the overlapping syndrome of myelin oligodendrocyte glycoprotein antibody and anti-N-methyl-D aspartate receptor in children. *Zhonghua Er Ke Za Zhi*. 2020; 58: 581–585. (In Chinese)
  - [28] Xu X, Lu Q, Huang Y, Fan S, Zhou L, Yuan J, *et al.* Anti-NMDAR encephalitis. *Neurology Neuroimmunology & Neuroinflammation*. 2020; 7: e633.
  - [29] Gabilondo I, Saiz A, Galán L, González V, Jadraque R, Sabater L, *et al.* Analysis of relapses in anti-NMDAR encephalitis. *Neurology*. 2011; 77: 996–999.
  - [30] Jarius S, Ruprecht K, Kleiter I, Borisow N, Asgari N, Pitarokoili K, *et al.* MOG-IgG in NMO and related disorders: a multicenter study of 50 patients. Part 1: Frequency, syndrome specificity, influence of disease activity, long-term course, association with AQP4-IgG, and origin. *Journal of Neuroinflammation*. 2016; 13: 279.
  - [31] Jarius S, Ruprecht K, Kleiter I, Borisow N, Asgari N, Pitarokoili K, *et al.* MOG-IgG in NMO and related disorders: a multicenter study of 50 patients. Part 2: Epidemiology, clinical presentation, radiological and laboratory features, treatment responses, and long-term outcome. *Journal of Neuroinflammation*. 2016; 13: 280.
  - [32] Jarius S, Kleiter I, Ruprecht K, Asgari N, Pitarokoili K, Borisow N, *et al.* MOG-IgG in NMO and related disorders: a multicenter study of 50 patients. Part 3: Brainstem involvement - frequency, presentation and outcome. *Journal of Neuroinflammation*. 2016; 13: 281.
  - [33] Pache F, Zimmermann H, Mikolajczak J, Schumacher S, Lacheta A, Oertel FC, *et al.* MOG-IgG in NMO and related disorders: a multicenter study of 50 patients. Part 4: Afferent visual system damage after optic neuritis in MOG-IgG-seropositive versus AQP4-IgG-seropositive patients. *Journal of Neuroinflammation*. 2016; 13: 282.
  - [34] Zheng J, Shen J, Wang A, Liu L, Xiong J, Li X, *et al.* Clinical characteristics of anti-N-methyl-D-aspartate receptor encephalitis in children. *Zhong Nan Da Xue Xue Bao Yi Xue Ban*. 2020; 45: 47–54. (In Chinese)