

Multiple Intracerebral Arteriovenous Malformations

A Case Report and Literature Review

Kesava Reddy, M.D., Michael West, M.D., Ph.D., F.R.C.S.(C), and
Blake McClarty, M.D., F.R.C.P.(C)

Section of Neurosurgery and Department of Radiology, University of Manitoba, Winnipeg, Manitoba, Canada

Reddy K, West M, McClarty B. Multiple intracerebral arteriovenous malformations. A case report and literature review. *Surg Neurol* 1987;27:495-9.

The presence of multiple intracerebral arteriovenous malformations (AVMs) in a single patient has only been very rarely reported. We present a patient with three separate angiographically demonstrable intracerebral AVMs, all of which were radiologically demonstrated and surgically removed without residual neurological deficit. A literature survey was conducted and all the previously described cases of multiple intracerebral AVMs are discussed, along with the potential diagnostic and therapeutic implications.

KEY WORDS: Cerebral; Multiple; Arteriovenous malformations; Angiography; Surgery

Arteriovenous malformations (AVMs) have been best defined simply as "congenital arteriovenous fistulous malformations" [39]. Numerous publications have highlighted the clinical presentation [12,30,39,53], natural history [13,14,17,33,42,50], and various treatment modalities [8,10,12,13,29,30,46,49,53]. Multiple intracerebral AVMs in a single patient are extremely uncommon, apart from those occurring in the setting of hereditary hemorrhagic telangiectasia. We present a single case of a young girl with three separate intracranial AVMs successfully operated on after radiographic demonstration. The relevant literature regarding multiple intracerebral AVMs is reviewed.

Case Report

A previously healthy 16-year-old girl was admitted to the Neurosurgical Service at St. Boniface General Hospital on May 31, 1982 after being found unconscious at

home. She had bitten her tongue and had been incontinent of urine, and was presumed to have suffered a grand mal seizure. In the hospital she had an episode of loss of contact with surroundings with tonic eye deviation to the left, unaccompanied by clonic movements. The history obtained at the time of admission revealed nonspecific bifrontal headaches in an intelligent high school student with a good scholastic background. Relevant family history included a possible pulmonary AVM (unconfirmed) in one of the patient's maternal aunts. On admission her blood pressure was 110/70 and pulse was regular at 64 per minute. A general physical examination showed no abnormalities, specifically no angiomatous malformations. The neurological examination, including fundi and visual fields, was normal and there was no neck stiffness. No cranial bruits were found on auscultation. A contrast infused computed tomography (CT) scan of the head showed two areas of irregular enhancement; in the right frontal and the right parietal regions (Figure 1). Transfemoral pan-cerebral angiography was performed and three separate AVMs were demonstrated, one each in the right frontal, right temporal, and left posterior parieto-occipital regions (Figures 2 and 3). The right frontal lesion was filled with branches from the right middle cerebral and right anterior cerebral arteries. It drained predominantly to the superior sagittal sinus via two venous channels. The right temporal lesion was supplied predominantly by the right middle cerebral artery, and drained into the superior sagittal sinus by a large vein. A smaller venous varix was also found to be draining the lesion, heading towards the right orbit. The left parieto-occipital AVM was filled with the parietal branches of the left middle cerebral artery and drained predominantly by a single vein into the straight sinus. The largest of the lesions, the right frontal AVM, was totally excised on the 10th day after presentation. The right temporal and left parietal lesions were also totally excised at 1 week intervals consequently. Postoperative angiography after the second craniotomy showed no residual right-sided malformations (Figures 4 and 5). The only complication was an episode

Address reprint requests to: Dr. K. Reddy, S1 Medical Services Building, 750 Bannatyne Avenue, Winnipeg, Manitoba, R3E 0W2, Canada.

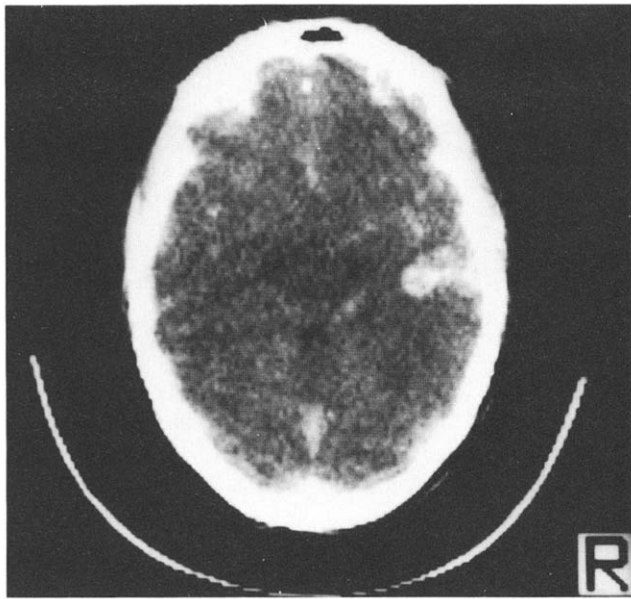


Figure 1. CT scan of patient on admission, showing right frontal and parietal enhancement.

of transient dysphasia which followed the left-sided craniotomy. When contacted recently (2.5 years following surgery), the patient was without deficit and in excellent health.

Discussion

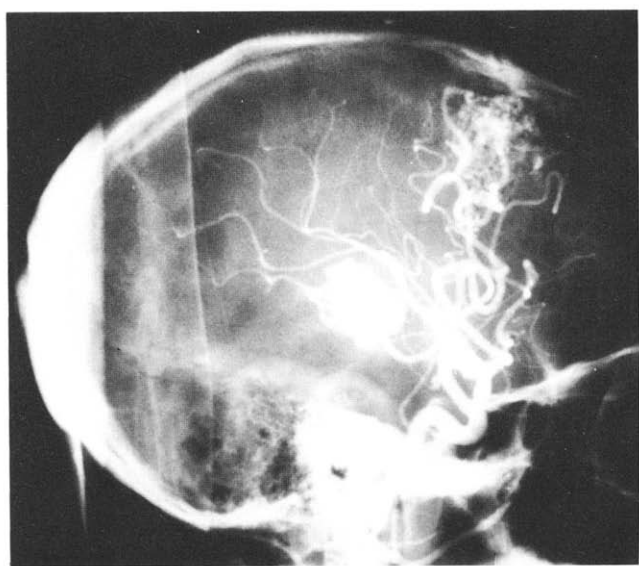
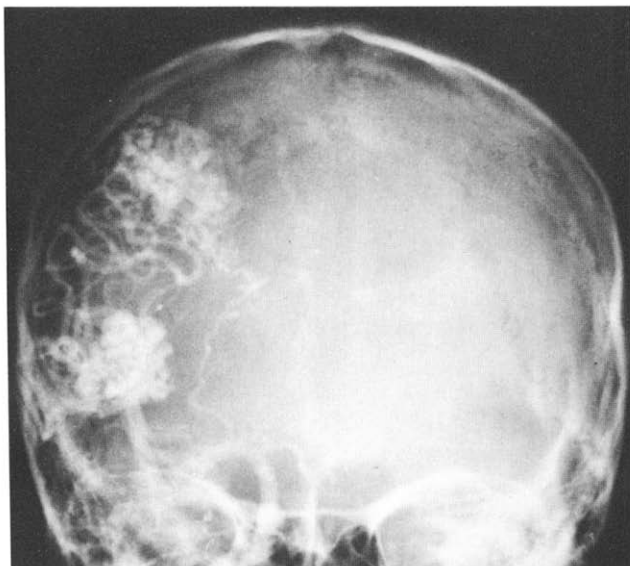Cranial AVMs have been estimated to be present in 0.14% of the population and the incidence has been said to be one-seventh that of intracranial aneurysms

[33]. The pathogenesis of AVMs is somewhat unclear but they have been thought to represent persistent embryonic arteriovenous connections [27,38,54]. The cumulative rebleed rate for intracranial AVMs has been reported to be approximately 2%–3% per year [17], though Fults and Kelly [14] quote a higher figure of 17.9% for the first 5 years. The incidence of seizures as the presenting feature has varied from 10% to 28% in various adult series [12,14,17,42], whereas in pediatric series the incidence has varied from 15% to 40% [2,15,35,48].

There has been no uniformity in the classification of these lesions [5]. Pathologically angiomatous malformations of the brain have been classified as follows: telangiectasia, venous and capillary angiomas, and AVMs [5,44]. Clinicians tend to name all the angiographically demonstrable vascular anomalies as "AVMs," and they have been subdivided on the basis of size, the "small" lesions being less than 2 cm in diameter [18]. Many large series of AVMs have not made any mention of multiplicity among intracranial AVMs [12,13,18,31,37,39,53]. Many large pediatric series have also not reported on multiplicity among intracranial AVMs [2,15,35,48].

The association of AVMs with single and multiple intracranial aneurysms is well known [4,37,41]. Nine percent of all AVMs have been said to be associated with aneurysms. Aneurysms have been found on the feeding vessels to an AVM as well as on other vessels [9,21,42] and have been postulated to be due to hemodynamic stress [12,21]. Association of an aneurysm with multiple AVMs has also been reported [47]. The as-

Figure 2. Anteroposterior (left) and lateral (right) angiograms following a selective right carotid artery injection showing the right frontal and right parietal AVMs.



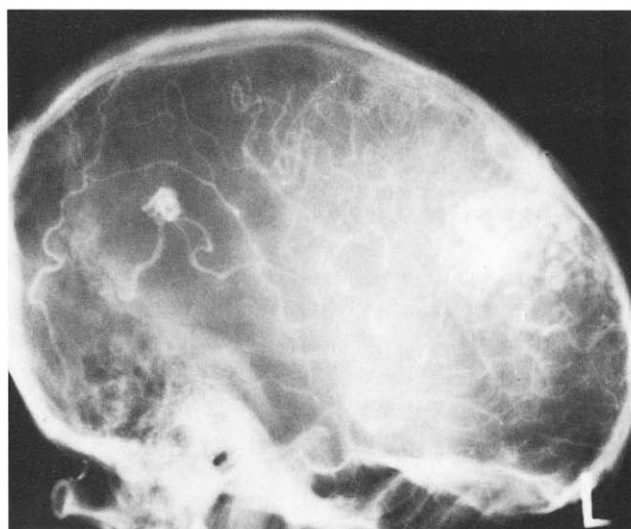
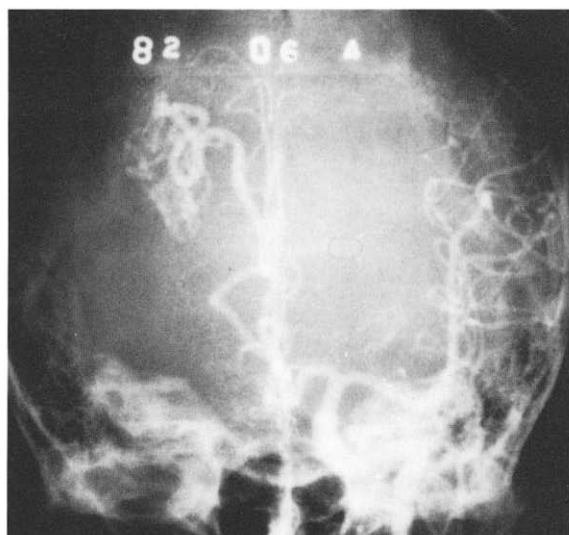
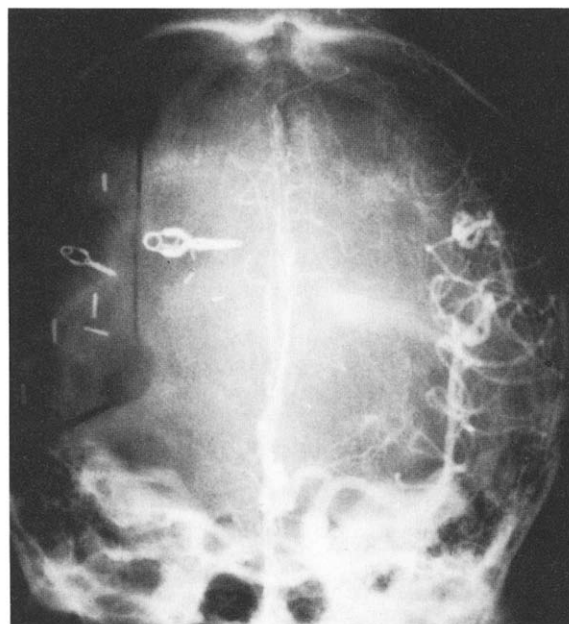


Figure 3. Anteroposterior (left) and lateral (right) angiograms following a selective left carotid artery injection showing the right frontal AVM being filled by the left anterior cerebral artery. The smaller left parietal AVM is also shown.

sociation of spinal AVMs with cerebral AVMs has been reported in adults [11,20,40] and in a child [24]. Multiple intracranial AVMs associated with similar lesions elsewhere in the body have been described in the setting of hereditary telangiectasia, especially Osler-Weber-Rendu syndrome [1,6,22,23,32,36,43,52], though the more common intracranial lesion in this syndrome is a capillary telangiectasia [22]. A case with multiple intracranial dural AVMs with spontaneous resolution has recently been reported [28].

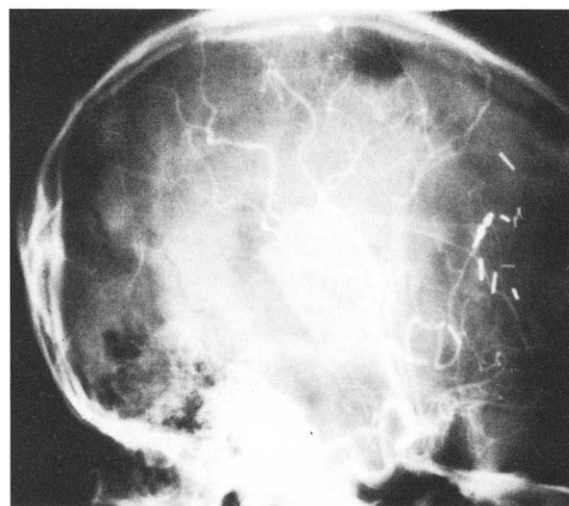
Figure 4. Anteroposterior left carotid artery angiogram showing the postoperative absence of filling of the right frontal AVM (Figure 2).



Multiple intracerebral AVMs have been mentioned, without further qualification, in some of the larger series [34,41,42,50] and postmortem cases of multiple capillary telangiectasia and cavernous angiomas are not uncommon [5,7,25,26]. Tamaki [51] reported a case of multiple AVMs treated by radiotherapy. A possible case of multiple intracranial AVMs in an infant has been reported [3].

Hanieh et al [19] reported a case with two separate cerebral AVMs that presented as intracerebral hematomas but were not angiographically demonstrable. Schlacter et al [45] reported a series of four cases with possible multiple AVMs. Of their cases, case 2 could

Figure 5. Lateral right carotid artery angiogram showing the postoperative absence of filling of right frontal and parietal AVMs.



well have been a single lesion [16]. In a recent publication Zellem and Buchst [55] demonstrated three discrete, small AVMs in a patient with hereditary hemorrhagic telangiectasia. The present case represents one of the few with multiple, discrete, angiographically demonstrated AVMs, with no definitive family history or clinical features of hereditary hemorrhagic telangiectasia.

In the management of patients with subarachnoid hemorrhage, as clearly documented in the case of ruptured aneurysms, the territories of all four intracranial vessels must be satisfactorily demonstrated so that multiple vascular anomalies are not missed, even in the absence of stigmata of hereditary telangiectasia. In this case all the cerebral lesions were well demonstrated and completely excised, with no permanent neurological disability.

Conclusions

Multiple intracerebral AVMs are extremely uncommon, especially in the absence of family history or stigmata of hereditary hemorrhagic telangiectasia. Four vessel angiography is absolutely essential to rule out multiple lesions in the evaluation of a patient for possible aneurysms or AVMs. In the absence of radiologic pointers, the decision regarding which lesion to operate on first is difficult to resolve. Currently, the best way to manage surgically accessible lesions is by surgical excision, with a possible adjunctive role for interventional neuroradiology.

Note added in proof: After this paper was accepted, the patient's brother sought medical attention for headaches, and was noted to have stigmata of Rendu-Osler-Weber syndrome, which was confirmed by genetic investigation of the whole family.

The authors wish to thank Ms. D. Breckon, Ms. P. Frank, and Ms. D. Henry for their help in the preparation of this manuscript.

References

1. Adams HP, Subbiah B, Bosch E. Neurologic aspects of hereditary hemorrhagic telangiectasia. *Arch Neurol* 1977;34:101-4.
2. Amacher AL, Drake CG, Hovind L. The results of operating upon cerebral aneurysms and angiomas in children and adolescents. II. Cerebral angiomas. *Child's Brain* 1979;5:166-73.
3. Arai H, Sugiyama Y, Kawakami S, et al. Multiple intracranial aneurysms and vascular malformations in an infant. *J Neurosurg* 1972;37:357-60.
4. Batjer H, Suss RA, Samson D. Intracranial arteriovenous malformations associated with aneurysms. *Neurosurgery* 1986;18:29-35.
5. Bebin J, Smith EE. Vascular malformations of the brain. In: Smith RR, Haerer AF, Russell WF, eds *Vascular malformations and fistulas of the brain*. New York: Raven, 1982:13-29.
6. Bird RM, Jacques WE. Vascular lesions of hereditary hemorrhagic telangiectasia. *N Engl J Med* 1959;260:597-9.
7. Bugiani O. Multiple strokes due to multiple vascular malformations of the brain. *Eur Neurol* 1984;23:206-10.
8. Cromwell LD, Harris AB. Treatment of cerebral AVM's—a combined neurosurgical and neuroradiological approach. *J Neurosurg* 1980;52:705-8.
9. Cronqvist S, Troupp H. Intracranial AVM's and arterial aneurysms in the subarachnoid hemorrhage patients. *Acta Neurol Scand* 1966;42:307-16.
10. Debrun G, Vinuela F, Fox A, et al. Embolization of cerebral AVM's with bucrylate—experience in 46 cases. *J Neurosurg* 1982;56:615-27.
11. Dichiro G. Combined retino cerebellar angiomas and deep cervical angioma. *J Neurosurg* 1957;14:685-7.
12. Drake CG. Cerebral AVM's—considerations for and experience with surgical treatment in 166 cases. *Clin Neurosurg* 1979;26:145-208.
13. Forster DM, Steiner L, Hakanson S. Arteriovenous malformations of the brain—a long term clinical study. *J Neurosurg* 1972;37:562-70.
14. Fults D, Kelly DL. Natural history of AVM's of the brain—a clinical study. *Neurosurgery* 1984;15:658-62.
15. Gerossa MA, Cappellotto P, Licata C. Cerebral AVM's in children. *Child's Brain* 1981;8:306-71.
16. Golden JB. Letter. *Neurosurgery* 1980;7:444.
17. Graf CJ, Perret GE, Turner JC. Bleeding from cerebral AVM's as part of their natural history. *J Neurosurg* 1983;58:331-7.
18. Guidetti B, Delitala A. Intracranial AVM's—conservative and surgical treatment. *J Neurosurg* 1980;53:149-52.
19. Hanieh A, Blumberg PC, Carney PC. Multiple cerebral AVM's associated with soft tissue vascular malformations. *J Neurosurg* 1981;54:670-2.
20. Hash CJ, Grossman CB, Shenkin HA. Concurrent intracranial and spinal cord arteriovenous malformations, case report. *J Neurosurg* 1975;43:104-7.
21. Hayashi S, Arimoto T, Itakura T, et al. The association of intracranial aneurysms and AVMs of the brain. *J Neurosurg* 55:971-5.
22. Heffner RR, Solitaire GB. Hereditary hemorrhagic telangiectasia—neuropathologic observations. *J Neurol Neurosurg Psychiatry* 1969;32:604-8.
23. Hodgson CH, Burchell HB, Good C, et al. Hereditary hemorrhagic telangiectasia and pulmonary AV fistula. *N Engl J Med* 1959;261:625-36.
24. Hoffman HJ, Mohr G, Kusunoki T. Multiple arteriovenous malformations of spinal cord and brain in a child. *Child's Brain* 1976;2:317-24.
25. Hosoi K. Multiple intracranial angiomas. *Am J Pathol* 1930;6:235-43.
26. Jellinger K. The morphology of centrally situated angioma. In: Pia HW, Gleave JRW, Grove E, et al, eds. *Cerebral angiomas, advances in diagnosis and therapy*. Berlin, Heidelberg, New York: Springer-Verlag, 1975:16-7.
27. Kaplan HA, Aronson S, Browder EJ, et al. Vascular malformations of the brain, an anatomical study. *J Neurosurg* 1961;18:630-5.
28. Kataoka K, Taneda M. Angiographic disappearance of multiple dural AVM's. *J Neurosurg* 1984;60:1275-8.
29. Kjelberg RN, Hanamura T, Davis RK, et al. Bragg peak proton beam therapy for arteriovenous malformations of the brain. *N Engl J Med* 1983;309:269-74.
30. Malis LI. Arteriovenous malformations of the brain. In: Youmans JR, ed. *Neurological surgery*, vol. 3, 2nd ed. Philadelphia: WB Saunders, 1982:1786-803.

31. McCormick. The pathology of vascular (arteriovenous) malformations. *J Neurosurg* 1966;24:807-16.
32. Michael JC, Levin PM. Multiple telangiectases of the brain. *Arch Neurol Psychiatry* 514-29.
33. Michelsen WJ. Natural history and pathophysiology of arteriovenous malformations. *Clin Neurosurg* 1979;26:307-13.
34. Moody RA, Poppen JL. Arteriovenous malformations. *J Neurosurg* 1970;32:503-11.
35. Mori K, Murata T, Hashimoto N, et al. Critical analysis of AVM's in children. *Child's Brain* 1980;6:13-25.
36. Nunn DB, Garten L. Pulmonary AV fistulae with hereditary hemorrhagic telangiectasia with carotid aneurysm. *J Cardiovasc Surg* 1980;21:99-104.
37. Olivecrona H, Riives J. Arteriovenous aneurysms of the brain, their diagnosis and treatment. *Arch Neurol Psychiatry* 1948;59:567-602.
38. Padget D. The cranial venous system in man in reference to development, adult configuration and relation to the arteries. *Am J Anat* 1958;98:307-55.
39. Parkinson D, Bachers G. Arteriovenous malformations: summary of 100 consecutive supratentorial cases. *J Neurosurg* 1980;53:285-99.
40. Parkinson D, West M. Spontaneous subarachnoid hemorrhage from an intracranial and then a spinal AVM—a case report. *J Neurosurg* 1977;47:965-68.
41. Paterson JH, McKissock W. A clinical survey of intracranial angiomas with special reference to their mode of progression and surgical treatment: a report of 110 cases. *Brain* 1956;79:233-66.
42. Perrin G, Nishioka H. Report on the cooperative study of intracranial aneurysm and subarachnoid hemorrhage—AVM's. *J Neurosurg* 1966;25:467-90.
43. Reagan TJ, Bloom WH. The brain in hereditary hemorrhagic telangiectasia. *Stroke* 1971;2:361-8.
44. Rubenstein LJ. Tumors of the nervous system. *AFIP Fascicle* 1976;6:241-56.
45. Schlacter LB, Fleisher AS, Faria MA Jr, et al. Multifocal intracranial AVM's. *Neurosurgery* 1980;95:440-1.
46. Serbinenko FA. Balloon catheterization and occlusion of major cerebral vessels. *J Neurosurg* 1974;41:125-44.
47. Shigemori M, Kunitada H, Shirahama M, et al. Multiple vascular malformations of the brain associated with a cerebral aneurysm. *Neurol Med Chir* 1982;22:383-8.
48. So SC. Cerebral AVM's in children. *Child's Brain* 1978;4:242-50.
49. Stein BM, Wolpert SM. AVM of the brain. Current concepts and treatment. *Arch Neurology* 1980;37:1-5, 69-75.
50. Svien HJ, McRae JA. Arteriovenous anomalies of the brain. *J Neurosurg* 1965;23:23-8.
51. Tamaki N, Fugita K, Yamashita H. Multiple AVM's involving the scalp, dura, retina, cerebellum and posterior fossa. *J Neurosurg* 1971;34:95.
52. Waller JD, Greenberg JH, Lewis W. Hereditary hemorrhagic telangiectasia with cerebrovascular malformations. *Arch Dermatol* 1976; 112:49-52.
53. Wilson CB, Sang H, Domingue J. Microsurgical treatment of intracranial vascular malformations. *J Neurosurg* 1979;51:446-54.
54. Wyburn-Mason R. Arteriovenous aneurysm of mid brain and retina, facial naevi and mental changes. *Brain* 1943;66:12-203.
55. Zellem RJ, Buchest WA. Multiple intracranial AVM's. Case report. *Neurosurgery* 1985;17:88-93.