

# Moyamoya Syndrome in a Patient with Williams Syndrome: A Case Report

Taisuke Akimoto<sup>a,b</sup> Jun Suenaga<sup>b</sup> Tomoko Hayashi<sup>a</sup> Daisuke Hirokawa<sup>a</sup>  
Susumu Ito<sup>a</sup> Hironobu Sato<sup>a</sup> Tetsuya Yamamoto<sup>b</sup>

<sup>a</sup>Department of Neurosurgery, Kanagawa Children's Medical Center, Yokohama, Japan; <sup>b</sup>Department of Neurosurgery, Yokohama City University, Yokohama, Japan

## Established Facts

- Moyamoya syndrome associated with Williams syndrome is very rare.
- The prognoses of moyamoya syndrome with Williams syndrome cases were severe.
- *RNF213* c.14576G>A is known to be significantly associated with definite moyamoya disease.

## Novel Insights

- This was the first reported case of a Williams syndrome with moyamoya syndrome that was confirmed by the presence of an *RNF213* mutation.
- In moyamoya syndrome associated with Williams syndrome, adequate perioperative management of both the moyamoya arteries and the cardiovascular abnormalities is important to prevent complications.

## Keywords

Williams syndrome · Moyamoya syndrome · Moyamoya gene · *RNF213*

## Abstract

**Introduction:** Moyamoya syndrome associated with Williams syndrome is very rare but has been reported to have severe outcomes. Here, we reported a case of Williams syndrome with moyamoya syndrome that was confirmed by the presence of an *RNF213* mutation. **Case Presentation:** A 6-year-old boy with Williams syndrome presented with right hemiparesis induced by hyperventilation. Magnetic reso-

nance angiography and cerebral angiography showed severe stenosis of the bilateral internal carotid arteries and development of moyamoya vessels. Genetic analysis identified a heterozygous c.14576G>A (p.R4859K) mutation in *RNF213*. Moyamoya syndrome was diagnosed, and bilateral indirect revascularization surgery was conducted without complications and with a good postoperative course. In moyamoya syndrome associated with Williams syndrome, adequate perioperative management of both the moyamoya arteries and the cardiovascular abnormalities is important to prevent complications. **Conclusion:** This was the first report on a case in which moyamoya syndrome associated with Williams syndrome was confirmed by the presence of a heterozygous

*RNF213* mutation. Similar to the workup of moyamoya disease, confirmation of *RNF213* mutation in Williams syndrome may be useful in predicting the development of moyamoya syndrome that can lead to severe complications.

© 2022 The Author(s).  
Published by S. Karger AG, Basel

## Introduction

Williams syndrome is a genetic disorder characterized by cardiovascular problems, such as supravalvular aortic and pulmonary artery stenoses, mental retardation, and an elfin face. The disorder is caused by deletions of multiple contiguous genes, including the *ELN* gene, that code for the protein elastin, on the long arm of chromosome 7 [1, 2]. Because elastin is related within the formation of blood vessels, lack of the protein causes the circulatory system abnormalities of this syndrome.

Moyamoya syndrome in patients with Williams syndrome is very rare; in fact, a PubMed search uncovered only a few reports on such association [3, 4], and the prognoses of these cases were severe [3, 4]. Moreover, there was only one extremely rare case of indirect revascularization for Williams syndrome and moyamoya disease. In this present report, we showed the case of a 6-year-old boy with Williams syndrome associated with moyamoya syndrome that was confirmed by the presence of a c.14576G>A (p.R4859K) mutation in *RNF213* and was successfully treated with cerebral revascularization surgery. In Williams syndrome, both the cardiovascular and cerebrovascular complications are major causes of death; therefore, evaluation of the moyamoya syndrome by magnetic resonance imaging or the presence of an *RNF213* mutation, in addition to the cardiac function, may be necessary.

## Case Report

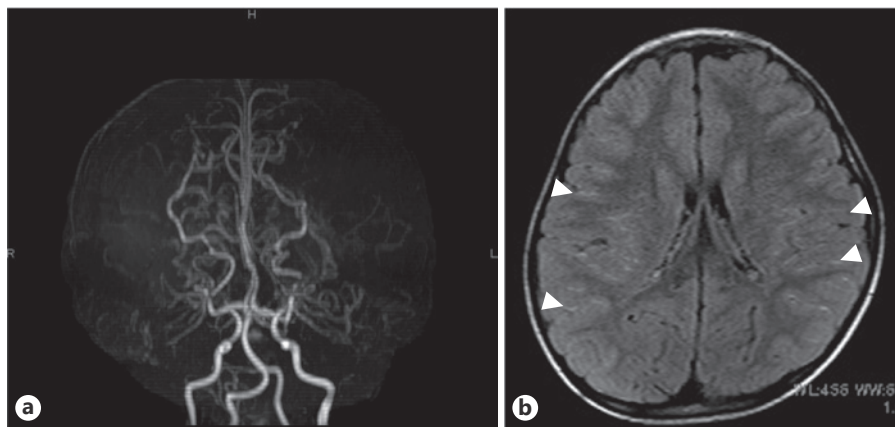
### History and Examination

The patient presented at the age of 6 years with right hemiparesis induced by hyperventilation. In addition to transient right hemiparesis, he sometimes cried while his head was being held, suggesting headache. At the age of 2 years, he had been diagnosed with Williams syndrome, which was confirmed by the deletion of 7q11.23 on fluorescence in-situ hybridization. There was no history of trauma or any preceding infection, such as varicella-zoster. The patient had no history of moyamoya disease.

Although he had mild pulmonary artery bifurcation stenosis (i.e., about 2 m/s on both sides with pressure difference 10–15 mm Hg), the echocardiography results showed normal cardiac function, as follows: left ventricular internal dimension in diastole of 28 mm, fractional shortening of 40%, ejection fraction of 70%, and no supravalvular aortic stenosis. Specialists from the cardiology department assessed and anticipated no problems during angiography or surgery. Magnetic resonance angiography (MRA) showed severe stenosis of the bilateral internal carotid arteries, and the fluid-attenuated inversion recovery image demonstrated the ivy sign bilaterally (Fig. 1). Likewise, cerebral angiography showed severe stenosis, especially in the proximal portions of the bilateral middle cerebral arteries, as well as development of moyamoya vessels (Fig. 2). The presence of bilateral stenosis of the internal carotid arteries without obvious dissecting vessels on MRA and cerebral angiography ruled out focal cerebral arteriopathy, based on its new classification, and was consistent with moyamoya syndrome, which we classified as Suzuki stage III [5, 6].

### Operative and Postoperative Course

The patient underwent left-sided indirect cerebral revascularization surgery using superficial temporal artery, temporal muscle, and periosteum tissues from a donor. Two months after the first operation, there was left hemiparesis induced by crying. Therefore, we performed the same procedure on the right side. In both perioperative periods, normocapnia, normotension, and adequate hematocrit level were strictly maintained, in addition to pain control with fentanyl and dehydrobenzperidol. After the second operation, the patient recovered well and had no cerebral ischemic event. Postoperative MRA demonstrated collateral vessels from the bilateral superficial and deep temporal arteries and reduced number of moyamoya vessels (Fig. 3). Moreover, the postoperative



**Fig. 1.** **a** MRA shows stenosis of the bilateral internal carotid arteries. **b** FLAIR image demonstrates the ivy sign bilaterally (arrowheads). FLAIR, fluid-attenuated inversion recovery.

fluid-attenuated inversion recovery images showed resolution of the bilateral ivy sign (Fig. 3). Five years after the operation, he had no hemiparesis or ischemic events.

#### Genetic Study

DNA analysis showed a p.Arg4810Lys mutation in the ring finger protein (RNF) 213 c.14429G>A (Fig. 4). We extracted gDNA samples from the blood and analyzed the genome sequence by pyrosequencing. An *RNF213* NM\_001256071.1 c.14429G>A pArg4810Lys heterozygous mutation was found in exon 60 of *RNF213*. A mutation, in which the arginine at the 4,810th position was replaced with a lysine, was observed by changing the base from G to A at the 14,429th position. The mutation was registered in the dbSNP database as rs112735431.

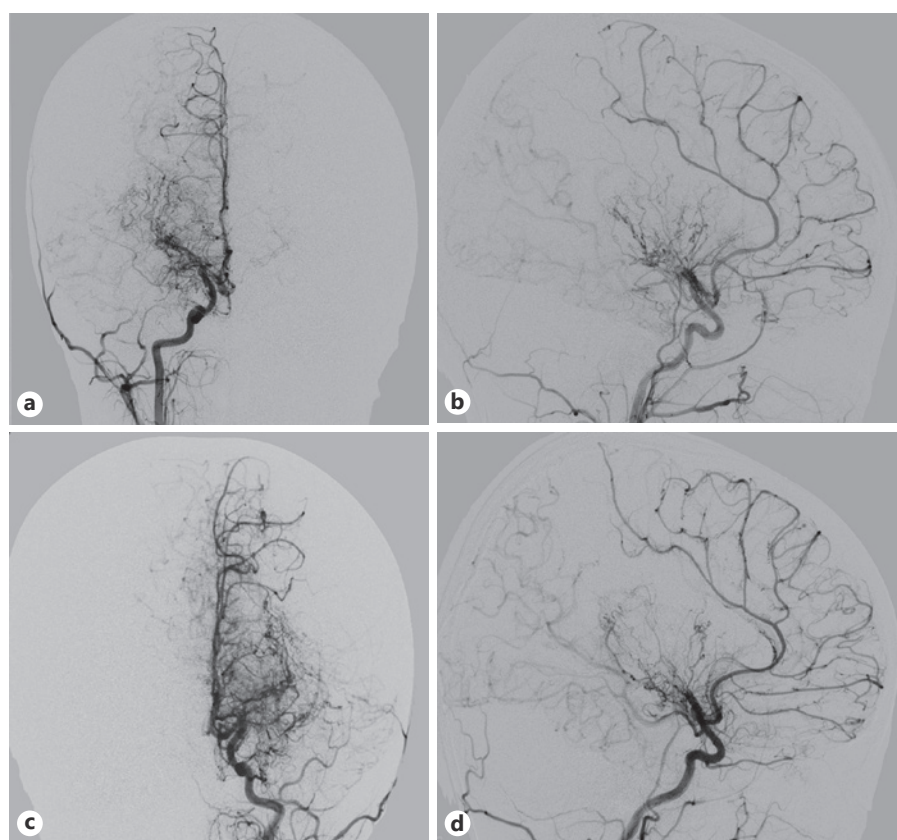
#### Discussion

Williams syndrome is causative of moyamoya syndrome, but only 2 cases have been reported so far [3, 4]; in both cases, the disease was fatal. One case was that of an 18-year-old patient with Williams syndrome and died of intracerebral hemorrhage secondary to moyamoya syndrome, based on autopsy [3]. The other case was that of a 9-year-old boy from who unexpectedly developed

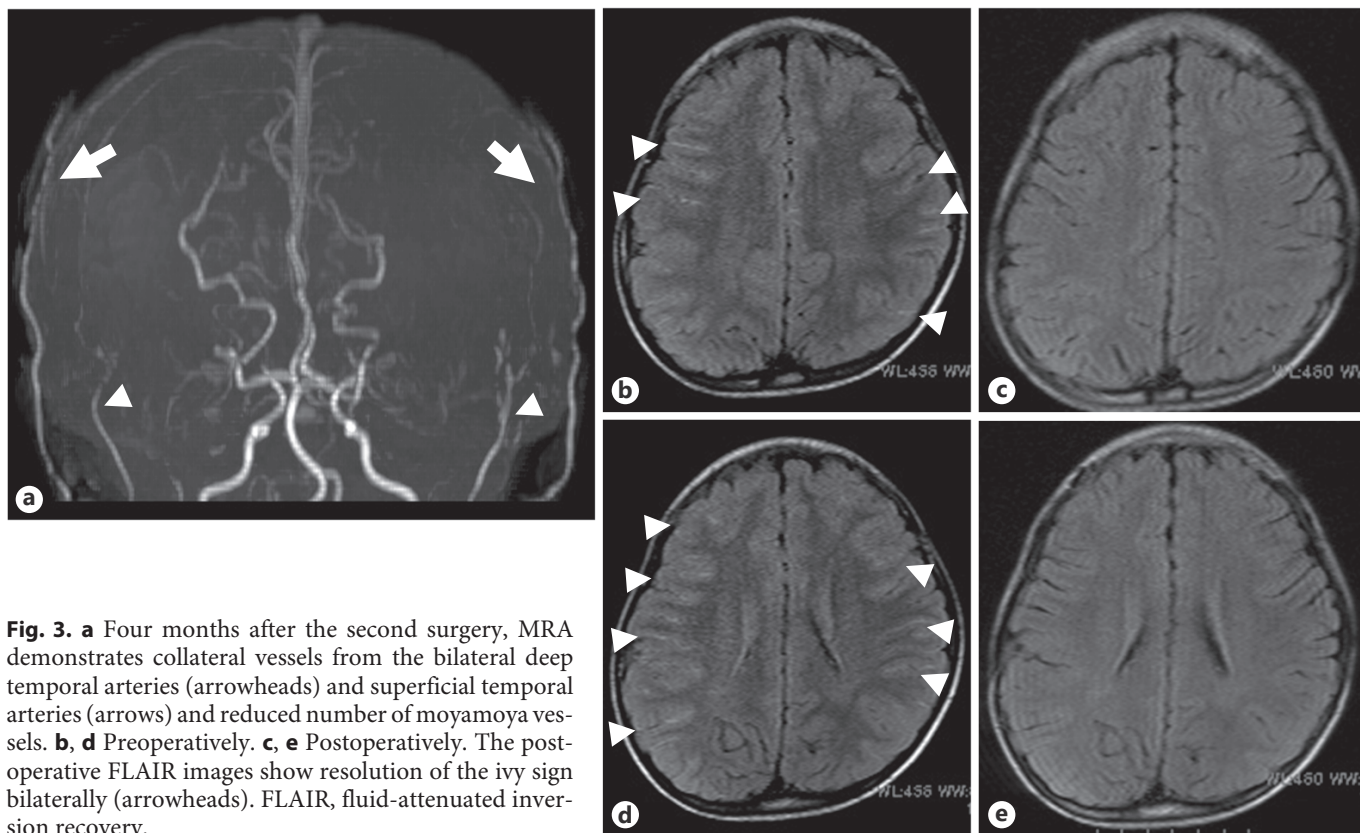
global cerebral infarction after revascularization surgery for moyamoya disease, which led to brain death [4]. In that case from Korea, the patient's pupils dilated suddenly on the third postoperative day and diffuse hypodense areas in the bilateral cerebral hemispheres were seen on brain computed tomography 1 h after. Two months before his operation, the patient had undergone a second surgery for coarctation of the aorta.

The reports that we found on such cases had poor prognosis; therefore, we were concerned that this would be a high-risk operation. In Williams syndrome, cardiovascular problems and cerebrovascular complications are the major cause of death. In fact, the risk of sudden death was 25–100 times greater than that for an age-matched normal population [7]. Decreased cardiac output, myocardial ischemia, and arrhythmias are the presumed mechanisms of death. In this present case, the patient only had mild pulmonary stenosis in the cardiovascular system, which fortunately allowed us to perform indirect revascularization surgery.

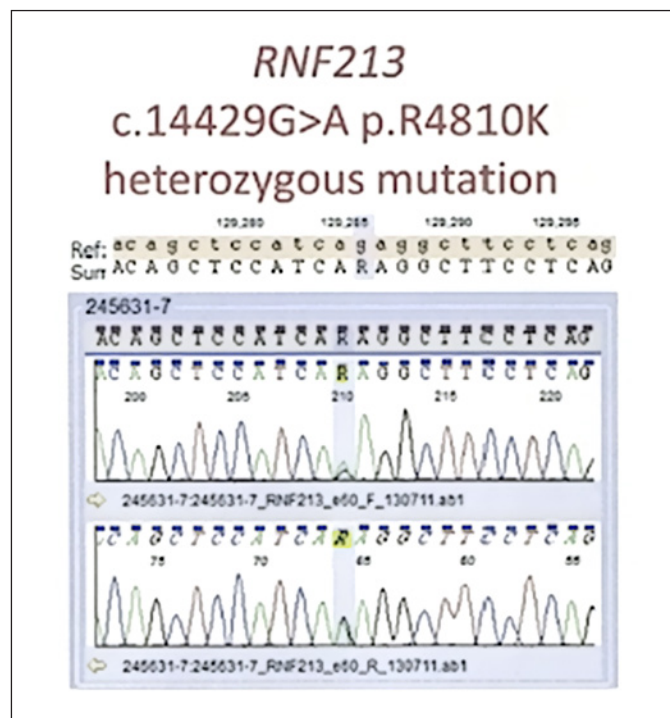
Moyamoya syndrome refers to a condition in which a stenosis or occlusion is found in the terminal portion of the internal carotid artery, anterior cerebral artery, and



**Fig. 2.** Common carotid angiography findings. Right frontal (a) and lateral (b) views and left frontal (c) and lateral (d) views show severe stenosis, especially in the proximal portions of the bilateral middle cerebral arteries, and development of moyamoya vessels. On the basis of these findings, we classified the moyamoya syndrome as Suzuki Stage III [19].



**Fig. 3.** **a** Four months after the second surgery, MRA demonstrates collateral vessels from the bilateral deep temporal arteries (arrowheads) and superficial temporal arteries (arrows) and reduced number of moyamoya vessels. **b, d** Preoperatively. **c, e** Postoperatively. The postoperative FLAIR images show resolution of the ivy sign bilaterally (arrowheads). FLAIR, fluid-attenuated inversion recovery.



**Fig. 4.** Schematic result of the pyrosequencing of *RNF213* A p.Arg4810Lys mutation in the *RNF213* c.14429G>A is observed.

proximal portion of the middle cerebral artery. It is accompanied by an abnormal vascular network, which is similar to the findings in definite moyamoya disease, but moyamoya syndrome has an underlying genetic or autoimmune disease [8]. The treatment for moyamoya syndrome is similar to that of definite moyamoya disease. For moyamoya syndrome associated with Recklinghausen's disease, Down syndrome, or irradiation, direct and indirect revascularization has been demonstrated to be effective [9–11]. However, owing to the few number of reports, the value and efficacy of revascularization for Williams syndrome were unclear. In patients with moyamoya syndrome, unilateral involvement may progress to bilateral disease [12], and the nature of the underlying disease influences the prognosis [13]. This present case was a symptomatic and bilaterally progressive moyamoya syndrome associated with Williams syndrome, and indirect revascularization surgery could be done without complication.

*RNF213* c.14576G>A is known to be significantly associated with definite moyamoya disease. The variant is involved in vascular development and in the function of vascular endothelial cells [14–16]. Although its exact function is unknown, the presence of *RNF213* c.14576G>A may act as a pathologic condition that triggers the athero-

genic development of the end of the internal carotid artery in definite moyamoya disease. On the other hand, in moyamoya syndrome, various baseline diseases could trigger the pathologic condition. For example, the *RNF213* variant might be a risk factor for development of moyamoya syndrome in NF-1 populations [17]; however, this association is weaker compared with the robust contributions of the *RNF213* c.14576G>A variant to sporadic/familial moyamoya disease [17]. In patients with Down Syndrome, reports have shown a relatively early age of onset (i.e., 2 years) of moyamoya syndrome, owing to the presence of the *RNF213* variant. This finding suggested that the Down syndrome and *RNF213* variants contribute to the development of moyamoya vasculopathy [18]. In a study on Japanese patients with moyamoya disease, homozygous individuals had relatively early onset and severe presentation [19]. Therefore, the disease severity is possibly related with a combination of the number and type of variants present, as well as with other modifiers affected by genetic/environmental factors [19, 20].

Based on this report, we suggest that the *RNF213* c.14576G>A mutation may be a modifier of the phenotypic features of Williams syndrome. More clinical data are needed to further elucidate the frequency and importance of the *RNF213* mutation in Williams syndrome, especially in patients with intracranial artery anomalies and moyamoya vessels. Williams syndrome is associated with a high incidence of sudden death and risk of intracranial vascular stenosis (i.e., moyamoya syndrome); therefore, intracranial arterial evaluation and the presence of the *RNF213* gene mutation should be noted.

## Conclusion

We reported a rare case of moyamoya syndrome in a patient with Williams syndrome that was successfully treated with indirect revascularization with superficial temporal artery, temporal muscle, and periosteum tissues. In Williams syndrome, cardiovascular problems (such as obstructive left-heart lesions and/or coronary artery stenosis) and cerebrovascular complications are a major cause of death. Confirming the presence of *RNF213* mutations may be necessary in cases of Williams syndrome.

## Acknowledgments

We thank Flaminia Miyamasu of the Medical English Communications Center, University of Tsukuba, for manuscript editing.

## Statement of Ethics

The authors affirm that the parents of the patient gave written informed consent for publication of data and images. Ethical approval was not required for this study in accordance with national guidelines.

## Conflict of Interest Statement

All authors have no conflict of interest.

## Funding Sources

The authors did not receive any funding for this study.

## Author Contributions

Taisuke Akimoto and Jun Suenaga conceptualized and designed the study, drafted the initial manuscript, and reviewed and revised the manuscript. Taisuke Akimoto drafted the manuscript, analyzed the data, and reviewed the literature. Taisuke Akimoto, Jun Suenaga, Tomoko Hayashi, Daisuke Hirokawa, Susumu Ito, Hironobu Sato, and Tetsuya Yamamoto critically reviewed the manuscript, approved the final manuscript to be submitted, and agreed to be accountable for all aspects of the work.

## Data Availability Statement

All data generated or analyzed during this study are included in this article. Further inquiries can be directed to the corresponding author.

## References

- 1 Schubert C. The genomic basis of the Williams-Beuren syndrome. *Cell Mol Life Sci.* 2009;66(7):1178–97.
- 2 Kaplan P, Wang PP, Francke U. Williams (Williams Beuren) syndrome: a distinct neurobehavioral disorder. *J Child Neurol.* 2001; 16(3):177–90.
- 3 Kawai M, Nishikawa T, Tanaka M, Ando A, Kasajima T, Higa T, et al. An autopsied case of Williams syndrome complicated by moyamoya disease. *Acta Paediatr Jpn.* 1993;35(1): 63–7.
- 4 Sim YW, Lee MS, Kim YG, Kim DH. Unpredictable postoperative global cerebral infarction in the patient of williams syndrome accompanying moyamoya disease. *J Korean Neurosurg Soc.* 2011;50(3):256–9.
- 5 Suzuki J, Takaku A. Cerebrovascular “moyamoya” disease. Disease showing abnormal net-like vessels in base of brain. *Arch Neurol.* 1969;20(3):288–99.

- 6 Wintermark M, Hills NK, DeVeber GA, Barkovich AJ, Bernard TJ, Friedman NR, et al. Clinical and imaging characteristics of arteriopathy subtypes in children with arterial ischemic stroke: results of the VIPS study. *AJNR Am J Neuroradiol*. 2017;38(11):2172–9.
- 7 Wessel A, Gravenhorst V, Buchhorn R, Gosch A, Partsch CJ, Pankau R. Risk of sudden death in the Williams-Beuren syndrome. *Am J Med Genet A*. 2004;127A(3):234–7.
- 8 Research Committee on the Pathology and Treatment of Spontaneous Occlusion of the Circle of Willis; Health Labour Sciences Research Grant for Research on Measures for Intractable Diseases. Guidelines for diagnosis and treatment of moyamoya disease (spontaneous occlusion of the circle of willis). *Neurol Med Chir*. 2012;52(5):245–66.
- 9 Ishikawa T, Houkin K, Yoshimoto T, Abe H. Vasoreconstructive surgery for radiation-induced vasculopathy in childhood. *Surg Neurol*. 1997;48(6):620–6.
- 10 Jea A, Smith ER, Robertson R, Scott RM. Moyamoya syndrome associated with Down syndrome: outcome after surgical revascularization. *Pediatrics*. 2005;116(5):e694–701.
- 11 Scott RM, Smith JL, Robertson RL, Madsen JR, Soriano SG, Rockoff MA. Long-term outcome in children with moyamoya syndrome after cranial revascularization by pial synangiosis. *J Neurosurg*. 2004;100(2 Suppl Pediatrics):142–9.
- 12 Kelly ME, Bell-Stephens TE, Marks MP, Do HM, Steinberg GK. Progression of unilateral moyamoya disease: a clinical series. *Cerebrovasc Dis*. 2006;22(2–3):109–15.
- 13 Kestle JR, Hoffman HJ, Mock AR. Moyamoya phenomenon after radiation for optic glioma. *J Neurosurg*. 1993;79(1):32–5.
- 14 Hitomi T, Habu T, Kobayashi H, Okuda H, Harada KH, Osafune K, et al. Downregulation of Securin by the variant RNF213 R4810K (rs112735431, G>A) reduces angiogenic activity of induced pluripotent stem cell-derived vascular endothelial cells from moyamoya patients. *Biochem Biophys Res Commun*. 2013;438(1):13–9.
- 15 Hitomi T, Habu T, Kobayashi H, Okuda H, Harada KH, Osafune K, et al. The moyamoya disease susceptibility variant RNF213 R4810K (rs112735431) induces genomic instability by mitotic abnormality. *Biochem Biophys Res Commun*. 2013;439(4):419–26.
- 16 Liu W, Morito D, Takashima S, Mineharu Y, Kobayashi H, Hitomi T, et al. Identification of RNF213 as a susceptibility gene for moyamoya disease and its possible role in vascular development. *PLoS One*. 2011;6(7):e22542.
- 17 Phi JH, Choi JW, Seong MW, Kim T, Moon YJ, Lee J, et al. Association between moyamoya syndrome and the RNF213 c.14576G>A variant in patients with neurofibromatosis Type 1. *J Neurosurg Pediatr*. 2016;17(6):717–22.
- 18 Chong PF, Ogata R, Kobayashi H, Koizumi A, Kira R. Early onset of moyamoya syndrome in a Down syndrome patient with the genetic variant RNF213 p.R4810K. *Brain Dev*. 2015;37(8):822–4.
- 19 Miyatake S, Miyake N, Touho H, Nishimura-Tadaki A, Kondo Y, Okada I, et al. Homozygous c.14576G>A variant of RNF213 predicts early-onset and severe form of moyamoya disease. *Neurology*. 2012;78(11):803–10.
- 20 Nanba R, Kuroda S, Tada M, Ishikawa T, Houkin K, Iwasaki Y. Clinical features of familial moyamoya disease. *Childs Nerv Syst*. 2006;22(3):258–62.