

## Short report

# Necrotising haemorrhagic encephalomyelopathy in an adult: ? Leigh's disease

G DELGADO,\* J GÁLLEGO,\* TERESA TUÑÓN,† J J ZARRANZ,‡  
J A VILLANUEVA\*

From Servicios de Neurología,\* Anatomía Patológica,† Hospital de Navarra, Pamplona. Cátedra de Neurología, Universidad del País Vasco,‡ Bilbao, Spain

**SUMMARY** A 21 year old male, well-nourished and non-alcoholic, died after five weeks illness. He had suffered epileptic fits, bilateral internuclear ophthalmoplegia, bulbar and pontine paralysis, tetraparesia, ataxia and dystonia. A CT brain scan showed low density lesions of the striatum bilaterally. Post-mortem studies revealed pathological anomalies compatible with Leigh's disease, although the presence of haemorrhages and involvement of the mamillary bodies could also suggest Wernicke's encephalopathy.

Leigh's disease is unusual in the adult. Eighteen cases with pathological verification have been published.<sup>1-11</sup> It is even questionable whether some of the cases, such as patient 2 of Feigin and Goebel,<sup>1</sup> patient 1 of Kalimo *et al*<sup>6</sup> and all those of Feigin and Budzilovich<sup>5</sup> were really suffering from Leigh's disease. Among the cases with a reasonably certain diagnosis, the symptoms began in adult life in only five,<sup>2,3,6,10,11</sup> so that the remaining cases may be juvenile forms with prolonged survival.<sup>10</sup> We present the clinical, radiological and pathological study of a patient with Leigh's disease in whom the five weeks course of the disease took place in adult life.

### Case report

The patient was a 21 year old male, neither alcoholic nor undernourished, the third of the healthy children of non-consanguineous parents. He was admitted to hospital because of a progressive illness of three weeks duration, consisting of epileptic fits, diplopia, dysarthria, dysphagia and weakness of the left limbs. Neurological examination revealed pale optic discs, bilateral internuclear ophthalmoplegia, dysarthria, bilateral facial, lingual and palatopharyngeal paresis, and motor deficit (4/5) of all four limbs, more pronounced on the left. Tendon jerks were brisk, the cutaneo-abdominal reflexes were present and Babinski's sign was elicited bilaterally. There was hypotonia, ataxia and

action dystonia of distal distribution in all four limbs. Repeated blood tests for copper, ceruloplasmin, aminoacids, pH, lactate and pyruvate levels were normal. An electroretinogram showed reduced amplitude and very prolonged latencies. Cortical somatosensory evoked potentials and motor and sensory nerve conduction velocities were normal. A CT brain scan and a right carotid angiogram were normal. The only abnormality found in the CSF was a protein content of 7 g/l. Repeated subsequent CT scans revealed bilateral low density of the caudate nucleus, putamen and thalamus, with no enhancement (fig 1). The level of consciousness gradually deteriorated until he was in coma, showing a slight reaction to pain. The pupils were fixed and medium in size. Oculocephalic, oculovestibular and corneal reflexes were abolished. Tendon jerks, cutaneo-abdominal and plantar reflexes also disappeared. Respiration became irregular. The patient died of cardiorespiratory failure two weeks after admission. He was treated with phenobarbitone (150 mg/day) and i.v. thiamine (1200 mg/day).

The necropsy was carried out immediately after death. No macroscopic or microscopic abnormalities were found outside the nervous system. The brain weighed 1530 g. Macroscopically, there was bilateral uncinatate herniation, more pronounced on the left side. The cortex presented diffuse haemorrhages of patchy distribution. There were bilateral necrotic cavities in the caudate nucleus and putamen (fig 2). The thalamic nuclei were dark gray. Haemorrhages were observed around the aqueduct of Sylvius, below the floor of the fourth ventricle and in some cerebellar folia. Microscopically, there were diffuse lesions in the cerebral cortex with spongiosis, proliferation of fine-walled capillaries and recent perivascular haemorrhages (fig 3a). The neurons were mostly preserved; only a few were shrunken and pycnotic. In the hippocampus, the cortex showed neuronal loss and gliosis.

Address for reprint requests: Dr G Delgado, Servicio de Neurología, Hospital de Navarra, c/ Irunlarrea s/n Pamplona, Spain.

Received 22 November 1985 and in revised form 16 June 1986.  
Accepted 23 June 1986

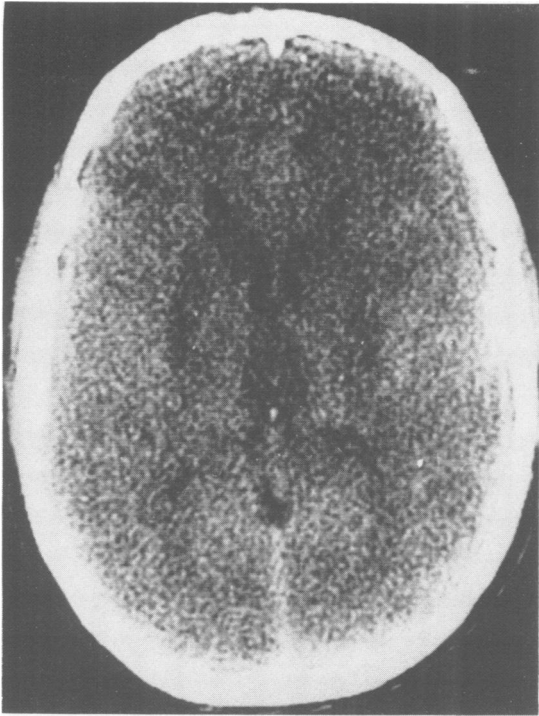


Fig 1 CT brain scan showing symmetrical areas of low density in the putamen, caudate nucleus and thalamus.

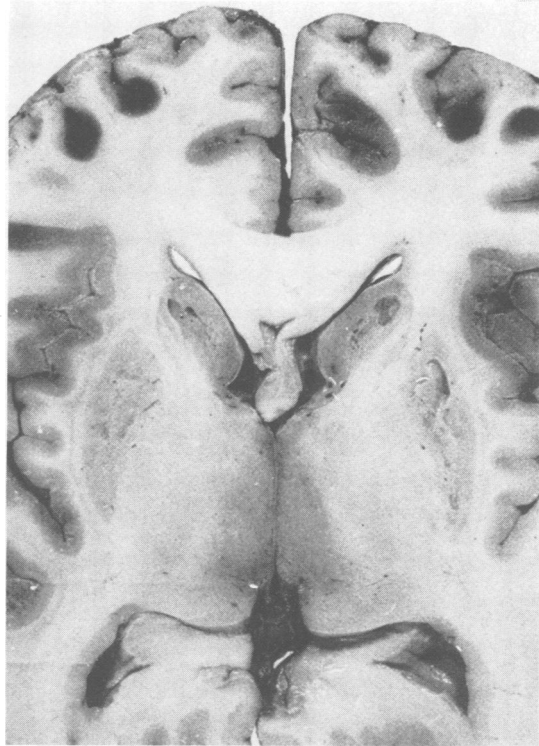

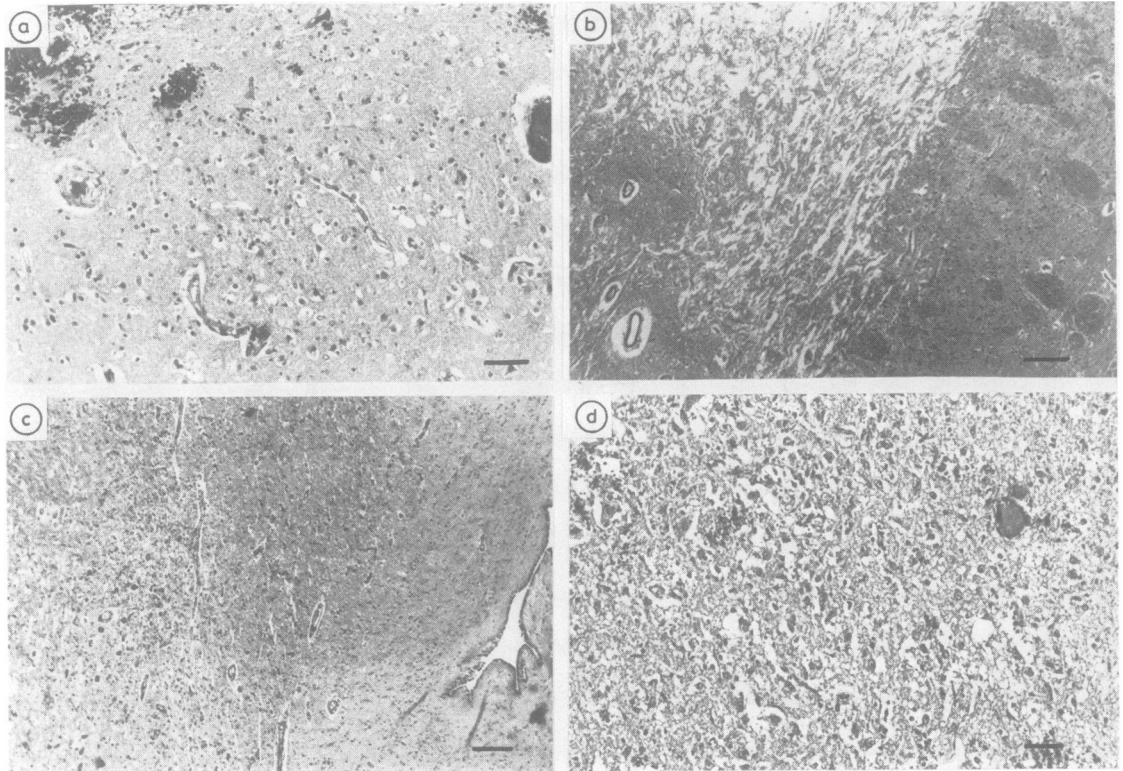
Fig 2 Transverse section of the encephalon at the level of the geniculate bodies. Parahippocampal herniation on the left side (right side of image), bilateral necrosis with cavitations of the head of the caudate nucleus and putamen and cortical haemorrhages can be seen.

sis. In the putamen, globus pallidus, and caudate nucleus, necrotic areas were seen (fig 3b), with numerous macrophages, astrocytic gliosis, spongiosis and capillary proliferation. Outside the necrotic areas, the neurons were relatively preserved. Similar changes, without necrosis, were present in the thalamus, hypothalamic nuclei, periaqueductal gray matter (fig 3c), substantia nigra, dorsal nucleus of the vagus and hypoglossal nucleus. The mammillary bodies showed severe spongiosis, vascular proliferation, shrunken neurons, some macrophages containing iron and preservation of the peripheral white matter (fig 3d). The cerebral white matter appeared moderately pale, with the nerve fibres undamaged. Haemorrhagic necrosis and vascular proliferation were present in some cerebellar folia. The cerebellar white matter and deep gray nuclei were normal. The spinal cord showed microhaemorrhages, vascular proliferation and spongiosis with preserved neurons, in the anterior and intermedio-lateral horns. The lateral and posterior columns were normal. Most of the optic nerve fibres were demyelinated. The sural nerve and the sympathetic ganglia were normal. In the skeletal muscle, there were signs of acute denervation of moderate intensity, with no mitochondrial abnormalities found in the electron microscope study.

## Discussion

The clinical picture was that of a multifocal encephalomyelopathy. The findings on the CT scan made one

suspect the presence of Leigh's disease because of the similarity to the abnormalities seen in infantile and juvenile forms of the disease.<sup>12 13</sup> We excluded other entities in which low density of the striatum has also been reported, such as Wilson's disease,<sup>14-16</sup> anoxic, ischaemic and toxic encephalopathies,<sup>17-22</sup> hypoglycaemia,<sup>23 24</sup> wasp stings,<sup>25 26</sup> and bilateral striatal necrosis of unknown cause in children.<sup>27</sup> As far as we know, only three adult patients with pathologically proven Leigh's disease have been studied by means of CT brain scan.<sup>7 10 11</sup> Whetsell and Plaitakis<sup>7</sup> mention the existence of "edema of the mid-brain" in one of the three cases. In the case of Gray *et al*<sup>10</sup> symmetrical areas of low density were observed in both thalami and anterior limbs of internal capsules; these and the splenium of the corpus callosum were enhanced after iv contrast. The case of Masó *et al*<sup>11</sup> showed "enlargement of the fourth ventricle and atrophy of the cerebellum". Bilateral thalamic low density has also been noted in infantile and juvenile forms of Leigh's disease,<sup>28</sup> in viral encephalitis<sup>29</sup> and exceptionally in Wernicke's encephalopathy.<sup>30 31</sup>



**Fig 3** (a) Cerebral cortex. Recent microhaemorrhages, spongiosis and moderate vascular proliferation can be seen. Haematoxylin & eosin; bar = 310  $\mu$ m. (b) Necrotic cavity in the left putamen. Haematoxylin & eosin; bar = 1 cm. (c) Periaqueductal gray matter. Note necrosis, vascular proliferation and preserved neurons. Haematoxylin & eosin; bar = 1200  $\mu$ m. (d) Mammillary body lesion showing spongiosis, haemorrhages and numerous preserved neurons. Haematoxylin & eosin; bar = 310  $\mu$ m.

The distinction between the adult form of Leigh's disease and Wernicke's encephalopathy is based fundamentally on the topography of the lesions, which morphologically are very similar. Denis Leigh, in his initial description of the subacute necrotising encephalomyelopathy, considered the diagnostic possibility of a Wernicke's encephalopathy in an infant.<sup>32</sup> In the present case, neuropathological findings are compatible with both diagnoses. The involvement of the optic nerves, gray matter of the spinal cord, substantia nigra, the necrotic cavitation of the striatum and the severe bulbar and pontine lesions, are more suggestive of Leigh's disease than of Wernicke's encephalopathy.<sup>33 34</sup> The presence of haemorrhages and the lesion of the mammillary bodies are traditionally considered to be typical of Wernicke's encephalopathy.<sup>34</sup> Diffuse lesions of the cerebral cortex, as in the present case, have been noted in eight infantile and juvenile cases of Leigh's disease.<sup>35</sup> In our case we did not find abnormalities of the muscle mitochondria as described by Eggar and Pincott.<sup>35</sup> Despite the pres-

ence of haemorrhages and the lesion of the mammillary bodies, the whole of neuropathological findings, in absence of alcoholism and malnutrition is more suggestive of Leigh's disease than of Wernicke's encephalopathy. Moreover, bilateral low density of the striatum has never been reported in Wernicke's encephalopathy. To our knowledge only two cases of Wernicke's encephalopathy have been reported with CT scan abnormalities other than alcoholic cerebral atrophy.<sup>30 31</sup> In these two cases, low density, both periaqueductal and on either side of the third ventricle was observed, with normal density of the striatum.

The study of this case suggests that the topography of the lesions is not an absolute nosological criterion of differentiation between adult Leigh's disease and Wernicke's encephalopathy. The demonstration of disorders of pyruvate and thiamine metabolisms or of the respiratory chain<sup>7 36</sup> may be necessary to elucidate the diagnostic dilemma.

We thank Dr José Obeso for helpful suggestions.

## References

- 1 Feigin I, Goebel HH. "Infantile" subacute necrotizing encephalopathy in the adult. *Neurology* 1969;19:749-59.
- 2 Solheid C, Stoupe N, Martin JJ. La forme adulte à évolution chronique de l'encephalopathie nécrasante de Leigh. Sa situation vis à vis des formes infantile-juvéniles. *Acta Neurol Belg* 1971;71:282-95.
- 3 Martin JJ. Sur la délimitation clinicopathologique de l'encephalopathie de Gayet-Wernicke et de la forme adulte d'encephalopathie de Leigh. *Acta Neurol Belg* 1972;72:347-54.
- 4 Sipe JC. Leigh's syndrome: The adult form of subacute necrotizing encephalomyelopathy with predilection for the brainstem. *Neurology* 1973;23:1030-8.
- 5 Feigin I, Budzilovich GN. Further observations on subacute necrotizing encephalomyelopathy in adults. *J Neuropathol Exp Neurol* 1977;36:128-39.
- 6 Ulrich J, Fankhauser-Mauri C. Subacute necrotizing (Leigh) in an adult. *Eur Neurol* 1978;17:241-6.
- 7 Whetsell WO Jr, Plaitakis A. Leigh's disease in an adult with evidence of "inhibitor factor" in family members. *Ann Neurol* 1978;3:519-24.
- 8 Kalimo H, Lundberg PO, Olsson Y. Familial subacute necrotizing encephalomyelopathy of the adult form (adult Leigh syndrome). *Ann Neurol* 1979;6:200-6.
- 9 Kepes JJ. Oncocytic transformation of choroid plexus epithelium. *Acta Neuropathol* 1983;62:145-8.
- 10 Gray F, Louarn F, Gherardi R, Eizenbaum JF, Marsault C. Adult form of Leigh's disease: a clinicopathological case with CT scan examination. *J Neurol Neurosurg Psychiatry* 1984;47:1211-5.
- 11 Masó E, Ferrer I, Herraiz J, Roquer J, Serrano S. Leigh's disease in an adult. *J Neurol* 1984;231:253-7.
- 12 Hall K, Gardner-Medwin D. CT scan appearances in Leigh's disease. *Neuroradiology* 1978;16:48-50.
- 13 Giroud M, Dumas R. La maladie de Leigh. Ses aspects cliniques, biochimiques, histologiques et tomodensitométriques. *Rev Pediat* 1982;28:395-8.
- 14 Nelson RF, Guzman DA, Grahovac Z, Howse DCN. Computerized cranial tomography in Wilson disease. *Neurology* 1979;29:866-8.
- 15 Kendall BG, Pollock SS, Bass NM, Valentine AR. Wilson's disease. Clinical correlation with cranial computed tomography. *Neuroradiology* 1981;22:1-5.
- 16 Williams FGB, Walshe JM. Wilson's disease: An analysis of the cranial computerized appearances found in 60 patients and the changes in response to treatment with chelating agents. *Brain* 1981;104:735-52.
- 17 Kjos BO, Brandt Zawadzki M, Young RG. Early CT findings of global central nervous system hypoperfusion. *AJNR* 1983;4:1043-8.
- 18 Kim KS, Weinberg PE, Suh JH, Ho SU. Acute carbon monoxide poisoning: Computed tomography of the brain. *AJNR* 1980;1:399-402.
- 19 McLean DR, Jacobs H, Niekke BW. Methanol poisoning. A clinical and pathological study. *Ann Neurol* 1980;8:161-7.
- 20 Matsuo F, Cumings JW, Anderson RE. Neurological sequelae of massive hydrogen sulphide inhalation. *Arch Neurol* 1979;36:452-3.
- 21 Finelli PF. Case report: Changes in the basal ganglia following cyanide poisoning. *J Comput Assist Tomogr* 1981;5:755-6.
- 22 Maier W. Cerebral computed tomography of ethylene glycol intoxication. *Neuroradiology* 1983;24:175-7.
- 23 Richardson ML, Kinard RE, Gray MB. CT of generalized gray matter infarction due to hypoglycemia. *AJNR* 1981;2:366-7.
- 24 Kaiser MC, Pettersson H, Harwood-Nash DC, Fitz CR, Chuang S. Case report: Computed tomography of the brain in severe hypoglycemia. *J Comput Assist Tomogr* 1981;5:757-9.
- 25 Laplane D, Widlocher D, Pillon B, Baulac M, Binoux F. Comportement compulsif d'allure obsessionnelle par necrose circonscrite bilatérale pallido-striatal. *Rev Neurol (Paris)* 1981;137:269-76.
- 26 Laplane D, Baulac M, Pillon B, Panayotopoulon-Achimastos I. Perte de l'autoactivation psychique. Activité compulsive d'allure obsessionnelle. Lésion lenticulaire bilatérale. *Rev Neurol (Paris)* 1982;138:137-41.
- 27 Goutieres F, Aicardi J. Acute neurological dysfunction associated with destructive lesions of the basal ganglia in children. *Ann Neurol* 1982;12:328-32.
- 28 Schwartz WJ, Hutchinson HT, Berg BO. Computerized tomography in subacute necrotizing encephalomyelopathy (Leigh disease). *Ann Neurol* 1981;10:268-71.
- 29 Marcu H, Hacker H, Vonfakos D. Bilateral reversible thalamic lesions on computed tomography. *Neuroradiology* 1979;18:201-4.
- 30 Mensing JWA, Hoogland PH, Sloof JL. Computed tomography in the diagnosis of Wernicke's encephalopathy: A radiological-neuropathological correlation. *Ann Neurol* 1984;16:363-5.
- 31 Kosaka K, Aoki M, Kawasaki N, Adachi Y, Konuma I, Iizuka R. A non-alcoholic Japanese patient with Wernicke's encephalopathy and Marchiafava-Bignami disease. *Clin Neuropathol* 1984;3:231-6.
- 32 Leigh D. Subacute necrotizing encephalomyelopathy in an infant. *J Neurol Neurosurg Psychiatry* 1951;14:216-21.
- 33 Monpetit VJA, Andermann F, Carpenter S, Fawcett JS, Zborowskasluis D, Giberson HR. Subacute necrotizing encephalomyelopathy. A review and a study of two families. *Brain* 1971;94:1-30.
- 34 Duchon LW, Jakobs JM. Nutritional deficiencies and metabolic disorders. In: Hume Adams J, Corsellis JAN, eds. *Greenfield's Neuropathology*. London: Edward Arnold 1984:573-626.
- 35 Egger J, Pincott JR. Cortical subacute necrotizing encephalomyelopathy. A study of two patients with mitochondrial dysfunction. *Neuropediatrics* 1984;15:150-8.
- 36 Van Erven PMM, Gabreëls FJM, Ruitenbeek W, Den Hartog MR, Fisher JC, Renier WO, Trijbels JMF, Sloof JL, Janssen AJM. Subacute necrotizing encephalomyelopathy (Leigh syndrome) associated with disturbed oxidation of pyruvate, malate and 2-oxoglutarate in muscle and liver. *Acta Neurol Scand* 1985;72:36-42.