

Brain lesions associated with eosinophilia. A useful clue for neurotoxocariasis. Report of one case

ALBERTO FICA^{1,2}, MARÍA ISABEL JERCIC³, CLAUDIO NAVARRETE^{4,5}

ABSTRACT

*Neurotoxocariasis is uncommon. Its manifestations include events of meningitis, encephalitis and less frequently vasculitis, which manifest as headache, seizures, focalization, confusion, cognitive alterations and /or fever. Peripheral eosinophilia with clinical and neurological imaging elements, allow its early suspicion. We report a 48-year-old agricultural worker, admitted in our hospital for one week of gastrointestinal complaints, headache, progressive left hemiparesis and impaired consciousness. He had leukocytosis (13,530/ μ L) with peripheral eosinophilia (25%, absolute count 3,400 / μ L). CSF analysis revealed no abnormalities and brain CT showed poorly defined hypodense lesions on subcortical areas and semioval centers. Magnetic resonance imaging showed multiple foci with increased signals predominantly in the white matter in both hemispheres, especially at frontal and occipital regions and at semioval centers. Lesions reinforced after paramagnetic contrast. Serological studies found specific IgG antibodies by ELISA against antigens of the genus *Toxocara*, which were confirmed by a positive IgG Western Blot. The patient was treated with albendazole (800 mg/d) for 14 days associated with parenteral and then oral corticosteroids with a favorable response and gradual complete recovery.*
(Rev Med Chile 2021; 149: 1673-1678)

Key words: Adrenal Cortex Hormones; Albendazole; Central Nervous System Infection; Eosinophilia; Magnetic Resonance Imaging; Toxocariasis.

Lesiones cerebrales asociadas con eosinofilia. Una clave útil en neurotoxocariasis

La neurotoxocariasis es infrecuente. Sus manifestaciones incluyen eventos de meningitis, encefalitis y con menor frecuencia vasculitis, que se manifiestan como cefalea, convulsiones, focalización, confusión, alteraciones cognitivas o fiebre. La eosinofilia periférica, junto a elementos clínicos e imágenes compatibles, permiten su sospecha. Informamos el caso de un trabajador agrícola de 48 años que ingresó por una semana de molestias gastrointestinales, cefalea, hemiparesia izquierda progresiva y deterioro de conciencia. Los exámenes revelaron leucocitosis (13.530/ μ L) con eosinofilia periférica (25%, recuento absoluto 3.400/ μ L). El análisis del LCR sin anomalías y la tomografía computada cerebral mostró lesiones hipodensas mal definidas en áreas subcorticales y centros semiovais. La resonancia magnética mostró múltiples focos con aumento de la señal predominantemente en la sustancia blanca en ambos

¹SubDepartamento de Medicina, Hospital Base de Valdivia, Valdivia, Chile.

²Instituto de Medicina, Facultad de Medicina, Campus Isla Teja, Universidad Austral de Chile. Valdivia, Chile.

³Sección Parasitología, Sub Departamento de Enfermedades Infecciosas, Departamento Laboratorio Biomédico, Instituto de Salud Pública de Chile. Santiago, Chile.

⁴Servicio de Neurología, Hospital Base de Valdivia. Valdivia, Chile.

⁵Instituto de Neurociencias Clínicas, Facultad de Medicina, Campus Isla Teja, Universidad Austral de Chile. Valdivia, Chile.

Conflicto de Interés: ninguno.

Financiamiento: ninguno.

Recibido el 7 de abril de 2021, aceptado el 6 de diciembre de 2021.

Correspondencia a:

Dr. Alberto Fica
SubDepartamento de Medicina,
Hospital Base de Valdivia, Chile.
Bueras 1003, Valdivia, Chile.
albertoficacubillos@gmail.com

hemisferios. Las lesiones presentaron refuerzo tras contraste paramagnético. Los estudios serológicos indicaron anticuerpos IgG específicos por ELISA contra antígenos del género *Toxocara*. El paciente fue tratado con albendazol (800 mg /día) durante 14 días asociado a corticoides con respuesta favorable y una recuperación gradual completa.

Palabras clave: Albendazol; Corticosteroides; Eosinofilia; Infecciones del Sistema Nervioso Central; Imagen por Resonancia Magnética; Toxocariasis.

Toxocariasis involve several clinical syndromes associated with the migration or permanence of *Toxocara canis* larvae or other rarer species in different human tissues. The infection is acquired after ingestion of full mature eggs present in soils, contact with canines, consumption of vegetables contaminated with dog feces or consumption of raw or improperly cooked liver. After their arrival into the intestine, the larvae developed from the eggs, manage to penetrate the intestinal wall, and migrate to different tissues^{1,2}. In adults, these syndromes include asymptomatic forms expressed only by eosinophilia, ocular migrant larvae (OML), visceral migrant larvae (VML), neurotoxocariasis and covert toxocariasis^{1,3,4}.

Ocular toxocariasis is an important cause of ocular morbidity in childhood and explained by exposure to contaminated soils or contact with canine pets⁵. This form accounts for less than 5% of the causes of uveitis in developing countries and is only occasionally associated with peripheral eosinophilia ($\leq 20\%$)^{6,7}. VML characteristically affects the lung or liver^{8,9}. In the first case, patients may present nonspecific respiratory symptoms in about half of cases with peripherally distributed nodules and/or ground glass infiltrates in CT imaging. In hepatic toxocariasis, patients present with single or multiple hypodense lesions with poorly defined borders along with occasional symptoms such as right upper quadrant abdominal pain. Cases of visceral pulmonary or hepatic toxocariasis have few important systemic manifestations or elevation of inflammatory parameters. However, they are notoriously associated with mild or moderate peripheral eosinophilia in about 85% of cases, which together with images and positive serological tests allow the diagnosis^{1,8,9}. Additionally, an increase in serum IgE titers is observed^{1,3,8,9}. Another compartmental condition is neurotoxocariasis, which involves the central

nervous system (CNS) in the form of transverse myelitis or cerebral toxocariasis with meningitis, encephalitis or vasculitis^{1,3}. This infection has also been invoked as a frequent cause of epilepsy in developing countries¹⁰.

The low frequency of this parasitic infection, has limited an appropriate clinical experience to raise an adequate suspicion and study, which is also surrounded by a broad differential diagnosis. Chilean literature has adequately described the extent of carriage in dogs and contamination by *T. canis* eggs in public squares and parks, as well as its seroprevalence in children and adults in urban or rural areas¹¹⁻¹⁴. However, the description of clinical pictures associated with this microorganism is very scarce and limited to few publications^{4,15} confirming the continuous need to communicate its different clinical forms.

Case Report

A 48-year-old agricultural worker with no known morbidity was admitted during year 2019 reporting one week of abdominal pain, vomiting, diarrhea, headache, and dizziness with paresis in the left lower limb and shortly after in the left upper limb. On admission he was disoriented without fever or hemodynamic or respiratory compromise. Physical examination showed no abnormalities except for mild diffuse abdominal tenderness without Blumberg's sign and a left M3 grade hemiparesis without meningeal signs or cranial nerve involvement. Exams revealed leukocytosis (13,530/ μ L) with peripheral eosinophilia (25%, absolute count 3,400/ μ L). Neutrophil and lymphocyte count were normal. He also had thrombocytopenia (76,000/ μ L) and the erythrocyte sedimentation rate was 39 mm /h. Renal function was preserved, and liver biochemical tests were normal. C-reactive protein was elevated

(4.2 mg/dL; normal ≤ 0.5 mg/dL). Rheumatoid factor, C3 and C4 serum complement levels and urine sediment showed no abnormalities. IgE levels were elevated (509.4; IU/ml; reference value ≤ 100 IU/ml). HIV and syphilis serological testing were non-reactive.

The patient evolved with drowsiness and contralateral hemiparesis. Brain CT showed poorly defined hypodense lesions on subcortical areas and semioval centers (Figure 1A). An embolic vascular event was proposed as an initial working hypothesis, including a possible event secondary

to infectious endocarditis; tissular parasitosis was also considered. The cerebrospinal fluid (CSF) study was normal without pleocytosis and with normal protein and glucose values. CSF and blood cultures were negative. The patient worked in farming activities in a rural area with frequent but indirect contact with dogs. Besides, pork consumption together with other family members 3 weeks before admission was retrieved during anamnesis, however, no trichinosis events were detected among relatives. Serological samples for trichinosis and toxocariasis diagnosis were

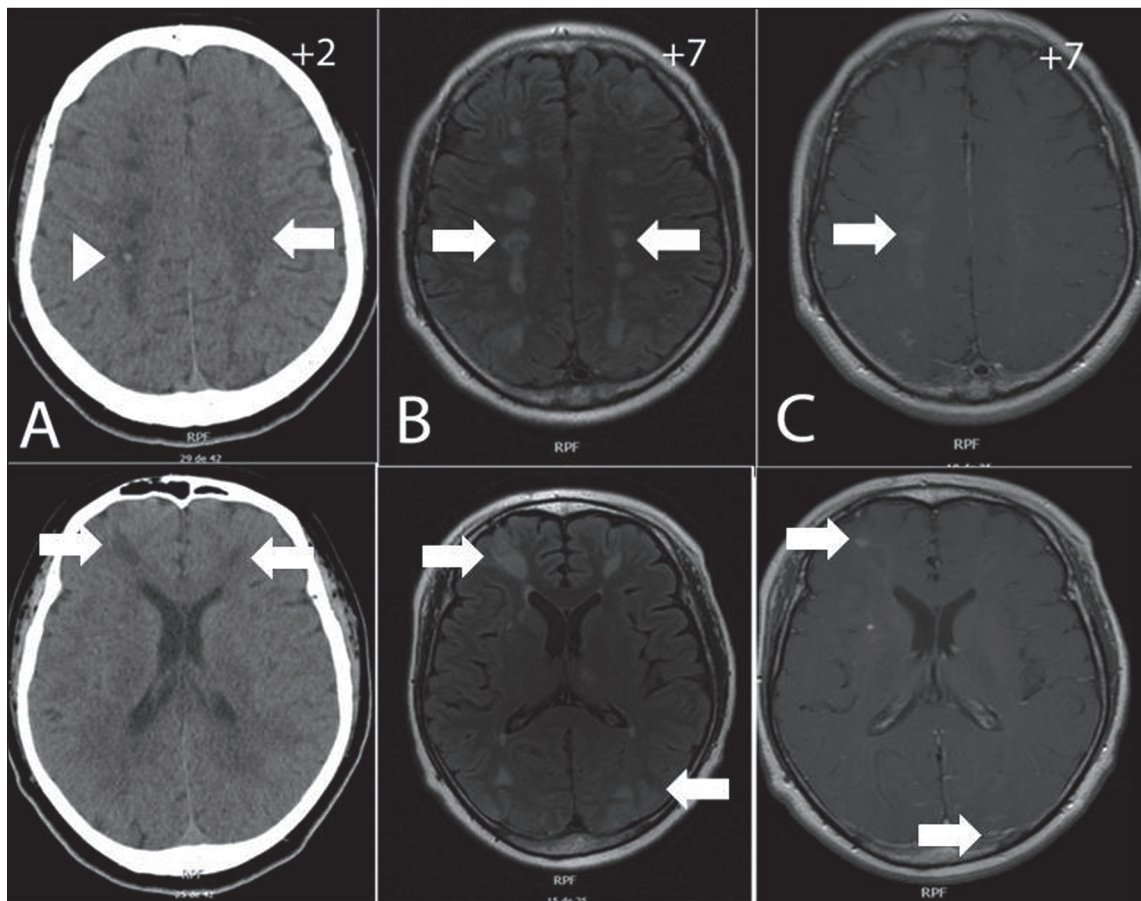


Figure 1. A: (Upper and lower figures): Brain CT images without contrast media obtained at 2 days post admission. Hypodense lesions are observed within semioval centers (arrow, upper figure) and in subcortical frontal areas (arrows, lower figure). Minor hemorrhagic points are also present (arrowhead in upper figure) that were corroborated by GRE T2-weighted MR sequence (not shown). **B:** (Upper and lower figures) FLAIR (*Fluid-Attenuated Inversion Recovery*) MR brain images in axial projection at 7 days post admission. Hypertense signals are observed in semioval centers (arrow, upper figure) and in frontal and occipital cortical-subcortical areas (arrows, lower figure). **C:** T1 signal in axial projection of brain MR with gadolinium (Gd, paramagnetic contrast). Gd-enhanced lesions are observed in semioval centers and in frontal and occipital areas (arrows). Images obtained at 7 days after admission.

referred to the National Reference Parasitology Laboratory.

The patient received empirical therapy with ceftriaxone and intravenous ampicillin for 48 hours which was suspended after having ruled out the possibility of infective endocarditis by negative blood cultures, echocardiography without vegetations and absent minor criteria. The patient also received acetyl-salicylic acid 100 mg/day with atorvastatin 80 mg/day due to the possibility of an acute cerebral vascular event, together with albendazole 400 mg every 12 hours orally and intravenous corticosteroids (dexamethasone 10 mg every 6 hours). He was transferred to the Intermediate Care Unit for close monitoring.

Patient evolved satisfactorily with consciousness recovery and complete regression of his right hemiparesis, and partial improvement on the left side. A thoracoabdominal-pelvic CT angiographic study besides a brain and carotid CT angiography ruled out embolic causes or vascular abnormalities and a control brain CT showed a partial regression of the hypodense lesions. Brain MRI indicated multiple foci with increased signal predominantly in the white matter in both hemispheres, especially at frontal and occipital regions and at semioval centers (Figure 1B). Lesions presented reinforcement after paramagnetic contrast (Figure 1C). Incidentally, a venous angioma was observed at the right fronto-temporal level (not shown).

Parasitic serological study ruled out antibodies against antigens of the genus *Trichinella* (ELISA IgG negative) and confirmed the presence of specific IgG antibodies by ELISA against antigens of the genus *Toxocara* that was confirmed by a positive IgG Western Blot. Corticosteroid therapy was trespassed to the oral route with prednisone 60 mg/day and after 2 weeks doses were gradually reduced. He completed a 14-day course of albendazole therapy and after 25 days, he was transferred to other hospital to complete his rehabilitation. Before discharge, he was evaluated by ophthalmology, ruling out eye compromise. A follow-up control at three weeks after discharge indicated improvement of the left hemiparesis. A complete recovery at 2 years was registered by a telephone call. Unfortunately, a brain control image, IgE levels or eosinophil count could not be performed due to the COVID pandemic and patient's rural condition.

Discussion

The neurotoxocariasis case presented here, of which a few hundred cases have been described in the literature, seems to be well documented by the presence of compatible brain CT and MRI images, the double positive serological study including confirmation by Western Blotting, peripheral eosinophilia, and the associated clinical picture. Manifestations of cerebral toxocariasis include events of meningitis, encephalitis and less frequently vasculitis, which manifest as headache, seizures, focalization, confusion, cognitive alterations and/or fever^{1,3}. Peripheral eosinophilia with clinical and neurological imaging elements, permit early suspicion and requesting of confirmatory serological studies.

The presence of mild or moderate peripheral eosinophilia ($> 500-5,000/\mu\text{L}$) is especially useful for neurotoxocariasis suspicion, since other causes of neurological pathologies that present with this feature are much more infrequent to observe than neurotoxocariasis itself. For example, *Coccidioides immitis* meningitis is an infrequent form of presentation of this geographic fungal infection already absent in the temperate climate of Chile. Likewise, gnathostomiasis, linked to the consumption of uncooked or raw freshwater fish rarely affects the CNS and, baylisascariasis, related to the inadvertent ingestion of parasitic eggs from raccoon droppings, is rare¹. Although *Fasciola hepatica* and *Trichinella* infections are associated with moderate or intense eosinophilia, they have another clinical profile, and other parasitic causes with CNS involvement such as neurocysticercosis, have not or just mild eosinophilia^{16,17}. Finally, other CNS diseases such as tuberculosis or lymphoma, exceptionally present eosinophilia. Table 1 shows important parameters observed in patients with neurotoxocariasis.

The optimal treatment of toxocariasis remains undefined due to the low frequency of these conditions which has prevented controlled studies and the self-limited and benign evolution of most cases¹⁸. In animal models, mebendazole and albendazole have shown to be larvicidal, but in high doses and for prolonged periods¹⁸. The evidence from the few observational, randomized, or non-randomized comparative studies in toxocariasis indicates that it is possible to obtain a favorable clinical and laboratory response using

Table 1. Relevant features of the reported case and comparison with data available from the literature

Variable	This case	Features previously reported focusing on neurotoxocariasis
Demographic	Adult, male, 47- year-old, rural condition	Cases concentrate in the middle age of life (40-50 years) and are predominately of the male sex (rate 2-3 to 1)
Zoonotic exposure	Farming worker with indirect contact with dogs	In adults, contact with dogs, living in rural areas or consumption of raw or improperly cooked liver. In children playing in public squares and parks, canine pet tenure or geophagy (for any kind of toxocariasis: asymptomatic or symptomatic). In the region of residence of the patient (South of Chile), a high prevalence of <i>T. canis</i> in dogs has been reported (reference 13)
Clinical features	Encephalitis with motor focalization. Neurotoxocariasis	Compartmental (ocular, lung, liver or CNS toxocariasis) or systemic syndromes with different organs and systems involvement. Brain toxocariasis is of rare occurrence and it manifest as meningitis, encephalitis, vasculitis, abscesses or hydrocephalia.
Peripheral eosinophilia	Moderate eosinophilia (3,800/ μ L)	Near 85% of CNS, lung or liver toxocariasis cases have mild or moderate eosinophilia that it useful as a diagnostic clue.
CSF study	Normal	For the 23 brain cases reported in a previous review with CSF analysis (reference 3) we calculated a median of 20 cells/ μ L (range 0-1,220; IQR 0-161/ μ L); 34.8% has 0 cell count on the CSF. For the few cases with eosinophil percentage available that have been reported (see reference 3), we calculated a median of 23% for this parameter (range 0-64%; IQR 9.5-54.7%)
Serological diagnosis	ELISA IgG + for <i>Toxocara genus</i> Western Blot + for <i>Toxocara genus</i> . ELISA IgG negative for <i>Trichinella sp.</i>	ELISA yield using larval antigens have a sensitivity of 78% and 92% specificity. Western Blot testing allows confirm infection and discard cross reactions. Occasionally, antibody studies from CSF have been applied either using ELISA and/or Western Blot.
Imaging	Brain CT: ill-defined hypodense lesions in both hemispheres mainly of subcortical distribution (contrast media not used). Brain RMI : multiple hyperintense lesions on FLAIR of subcortical distribution. Gadolinium-enhanced lesions on T1 signal.	Brain MR is the preference imaging technique. Neurotoxocariasis cases present hyperintense lesions on FLAIR or T2 signal, either as single or multiple lesions distributed in the cortex, subcortical zone or in the white matter. The use of gadolinium allows in some cases to demonstrate homogeneous, punctate or ring reinforcement.
Treatment	Albendazole as 10 mg/Kg /day (oral route) for 2 weeks and corticosteroids in high doses.	There are no guidelines for an optimal treatment. Most of the reported cases of cerebral toxocariasis have been treated with albendazole and corticosteroids.
Evolution and outcome	Favorable	Favorable in reported cases

antimicrobial regimens in high doses or for prolonged periods¹⁹⁻²³. For example, in a randomized open-label study, about 50% efficacy was observed with albendazole (10 mg/Kg/d) or thiabendazole

(50 mg/kg/d) in cases of OML or VML²³. The application of mebendazole at doses of 20-25 mg/kg/d has a similar efficacy to diethylcarbamazine in regimens of 3 weeks duration²⁰. The self-limi-

ted nature of toxocariasis has been evidenced in some studies with low dose of mebendazole (10-15 mg/kg/d) where it has not been found to be superior to placebo in accelerating symptomatic improvement¹⁹. Of 34 cases of cerebral toxocariasis reported up to 2015, half of them had been treated with albendazole and corticosteroids³. Of the group with cerebral toxocariasis, approximately 76% recovered, 11% worsened, and the rest remained in stable conditions³. Although there are no validated guidelines for the management of this form, the vital prognosis of neurotoxocariasis has been favorable with no fatal cases in patients with confirmed infection³.

Referencias

1. Finsterer J, Auer H. Neurotoxocarosis. *Rev Inst Med Trop Sao Paulo* 2007; 49(5):279-87.
2. Dzikowiec M, Góralaska K, Błaszowska J. Neuroinvasions caused by parasites. *Ann Parasitol*. 2017;63(4):243-53.
3. Sánchez SS, García HH, Nicoletti A. Clinical and Magnetic Resonance Imaging Findings of Neurotoxocariasis. *Front Neurol*. 2018 Feb 8;9:53.
4. Sánchez T JE, López G JP, González N M, Villaseca D E, Manieu M D, Roizen B A, et al. Detección de lesiones oculares en niños seropositivos para *Toxocara canis*. *Rev Chilena Infectol* 2011;28(5):431-4.
5. Majumder PD, Ghosh A, Biswas J. Infectious uveitis: An enigma. *Middle East Afr J Ophthalmol* 2017;24(1):2-10.
6. Biswas J, KharelSitaula R, Multani P. Changing uveitis patterns in South India - Comparison between two decades. *Indian J Ophthalmol* 2018;66(4):524-27.
7. Gillespie SH, Dinning WJ, Voller A, Crowcroft NS. The spectrum of ocular toxocariasis. *Eye (Lond)* 1993;7 (Pt 3):415-8.
8. Park BM, Jeong SO, Park HS, Jung SS, Kim SY, Kim JO, et al. Differences in the clinical and radiological characteristics of lung-involved toxocariasis between toxocariasis with eosinophilia and those without eosinophilia. *J Thorac Dis* 2014 ;6(12):1757-64.
9. Ha KH, Song JE, Kim BS, Lee CH. Clinical characteristics and progression of liver abscess caused by toxocara. *World J Hepatol* 2016;8(18):757-61.
10. Allahdin S, Khademvatan S, Rafiei A, Momen A, Rafiei R. Frequency of *Toxoplasma* and *Toxocara Sp.* Antibodies in Epileptic Patients, in South Western Iran. *Iran J Child Neurol*2015;9(4):32-40.
11. Mercado R, Ueta MT, Castillo D, Muñoz V, Schenone H. Exposure to larva migrans syndromes in squares and public parks of cities in Chile. *Rev Saude Publica* 2004;38(5):729-31.
12. Vargas C, Torres P, Jercic MI, Lobos M, Oyarce A, Miranda JC, et al. Frequency of anti- *Toxocara spp.* antibodies in individuals attended by the Centro de Salud Familiar and environmental contamination with *Toxocara canis* eggs in dog feces, in the coastal Niebla Town, Chile. *Rev Inst Med Trop Sao Paulo* 2016;58:62.
13. Torres P, Franjola R, Pérez J, Auad S, Hermosilla C, Flores L, et al. Geohelmintiasis intestinales en hombre y animales domésticos de sectores ribereños de la cuenca del río Valdivia Chile. *Bol Chil Parasitol* 1995; 50(3/4): 57-66.
14. Triviño X, Bedregal P, Torres M, Canales M, Alvarado C, Hernández R. Toxocariosis en Chile: Serie clínica en un centro de pediatría ambulatoria. *Parasitol Día* 1993; 23(3/4):113-17.
15. Rugiero E, Cabrera ME, Ducach G, Noemi I, Viovy A. Toxocariasis sistémica en el paciente adulto. *Rev Med Chile* 1995;123(5):612-6.
16. Fica A, Castro M, Soto A, Flores C, Oelker C, Weitzel T. Neurocisticercosis, una enfermedad desatendida en Chile. *Rev Chilena Infectol* 2012; 29:72-81
17. Fica A, Dabanch J, Farias C, Castro M, Jercic MI, Weitzel T. Acute fascioliasis-clinical and epidemiological features of four patients in Chile. *Clin Microbiol Infect* 2012; 18:91-96.
18. Othman AA. Therapeutic battle against larval toxocariasis: are we still far behind? *Acta Trop* 2012;124(3):171-8.
19. Magnaval JF, Charlet JP, Delarrard B. Double blind study of the efficacy of mebendazole in minor forms of human toxocariasis. *Therapie*1992; 47:145-148.
20. Magnaval JF. Comparative efficacy of diethylcarbamazine and mebendazole for the treatment of human toxocariasis. *Parasitology* 1995;110 (Pt 5):529-33.
21. Wiśniewska-Ligier M, Woźniakowska-Gęsicka T, Sobolewska-Dryjańska J, Markiewicz-Jóźwiak A, Wiczorek M. Analysis of the course and treatment of toxocariasis in children-a long-term observation. *Parasitol Res* 2012; 110(6):2363-71.
22. Bass JL, Mehta KA, Glickman LT, Blocker R, Eppes BM. Asymptomatic toxocariasis in children. A prospective study and treatment trial. *Clin Pediatr (Phila)* 1987; 26(9):441-6.
23. Stürchler D, Schubarth P, Gualzata M, Gottstein B, Oetli A. Thiabendazole vs. albendazole in treatment of toxocariasis: a clinical trial. *Ann Trop Med Parasitol* 1989; 83(5):473-8.