



## CLAUDE'S SYNDROME: CLINICAL AND COMPUTED TOMOGRAPHY CORRELATIONS

E. WOO, MB, MRCP, C. Y. HUANG, MB, FRACP, F. L. CHAN, MB, FRCR, AND Y. L. YU, MD, MRCP

*A patient with Claude's syndrome (ipsilateral fascicular third nerve palsy with contralateral ataxia) in whom computed tomography demonstrated a discrete infarct in the paramedian rostral mesencephalic tegmentum is reported. The vascular supply of the rostral mesencephalon is discussed.*

### KEY WORDS:

Claude's syndrome; Fascicular third nerve palsy

Third nerve palsy with pupillary involvement is most commonly the result of intracranial aneurysm (1). Other causes include trauma, neoplasms, and vascular diseases (2). Occlusive diseases of the vertebrobasilar arterial system (3) may produce a variety of oculomotor disturbances. However, a fascicular third nerve palsy due to a mesencephalic infarct is uncommon; it may occur in association with contralateral hemiplegia (Weber's syndrome) or contralateral hemiataxia (Claude's syndrome).

We recently encountered a patient who had a complete fascicular third nerve palsy associated with contralateral hemiataxia in whom computed tomography (CT) demonstrated a unilateral paramedian mesencephalic infarction. To our knowledge, this is the first case of Claude's syndrome to be documented by CT.

### CASE REPORT

A 66-year-old businessman who previously had been in good health awoke on the day of admission with acute left-sided ptosis and difficulty in walking. He was noted to be confused and disoriented. There was no history of trauma, headache, or loss of consciousness. Symptomatology continued over the next 3 weeks, and he was referred to our unit for further evaluation.

Neurologic examination revealed moderate global cognitive dysfunction and a complete left third nerve palsy with complete ptosis, an 8-mm nonreactive pupil, and paralysis of all the extraocular muscles innervated by the third nerve. The right upper and lower limbs were ataxic, but no tremor was observed. There were no sensory deficits, and the rest of the examination showed no abnormality. A clinical diagnosis of Claude's syndrome was made.

The patient made a slow recovery in his cognitive functions over the next 3 months. The left ptosis improved, with the palpebral fissure measuring 3 mm, but there was no return of function in the pupil and the extraocular muscles. He was able to stand with support; when he attempted to walk, he leaned to the right.

Investigations showing normal results included full blood counts, VDRL test, electrocardiogram, and sedimentation rate, coagulation, glucose, lipids, and cerebrospinal fluid studies.

### Computed Tomography Studies

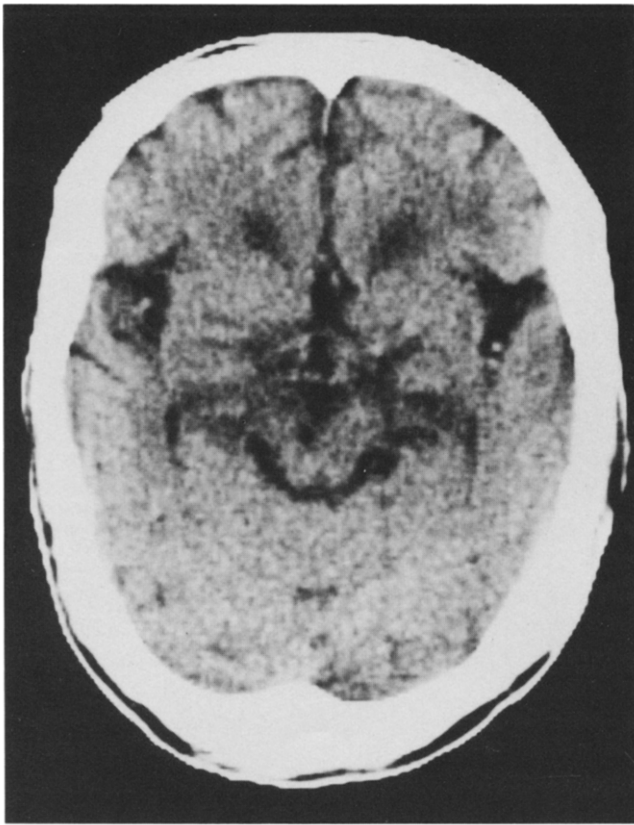
On the day of the ictus, CT of the brain performed at the referring institute showed mild cerebral atrophy with no focal lesions. Repeat CT 1 month later, performed with a GE 9800 scanner with a 256 × 256 matrix, revealed a nonenhancing hypodense area in the left paramedian mesencephalic tegmen-

From the Departments of Medicine and Diagnostic Radiology, Queen Mary Hospital, University of Hong Kong, Hong Kong.

Address reprint requests to: E. Woo, MB, MRCP, University Department of Medicine, Queen Mary Hospital, Hong Kong.

Received May 1986.

© 1987 by Elsevier Science Publishing Co., Inc.  
52 Vanderbilt Avenue, New York, NY 10017  
0149-936X/87/\$3.50



**FIGURE 1.** Noncontrast CT scan of the brain at the level of the mesencephalon showing a small hypodense area in the left paramedian mesencephalic tegmentum.

tum (Figure 1). Additional scanning using a  $512 \times 512$  matrix was performed after 2 months. It was targeted at the upper brain stem, with 3-mm slices parallel to the orbitomeatal line. The lucent area was confirmed as consistent with an infarct measuring 5.5 mm in transverse diameter and 6 mm in rostrocaudal extension, with a density of 1 Hounsfield unit (HU). The exact anatomic site was also delineated; it was situated in the paramedian mesencephalic tegmentum at the level of the superior colliculi in the region of the left red nucleus and the left third nerve fascicle (Figure 2A), and sparing the periaqueductal gray matter.

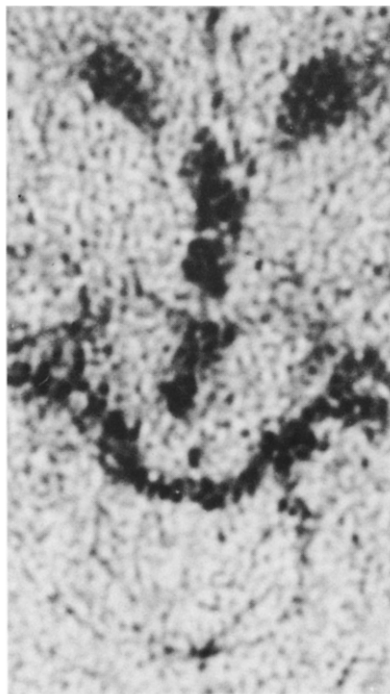
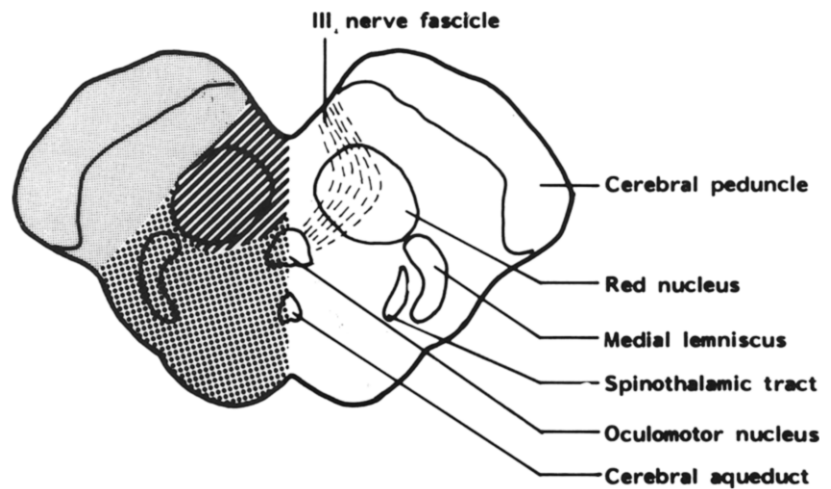
## DISCUSSION

Claude's syndrome was first described in 1912 in a 56-year-old man with diplopia, unilateral ptosis, and contralateral cerebellar ataxia due to a paramedian midbrain infarct (4). Our patient demonstrated

the typical clinical and CT features of this vascular syndrome. The initial disorientation with a complete unilateral third nerve palsy suggested a ruptured aneurysm, especially with ipsilateral pupillary dysfunction. However, the normal cerebrospinal fluid and subsequent CT findings excluded this pathologic entity. Likewise, traumatic and neoplastic lesions were also excluded from the history and the course of events. On the other hand, the constellation of oculomotor and behavioral disturbances without significant motor abnormalities was reminiscent of the "top of the basilar" syndrome (5), which is characterized by marked rostral brain stem dysfunction.

Although ophthalmoplegia is a well-known manifestation in vertebrobasilar arterial diseases (3), precise localization by CT is often difficult. In our patient, the CT demonstration of a paramedian mesencephalic infarct provided an opportunity for *in vivo* clinicoanatomic correlation in this uncommon syndrome. The third nerve, upon leaving the oculomotor nucleus complex in the dorsal midbrain, travels ventrally following a paramedian course through the tegmentum, red nucleus, and medial part of the substantia nigra before emerging from the sulcus on the medial side of the cerebral peduncle. This fascicle carries the parasympathetic fibers for pupillary constriction and the motor fibers to the ipsilateral levator palpebrae superioris, in addition to those for extraocular movements. A unilateral paramedian midbrain lesion involves the third nerve fascicle and the dentatorubrospinal fibers, resulting in ipsilateral third nerve palsy and contralateral ataxia. It is most unlikely that the lesion in our patient involved the oculomotor nucleus complex; such a lesion would produce bilateral ptosis because the unpaired central caudal subnucleus provides bilateral innervation to the levator palpebrae (6, 7). This was confirmed on CT by the sparing of the periaqueductal gray matter, within which is situated the third nerve nucleus.

The vascular supply of the rostral midbrain (Figure 2B) is generally divided into three main territories (8, 9) fed by branches of the posterior cerebral artery. A long circumferential branch supplies the dorsolateral aspect of the tegmentum, infarction of which causes ipsilateral Horner's syndrome with contralateral sensory loss, due to involvement of the descending sympathetic fibers and the ascending sensory pathways in the dorsolateral quadrant. The basal portion of the midbrain including the cerebral peduncle is supplied by a short circumferential (peduncular) branch. A paramedian perforating branch supplies the paramedian area including the third

**A****B**

**FIGURE 2.** (A) Targeted view of the rostral mesencephalon at the level of the superior colliculi showing the paramedian infarct in the region of the left third nerve fascicle and left red nucleus. (B) A schematic representation of a transverse section of the corresponding level of the rostral

mesencephalon showing the three vascular territories. Gray area = territory of the short circumferential (peduncular) branch; striped area = territory of the paramedian perforating branch; dotted area = territory of the long circumferential branch.

nerve fascicle and the red nucleus. It was the occlusion of this vessel that resulted in our patient's clinical presentation.

We thank Mrs. Shirila Tam for secretarial assistance.

## REFERENCES

1. Rucker CW: Paralysis of the third, fourth and sixth cranial nerves. *Am J Ophthalmol* 1958;46:787-94.
2. Rush JA, Younge BR: Paralysis of cranial nerves III, IV and VI. Cause and prognosis in 1,000 cases. *Arch Ophthalmol* 1981;99:76-9.
3. Minor RH, Kearns TP, Millikan CH, et al.: Ocular manifestations of occlusive disease of the vertebral-basilar arterial system. *Arch Ophthalmol* 1959;62:84-96.
4. Claude H, Loyez: Ramollissement du noyau rouge. *Rev Neurol (Paris)* 1912;23:49-51.
5. Caplan LR: "Top of the basilar" syndrome. *Neurology* 1980;30:72-9.
6. Warwick R: Representation of the extraocular muscles in the oculomotor nuclei of the monkey. *J Comp Neurol* 1953;98:449-504.

7. Growdon JH, Winkler GF, Wray SH: Midbrain ptosis. A case with clinicopathologic correlation. *Arch Neurol* 1974;30:179-81.
8. Fisher CM: The anatomy and pathology of the cerebral vasculature. In Meyer JS (ed): *Modern concepts of cerebrovascular disease*. New York: Spectrum, 1975:1-41.
9. Patten J: The brainstem. In *Neurological differential diagnosis*. New York: Springer-Verlag, 1977:113-4.

## CONTINUING MEDICAL EDUCATION QUESTIONS

1. Claude's syndrome describes the association of third nerve palsy with:
  - a. Contralateral parkinsonism.
  - b. Contralateral hemiplegia.
  - c. Contralateral hemisensory disturbance.
  - d. Contralateral hemiataxia.
2. In the midbrain tegmentum, the third nerve fascicle traverses the following:
  - a. The red nucleus.
  - b. The medial lemniscus.
  - c. The lateral spinothalamic tract.
  - d. The globus pallidus.

3. The paramedian mesencephalic tegmentum is supplied by:
  - a. A long circumferential branch of the posterior cerebral artery.
  - b. A peduncular branch of the posterior cerebral artery.
  - c. A paramedian branch of the middle cerebral artery.
  - d. A paramedian branch of the posterior cerebral artery.
4. An oculomotor nucleus complex infarction is likely to produce unilateral ptosis.
  - a. True.
  - b. False.