

*Case Report***Transient global amnesia with transient anosmia: a curious case suggestive of middle cerebral artery occlusion**Takahiko Nagamine^{1,*}¹Department of Emergency Medicine, Sunlight Brain Research Center, 4-13-18 Jiyugaoka, Hofu, 747-0066 Yamaguchi, Japan*Correspondence: tnagamine@outlook.com (Takahiko Nagamine)

Academic Editor: Rafael Franco

Submitted: 29 January 2021 Revised: 16 February 2021 Accepted: 29 April 2021 Published: 30 May 2022

Abstract

Background: Transient global amnesia (TGA) is an enigmatic amnesic syndrome and affects people in middle or older age. During an episode of TGA, a person is not able to make new memories, which indicates hippocampal damage. The symptom anosmia may be associated with memory impairment. **Case presentation:** A 70-year-old woman presented to our emergency room with transient spatial memory loss. She also complained of a sudden loss of smell. Magnetic resonance angiography confirmed occlusion of the right middle cerebral artery. **Discussion and conclusion:** The mechanism causing the transient anosmia may have resulted in a transient loss of hippocampal function, resulting in amnesia. This rare case is consistent with recent research showing that olfaction has developed as a navigation system.

Keywords: Transient global amnesia; Anosmia; Middle cerebral artery occlusion**1. Introduction**

We report a patient with transient global amnesia (TGA) with transient anosmia. TGA is an enigmatic amnesic syndrome and affects people in middle or older age [1]. During an episode of TGA, a person is not able to make new memories, which indicates hippocampal damage. However, there are no reports that TGA is accompanied by transient olfactory loss probably due to middle cerebral artery occlusion. This rare case may indicate a relationship between olfaction and memory.

2. Case presentation

A 70-year-old woman without significant medical history was transferred to our emergency room following a short episode of amnesia. According to her sister, she went out to deliver newspapers as usual. However, five hours later, she was found wandering the streets with losing her sense of direction. By the time a passerby called 911 and the paramedics got her into the ambulance, she had no memory of leaving her house and no idea which direction her house was in. There were no features of retrograde amnesia, with the patient still being able to recall her identity. Her vital signs, including blood pressure, were normal and neurological examinations other than memory were unremarkable. Blood tests such as blood sugar, liver function, and kidney function were within normal limits, and a head computed tomography (CT) showed no abnormalities. She was diagnosed with TGA and was admitted to the hospital for observation. At lunch right after admission, she complained that she could taste it, but not smell it at all. With the improvement of the memory loss, the sense of smell also fully recovered and normalized within a few hours. On the

second day in the hospital, an electroencephalography and Holter electrocardiogram were performed with no major abnormalities. The Mini-Mental State Examination (MMSE) was performed and the score was 28 points, indicating no decline in cognitive function. On the third day of hospitalization, a magnetic resonance imaging (MRI) was performed and showed no abnormalities (Fig. 1A). However, magnetic resonance angiography (MRA) indicated the right middle cerebral artery occlusion (Fig. 1B). Cerebral blood flow measurement and cerebral angiography were scheduled on the fourth day of hospitalization, but she refused the tests because her symptoms such as amnesia and anosmia had improved. She was discharged on the fifth day of hospitalization after receiving aspirin 100 mg/day as antiplatelet therapy to prevent reduced blood flow due to microscopic thrombi in the small collateral blood vessels that would probably be present. TGA and anosmia did not occur during the one-year follow-up after discharge.

3. Discussion

TGA is a syndrome featuring acute anterograde amnesia as the most prominent clinical manifestation. Approximately every tenth patient with suspected TGA either had an alternative diagnosis or a severe comorbidity, which had not been obvious at the time of admission [2]. The most important differential diagnosis was cerebrovascular diseases. CT and MRI are usually sufficient for differential diagnosis, but rarely, as in this case, MRA alone shows abnormalities. The brain region associated with TGA is the hippocampus, and diffusion-weighted imaging (DWI) may show regular dot-like hyperintense lesions on the outside of the hippocampus [3]. However, in this case, no hip-



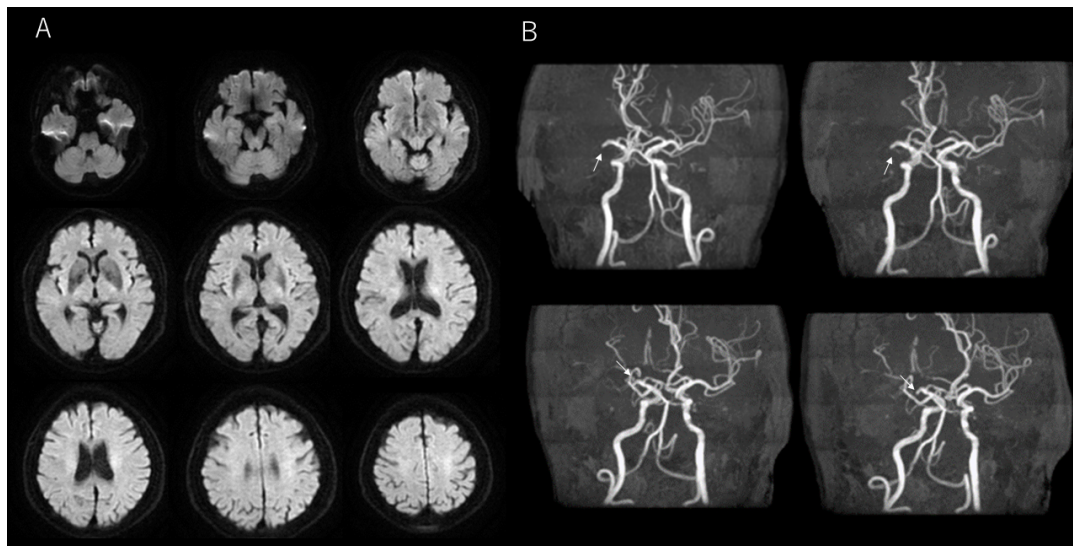


Fig. 1. MRI and MRA. Axial diffusion-weighted imaging showed no abnormality (A), however magnetic resonance angiography indicated the right middle cerebral artery occlusion(B).

hippocampal lesion was observed on MRI. Moreover, the hippocampus is supplied by the posterior cerebral artery, not the middle cerebral artery. Therefore, in this case, we considered the possibility that the mechanism that causes transient anosmia induces transient hippocampal hypofunction, resulted in amnesia. Olfactory deficit is caused by damage to the orbitofrontal cortex, which receives its vascular supply from the middle cerebral artery. The recent study by Dahmani *et al.* [4] indicated that olfaction and spatial memory are linked to overlapping brain areas which include the orbitofrontal cortex and hippocampus. And they speculated that this relationship may find its roots in the parallel evolution of the olfactory and hippocampal systems [4]. The present case seems to be a rare case in which transient anosmia caused by middle cerebral artery occlusion may have temporarily impaired spatial memory in the hippocampus. A limitation of this paper is that we were unable to examine the collateral blood flow because the patient refused cerebral angiography because of symptomatic improvement. Therefore, there is still a possibility that the middle cerebral artery occlusion caused transient hypofunction of the frontal lobe or medial temporal lobe, which led to amnesia. However, despite the limitation, the coexistence of transient anosmia and transient spatial memory deficits may suggest that memory and olfaction are interrelated. This rare case is consistent with recent research showing that olfaction has developed as a navigation system [4].

Abbreviations

CT, computed tomography; DWI, diffusion-weighted imaging; MMSE, mini-mental state examination; MRI, magnetic resonance imaging; MRA, magnetic resonance angiography; TGA, transient global amnesia.

Author contributions

TN took charge of this case, analyzed the data, and wrote the paper.

Ethics approval and consent to participate

Informed consent of the patient was obtained. The institutional review board of the *Sunlight Brain Research Center* approved the publication.

Acknowledgment

I would like to thank all the staff involved in the treatment of this case.

Funding

This research received no external funding.

Conflict of interest

The author declares no conflict of interest.

References

- [1] Liampas I, Raptopoulou M, Siokas V, Bakirtzis C, Tsouris Z, Aloizou AM, *et al.* Conventional cardiovascular risk factors in transient global amnesia: systematic review and proposition of a novel hypothesis. *Frontiers in Neuroendocrinology*. 2021; 61: 100909.
- [2] Werner R, Woehrle JC. Prevalence of mimics and severe comorbidity in patients with clinically suspected transient global amnesia. *Cerebrovascular Diseases*. 2021; 50: 171–177.
- [3] Förster A, Griebel M, Gass A, Kern R, Hennerici MG, Szabo K. Diffusion-weighted imaging for the differential diagnosis of disorders affecting the hippocampus. *Cerebrovascular Diseases*. 2012; 33: 104–115.
- [4] Dahmani L, Patel RM, Yang Y, Chakravarty MM, Fellows LK, Bohbot VD. An intrinsic association between olfactory identification and spatial memory in humans. *Nature Communications*. 2018; 9: 4162.