

Palinopsia and Visual Allesthesia

Alfredo Ardila, Manuel Botero & Jaime Gomez

To cite this article: Alfredo Ardila, Manuel Botero & Jaime Gomez (1987) Palinopsia and Visual Allesthesia, International Journal of Neuroscience, 32:3-4, 775-782, DOI: [10.3109/00207458709043332](https://doi.org/10.3109/00207458709043332)

To link to this article: <http://dx.doi.org/10.3109/00207458709043332>



Published online: 07 Jul 2009.



Submit your article to this journal [↗](#)



Article views: 15



View related articles [↗](#)



Citing articles: 2 View citing articles [↗](#)

PALINOPSIA AND VISUAL ALLESTHESIA

ALFREDO ARDILA, MANUEL BOTERO and JAIME GOMEZ

Instituto Neurologico de Colombia

(Received February 22, 1986)

Two cases of palinopsia are reported. The first patient had palinopsia and visual allesthesia secondary to an occipital calcified cysticercus. Symptoms were more prominent during treatment for his parasitic infection. The second case was a patient with long standing vascular headaches associated for many years with episodes of visual persistence; he had a right occipital lobe infarct; he reported deformation of images, illusion of movement and macropsia in his left homonymous hemianoptic visual field. Different hypotheses for explaining palinopsia have been proposed. An analysis of our cases does not prove or disprove any of the current hypotheses. However, the current hypotheses do not necessarily contradict each other. Implications of the two cases reported are analyzed.

Keywords: palinopsia; allesthesia; brain injury; visual symptoms

Different types of visual hallucinations have been described following lesions of the occipital cortex (e.g., Brown, 1985). Polyopia refers to the perception of multiple images even with monocular vision, associated sometimes with parieto-occipital insults and fixation nystagmus (Gloning, Gloning & Hoff, 1968; Brown, 1985).

Palinopsia relates to visual persistence or recurrence of images after the visual stimulation has disappeared. It is associated with hemianoptic field defects (mainly in the left visual field) (Bender, Feldman & Sobin, 1968; Meadows & Munro, 1977; Michel & Troost, 1980; Cummings et al., 1982). Recurrent images can persist immediately, return after sometime and may even last several hours. Cases have been reported in which the illusory image mixes with the current visual experience: Meadows and Munro (1977) for example, published a case report of a patient with the illusion of seeing everybody with a white beard and a red costume following Christmas.

Persistence of perception after disappearance of stimuli has also been described in the auditory system. It is referred to as palinacusia; recurrence of sounds, words or phrases have been reported (Jacob et al., 1973). Palinesthesia refers to the persistence of a tactile sensation (Cummings et al., 1982).

In rare occasions, palinopsia can be associated with visual allesthesia: objects located in the normal side of the visual field appear in the opposite visual field; this might be interpreted as diplopia, with two images, the real and the illusory ones (Jacob, 1979, 1980).

Paroxysmal visual illusions, as distortion of images, micropsia, macropsia, and so on, have been associated with lesions of the optic radiations; complex visual illusions can occur in lesions around the parahippocampal area (Ardila et al., 1986). Interpretation of palinopsia and visual allesthesia as paroxysmal disorders is still subject to controversy (Bender et al., 1968; Cummings et al., 1982).

Mailing address: Alfredo Ardila, Instituto Neurologico de Colombia, Apartado Aereo 17021, Bogota - COLOMBIA, South America.

Observations of palinopsia in temporo-occipital lesions, mainly on the right side, with invasion of the lingual and fusiform gyri have been reported (Meadows & Munro, 1977; Michel & Troost, 1980).

We present here two cases of palinopsia, one of them associated with visual allesthesia. We consider possible mechanisms responsible for these phenomena and analyze mechanisms the physiopathological hypotheses proposed.

Case 1

A 37 year old driver, first experienced episodes of blinking colored lights in his right visual field for a few seconds. On two occasions loss of consciousness followed this phenomenon. Twelve days prior to admission, a single episode of phosphenes occurred before turning his head to the right side and he had a generalized tonic-clonic seizure with loss of consciousness.

On admission to the Neurological Institute of Colombia his physical and neurological examinations were normal. He was right-handed (negative familial sinistrality), his language was normal; no color agnosia was detected; his eye movements were normal. Visual acuity was 20/200 with severe astigmatism, satisfactorily corrected with lenses. Visual fields were normal on tangent screen (Figure 1).

Computerized tomography showed multiple small calcifications on the left frontal, left occipital and right parietal areas, suggesting the possibility of neurocysticercosis (Figure 2).

EEG was normal. Alpha activity had an 11 Hz frequency at the occipital leads. Visual stimulation gave a poor response bilaterally.

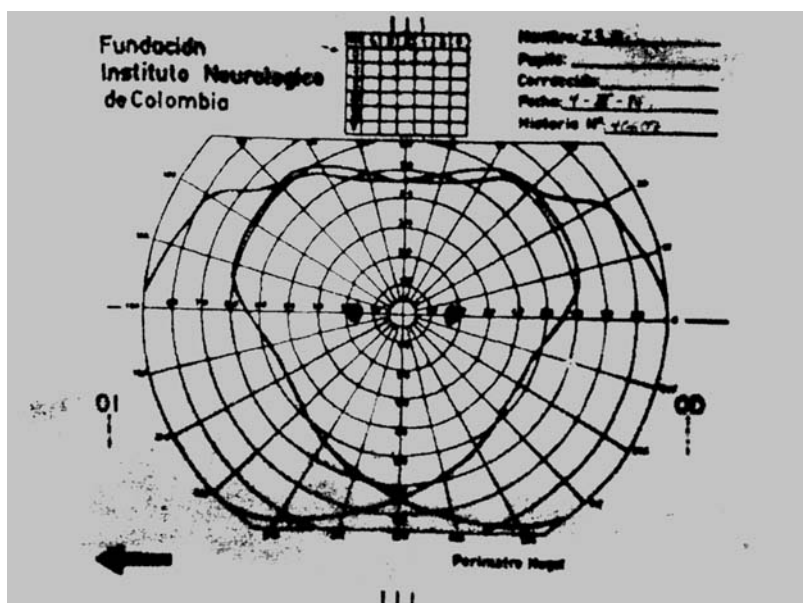


FIGURE 1 Patient 1: visual fields by tangent screen.

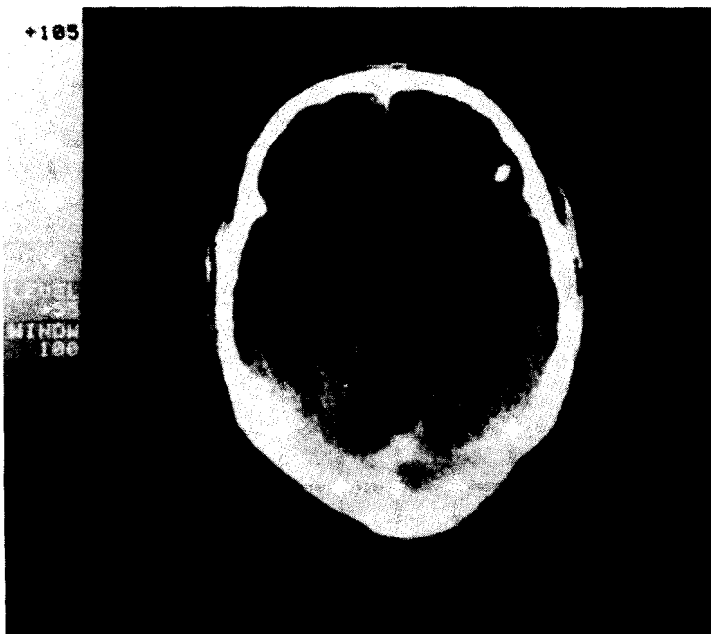
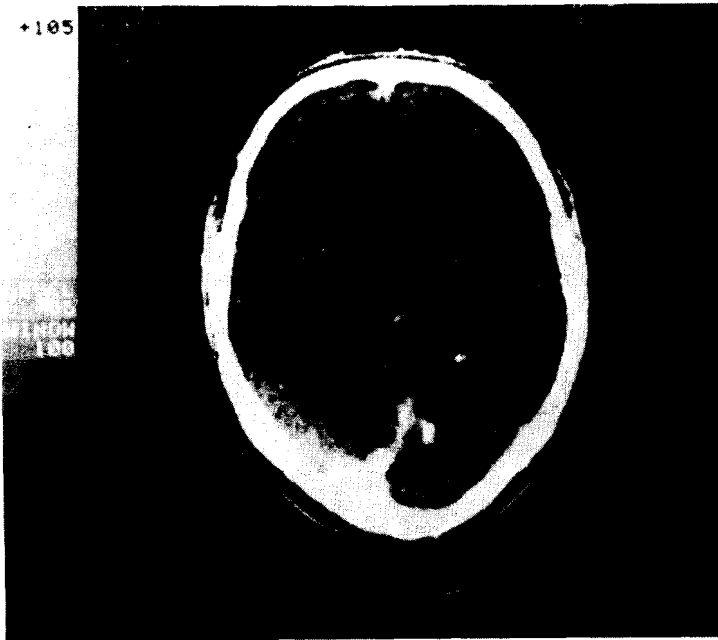


FIGURE 2 Patient 1: CT with contrast enhancement. Left occipital calcification.

ELISA test was positive for cysticercosis. Treatment with praziquantel 50 mg/kg/day in divided doses was given for 15 days. Phenytoin 300 mg/day was also given. Four days after admission a discrete rash on the abdomen was observed. Phosphenes with colored lights in the right visual field occurred several times. On the fifth day the patient reported new visual experiences: black-outs like "I was blinking and the light was gone"; that night he had a generalized seizure.

On the 6th day monocular diplopia was reported; a right homonymous field defect was recorded on confrontation. Thirty mg of steroids were given. The following days he had palinopsia. Phenytoin was changed for Carbamazepine (1 g/day). Persistence of visual images decreased in frequency and duration. Simple visual illusions with false images in the left visual field and monocular diplopia recurred; no visual field defects were found on confrontation.

On the 16th day the patient was discharged with a prescription of Tegretal (1 g/day).

Ten days later he reported the occurrence of simple visual hallucinations on the right visual field. He informed "blinking" images when looking at the edges of a door, a table, etc. Difficulty in judging the distance of objects produced occasional failure in his visuomotor coordination.

Palinopsia occurred during his hospitalization (on the 7th day). While lying in bed an orderly came into his room from his right side, bringing a tray. The perception of this image recurred for about one hour in his right visual field; when the image crossed to the left, it disappeared and the sequence started again. The patient realized nobody was entering his room but the image was equal in shape, color and speed of movement with the original. A similar experience was recorded the following day with less duration and frequency.

Monocular Diplopia was reported several days at different times from his palinopsia. He reported seeing double even when covering either eye; closing both eyes made the double images disappear. He knew the real image was always on the right side as if "the left eye [visual field] was seeing independently from the right," "the right eye was stronger than the left and the left image was identical." Occasionally, the false image appeared and disappeared. The two images were always duplicated in the horizontal plane and both moved with the motion of the objects.

Distortion of contours and visuomotor incoordination were reported only after his discharge from the hospital. The patient reported that at times the edges of the objects were brighter and appeared to blink. The abnormal perception of edges disappeared when he looked away. Errors in estimating distances were apparent to him when he tried to touch or grasp and object.

Comments. Simple visual hallucinations had occurred in his right visual field for 17 years, probably as a result of a left occipital lesion. During all these years, he never complained of palinopsia or monocular diplopia. Treatment increased his visual symptoms, visual hallucinations recurred more frequently, and palinopsia and monocular diplopia began. The skin rash, some dysuria, dizziness, and general malaise were associated with the treatment. Evidently, some exacerbation of visual symptoms was also apparent with the medication. It is of interest, that palinopsia was observed only in the right visual field and when the image crossed the midline, disappeared. It has been proposed that palinopsia develops in the affected visual field, although in occasions may be bilateral (Bender, 1970; Critchley, 1951).

Case 2

A 50 year-old executive, right-handed (negative familial sinistrality) was admitted complaining of recurrent episodes of global headaches and seeing lights, beginning six months earlier. The day prior to admission he had had a severe occipital headache associated with dizziness. For many years he had had occasional episodes of visual persistence lasting a few seconds.

On examination, he was alert, with normal language. A left homonymous hemianopsia was found. Extraocular movements were normal. Movements of the left extremities were awkward; a mild left hemisensory deficit for pain was noted.

Neuropsychological examination demonstrated difficulties in orienting in space, spatial alexia and prosopagnosia—he did not recognize even his own children. Colors were recognized but he made mistakes in recognizing superimposed figures.

A clinical diagnosis of right posterior cerebral artery occlusion was proposed. Computerized tomography showed an area of decreased attenuation in his right occipital area (Figure 3). Aspirin 150 mg/day was started.

He was discharged after seven days and a week later he returned for a follow-up examination. His left homonymous hemianopsia persisted (Figure 4) as well as some spatial difficulties and prosopagnosia.

Visual persistence. Even though the patient had a left homonymous hemianopsia, he had the impression that objects located in his left visual field moved closer toward him,

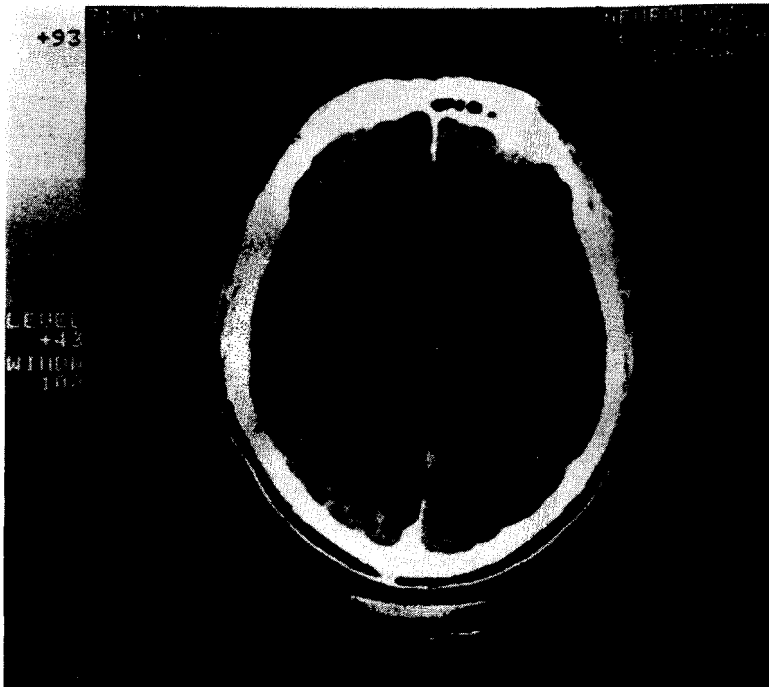


FIGURE 3 Patient 2: the CT shows an area of decreased density in the right occipital lobe.

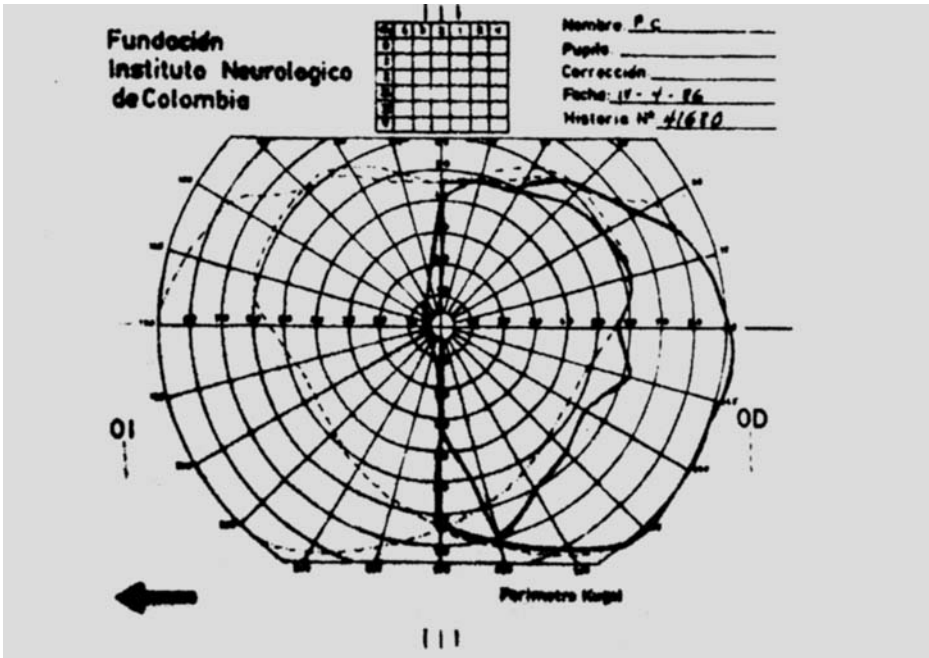


FIGURE 4 Patient 2: visual fields by tangent screen.

and after the objects was removed, the image persisted, repeating the motion performed. These images were perfectly distinct in color and he could describe them if requested. They did not fade away, but disappeared suddenly.

Visual illusions. After that the above described illusions, examination discovered other phenomena: when he was asked to draw a map, the outline on his right visual field was more or less correct but on the left side he stated that the sheet of paper enlarged towards the left and in fact his outline was greater on the left; then suddenly, he observed, the left side of the sheet disappeared. When an object such as a pencil or a paper was placed from his right in front to him, he noticed an apparent continuation of motion in his left visual field.

Such a phenomenon (palinopsia, illusion of motion, macropsia) appeared intermittently in episodes lasting up to 30 seconds during the 3rd day after admission and were accompanied by a severe occipital headache. The following days he was well, except for persistence of left homonymous hemianopsia, some spatial difficulties and prosopagnosia.

DISCUSSION

Palinopsia was associated in our first case with only transient defects in the visual field. Repeated tangent screen examination after discharge was normal; the second patient showed a complete left homonymous hemianopsia. Most reports of palinopsia in the

literature are associated with right temporo-occipital lesions but a few patients have palinopsia with lesions on the left side (Kinsbourne & Warrington, 1963; Michel & Troost, 1980).

Bender et al. (1968) proposed four possible explanations for palinopsia: (1) visual postimages, (2) sensory seizures, (3) psychogenic elaboration, and (4) hallucinations. Except for the third hypothesis, opinions have been divided. Kinsbourne and Warrington (1963) believe that there is an increase in the normal process of postimage formations, resulting in a pathologic overactivation of the nervous system, probably as a result of liberation of inhibitory influences. Cummings et al. (1982) postulate palinopsia as a type of release hallucination in which the excitatory stimulus occurred in the recent past. Other authors (e.g., Jacob, 1973; 1980, Swash, 1979) prefer the possibility of sensory seizures as the most likely explanation.

The evidence from our cases is not sufficient to prove or disprove any of the proposed hypotheses. Our patients presented a wide variety of visual manifestations. In case one, an important increment of visual hallucinations and even a generalized seizure during his hospitalization was observed, indicating some kind of hyperactivity of the cerebral cortex. In our opinion, this is not incompatible with the idea that palinopsia is a special hallucination in which the exciting stimulus occurred in the recent past (Cummings et al., 1982) as a consequence of disordered temporal synthesis of visual information (Michel & Troost, 1980).

It has been pointed out that there are important differences with visual postimages (Brown, 1985); we can consider the existence of a special type of hallucination. A postimage possibility represents the preservation of the nervous system activity after the stimulus is removed. The question might be, why the activity lasts for a long period of time? What inhibitory factors are absent? Differences between palinopsia and common postimages are obvious. It might be necessary to assume a pathological overactivity of the central nervous system underlying the visual perception (Kinsbourne & Warrington, 1963). In this sense, it would be a pathological type of post-image.

Visual allesthesia is a rare phenomenon. Only a few systematic reports are found in the literature (e.g., Herrmann, 1923; Herrmann & Potzl, 1928; Critchley 1951, 1954; Bender, 1970; Jacob, 1980). Jacob (1980) reported a case secondary to a right parieto-occipital lesion. His patient complained of monocular diplopia. The real object on the right was also perceived in the left hemianoptic field; the real object disappeared when looking to the other side but the illusion remained for about 15 minutes; the illusory image seemed about half the size but otherwise it was identical to the real image. In our case, transference occurred from the affected to the normal side which is similar to other forms of allesthesia; at times the illusory image appeared and disappeared; it was always identical with the real one; both disappeared simultaneously or were displaced in a parallel manner. This phenomenon was independent of palinopsia and not together as in Jacob's case. In our first patient, monocular diplopia persisted for hours or days associated with an increase in simple visual hallucinations and with a generalized seizure. It was also apparent that the right visual field defect was not a complete hemianopsia. The illusory image apparently resulted in the transference of the visual perception from the affected visual field to the normal side (Jacob, 1980) as a result of cortical excitation.

Kinsbourne and Warrington (1963) described the phenomenon of distortion of objects (blinking and brightening of the edges) associated with visual persistence. In our case, it was evident after palinopsia and monocular diplopia had disappeared.

The second patient with a long history of recurrent vascular headaches eventually had visual persistence and developed an occlusive lesion in the right occipital lobe. All abnormal visual phenomena were observed in the left visual field.

Analysis of palinopsia and visual allesthesia might help our understanding of the mechanisms of the cerebral organization of visual perception, and our knowledge about hallucinations and interhemispheric integration of visual informations.

ACKNOWLEDGEMENT

The present research was partially supported by a grant from COLCIENCIAS.

REFERENCES

- Ardila, A., Montanes, P., Bernal, B., Serpa, A. & Ruiz E. Partial psychic seizures and brain organization. *International Journal of Neuroscience*. 1986, **30**, 23-32.
- Bender, M. B. Perceptual interactions. In D. Williams (Ed). *Modern trends in neurology*, London: Butterworth, 1970.
- Bender, M. B., Feldman, M., & Sobin, A. J. Palinopsia. *Brain*, 1968, **91**, 321-338.
- Brown, J. W. Hallucinations. In J. A. M. Frederiks (Ed). *Handbook of clinical neurology*, vol. 45: *Clinical neuropsychology*. Amsterdam: Elsevier Science Publishers, 1985, pp. 351-372.
- Critchley, M. Types of visual perseveration: "palinopsia" and "illusory visual spread". *Brain*, 1951, **74**, 267-299.
- Critchley, M. Further remarks upon the phenomenon of visual perseveration. *Ges. Wurzburg*, 1954, **67**, 26-37.
- Cummings, J. L., Syndlulko, K., Golderg, Z. & Treiman, D. M. Palinopsia reconsidered. *Neurology* 1982, **32**, 444-447.
- Gloning, I., Gloning, H. & Hoff, H. *Neuropsychological symptoms and syndromes in lesions of the occipital lobe and adjacent areas*. Paris: Gauthier-Villars, 1968.
- Herrmann, G. Über eine eigenartige Propektionsstörung bei doppelseitiger Grobhirnlasion. *Monatschrift Psychiatrie Neurologie*, 1923, **55**, 99-104.
- Herrmann, G. & Pötzl, O. *Die Optische Alaesthesia*. Berlin: Berlin: S. Karger, 1928.
- Jacob, L. Visual allesthesia. *Neurology*, 1979, **29**, 599.
- Jacob, L. Visual allesthesia *Neurology*, 1980, **30**, 1059-1063.
- Jacob, L., Feldman, L., Diamond, S. P. Palinacusia: Persistent or recurring auditory sensations. *Cortex*, 1975, **9**, 275-287.
- Kinsbourne, M. & Warrington, E. A study of visual perseveration. *Journal of Neurology, Neurosurgery & Psychiatry*, 1963, **26**, 468-475.
- Meadows, J. C. & Munro, S. F. Palinopsia. *Journal of Neurology Neurosurgery & Psychiatry*. 1977, **40**, 5-8.
- Michel, E. B. & Troost, B. T. Palinopsia: cerebral localization with computed tomography. *Neurology*, 1980, **30**, 887-889.
- Swash, M. Visual perseveration in temporal lobe epilepsy. *Journal of Neurology Neurosurgery & Psychiatry*. 1979, **42**, 569-571.