

SINGLE CASE STUDY

Frégoli Syndrome after Cerebral Infarction

KAREL W. DE PAUW, M.R.C.PSYCH.,¹ T. KRYSZYNA SZULECKA, M.R.C.PSYCH.,² AND
TRACY L. POLTOCK, M.B.Ch.B.^{2,3}

A case of a rare form of delusional misidentification, the Frégoli syndrome, is described. Although usually occurring in the setting of primary or secondary schizophrenic psychoses, delusional misidentification has been reported in affective, neurological, and toxic-metabolic disorders. In this instance a diagnosis of paranoia (delusional disorder) secondary to predominantly right hemisphere pathology, rather than schizophrenia, seemed more appropriate.

In 1927 Courbon and Fail described a young female schizophrenic patient who identified various acquaintances, hospital staff members, and strangers as two well-known actresses of the time, whom she claimed were persecuting her. Although the former bore no physical resemblance to her persecutors, the patient claimed that they were psychologically identical and that she was able to discern their presence in bystanders when they interfered with her thoughts and actions or roused her sexually. She attributed their extraordinary abilities to their consummate acting skills and was convinced that they were also able to force her friends and relatives to assume the appearance of strangers and neighbours. The authors named the syndrome after the Italian actor and mimic, Leopoldo Frégoli, famous for his ability to impersonate people on stage.

The hallmark of the Frégoli syndrome is the delusional misidentification of familiar persons disguised as others. Phenomenologically it is closely related to the syndromes of Capgras, subjective doubles, and intermetamorphosis (Joseph, 1986a). Whereas the syndromes of Capgras and subjective doubles consist of a delusional belief in the existence of identical doubles of, respectively, familiar persons or the self, that of intermetamorphosis refers to the conviction that a key person has been physically transformed into another. Delusional misidentification is, however, not confined to persons, but may extend or be limited

to limbs, objects, location, and time. Nevertheless, these phenomena seem to represent variants of the same concept and may be categorized as syndromes of doubles or delusional misidentification (Christodoulou, 1978).

Although the most common diagnostic setting in which delusional misidentification occurs is that of primary (idiopathic) or secondary (symptomatic) schizophrenia, particularly paranoid schizophrenia (Berson, 1983; Christodoulou, 1976), cases have been reported in manic, depressive, epileptic, toxic-metabolic, and neurological disorders (Merrin and Silberfarb, 1976; Triccas *et al.*, 1985). The Frégoli syndrome has been described in combination with the syndromes of Capgras, subjective doubles, and intermetamorphosis as well as the delusional duplication of location and time (de Pauw and Szulecka, in press; Joseph, 1986b) and erotomania (Triccas *et al.*, 1985).

Etiological postulates of delusional misidentification reflect the psychodynamic/organic dichotomy that continues to bedevil the clarification of the psychosocial and neurological correlates of psychiatric disorders. Psychodynamic formulations include failure of repression of ambivalent feelings giving way to delusion or pathological splitting of internalized object representations (Berson, 1983). A growing number of reports strongly suggest an etiological association with cerebral dysfunction (Joseph, 1985, 1986a,b). In the seven patients with the Frégoli syndrome studied by Christodoulou (1976), clinical as well as EEG, air- and echoencephalography, and psychometric findings suggested neurological or toxic-metabolic components to the pathogenesis whereas Joseph (1985, 1986b) described three patients with paranoid schizophrenia, each of whom not only exhibited the Frégoli syndrome but other varieties of delusional misidentification as well as evidence of cerebral dysfunction.

These syndromes are characterized by defective integration of the normally fused functions of perception

¹ Arnold Lodge, Towers Hospital, Gipsy Lane, Humberstone, Leicester LE5 0TD, United Kingdom. Send reprint requests to Dr. de Pauw.

² Department of Psychiatry, Bassetlaw District General Hospital, Worksop, Nottinghamshire, S81 0BD.

³ Present address: Northern General Hospital, Sheffield.

This work was supported by the Bassetlaw Health Authority Trust Fund. The authors are grateful to Mr. P. Pratt for the psychometric assessment and Dr. Roger Causon for the MAO assay. We thank Professor G. N. Christodoulou and Professor W. J. de Pauw for their assistance in obtaining and translating the original French text.

and recognition, but unless specifically investigated for, responsible or contributory cerebral or toxic-metabolic disorders may go undetected on routine clinical examination. We present a case of the Frégoli syndrome that illustrates the interplay of the multiplicity of psychosocial, personality, and neurological factors that contribute to the etiology of these colorful neuropsychiatric disorders. It also demonstrates the necessity to entertain the possibility of neurological or toxic-metabolic disorders in patients who present with an unusual psychosis, particularly late in their life.

Case Report

Mrs. C., a 66-year-old, right-handed widow, presented as a psychiatric outpatient in March 1985. She was nearly 1 hour late for her appointment, because she had to make a complicated detour around the town and hospital in order to lose her pursuers. Four months earlier she had become convinced that her married cousin had moved into her neighborhood with a lady friend and that they were following her in disguise. They did so because they realized that she was the only member of the family who knew of their affair and criminal activities, *i.e.*, dealing in stolen goods and cars, and that she would report them.

She vividly described, often in minute detail, how the couple disguised themselves with makeup, wigs, dark glasses, false beards, and different clothes. The woman always wore expensive, fashionable outfits, of a sort that the patient had never been able to afford herself. They changed cars or had the same car resprayed in order to follow her, sometimes using two vehicles at a time to head her off. She even accused a local car dealer of helping them. On occasions she confronted strangers in public, demanding that they reveal their true identity. She took complicated routes on her way home to shake them off and reported their activities to the local police. During the day she kept her curtains drawn while opening them at night to keep an eye on them outside her house. She explained that she was able to recognize her cousin and his friend, who sometimes dressed as a man, by certain characteristics, *e.g.*, their gait and voices and the way they held their heads. "They keep changing their clothes and their hairstyles but I know it's them. He can look like an old man. They want a medal for doing it well. It's like an actor and actress [*sic*] preparing for different scenes." She acknowledged that other people, including members of her family, were unable to spot these subtle clues to the real identities of the various men and women she saw in her neighborhood.

Mrs. C. was born in a miner's family of six children. Her education was incomplete due to rheumatic fever and she was mainly employed as a domestic helper.

Her marriage at the age of 24 to a workshy, alcoholic man ended in divorce after 8 years. Three years later her only child, a daughter, was born out of a love affair and brought up by the patient's sister. Mrs. C. continued to meet the father, even after he had married someone else, over a period of 20 years. The relationship ended under unknown circumstances about 10 years before her current presentation. It subsequently transpired that he was in fact the above-mentioned cousin.

Previously Mrs. C. had received psychiatric treatment as an outpatient for anxiety and depression on four occasions between 1955 and 1983. One episode, 2 months after a hysterectomy at the age of 47, was marked by resentment because of her daughter's affection toward her foster parents, a preoccupation with her married lover, and nightmares concerning her late husband. Her premorbid personality was described as secretive, easily angered, often relating the behavior of others to herself, and although not able to sustain solitary activities for long, a poor social mixer. She had no family history of psychiatric disorder.

Her medical history included rheumatic fever at the age of 10, treatment for eczema, gout, and an amblyopic eye, a hysterectomy, and a hematoma over the left frontal area after a fall in 1982. In November 1983 she complained of severe headaches, her speech became slurred, and she lost her sense of direction. She was treated for hypertension (blood pressure 190/90) with atenolol 100 mg and bumetanide (with potassium chloride) 0.5 mg daily. She subsequently developed dizziness, blurred vision, and a right-sided headache, diagnosed as right-sided temporal arteritis, for which she received a course of prednisolone 5 mg *t.i.d.* In September 1984 she complained of spots before her eyes and pain over the vertex and back of her head. Her blood pressure was 200/100 and bendrofluazide 5 mg daily was added to her antihypertensive medication. Two months later Mrs. C. suffered a second cerebrovascular attack. Her speech was slurred and her memory and orientation in time and space impaired. Her cognitive deficits remitted completely, but during the following month she developed the delusional beliefs described above.

Physical examination was unremarkable apart from a blood pressure of 170/90. Investigations revealed normal biochemistry, hematology, and skull x-ray. Venereal Disease Research Laboratories, *Treponema pallidum* hemagglutination, and autoimmunity tests (rheumatoid factor, antinuclear factor, double-stranded DNA, mitochondria, smooth muscle) were negative. Her serum and platelet monoamine oxidase activity did not differ from that of an age- and sex-matched control group. An EEG, however, was markedly abnormal, with alternating emphasis throughout

the recording and very prominent rhythmic and sharp discharges, especially over the right and left hemispheres, respectively, suggesting the possibility of epilepsy. Although it revealed considerable improvement, a second EEG recording 8 months later showed excessive background slow activity with rhythmic and sharper elements, particularly in the temporal regions and with an overall right-sided emphasis. CAT scan demonstrated an old right-sided, posterior temporo-parietal infarct associated with moderate general cortical atrophy (Figure 1).

Psychometric testing found Mrs. C. to be in the dull normal range (WAIS 80 to 90), with a verbal-performance discrepancy of 7 points (85 *vs.* 78). Neither the overall WAIS nor the subtest scatter nor the Benton Visual Retention Test revealed any impairment of intellectual function. She scored 27 (of a maximum of 30) on the Mini-Mental State Examination, a test designed to assess selected areas of cognition, including orientation, attention, calculation, recent memory, and reading and writing abilities (Folstein *et al.*, 1975). She gave the incorrect year, her recall was impaired, and she gave her age as 62 years instead of 66. Her score on Warrington's Recognition Memory Test (1984) for unfamiliar faces lay at the seventh percentile for normal subjects of her age.

Mrs. C. was treated with trifluoperazine 15 mg at bedtime for about 3 months. She became free of her delusions and stated that her pursuers had returned to live with their respective spouses. On retest, her Mini-Mental State score was 30 and she gave her age correctly. However, she remained convinced that her experiences had been based in reality and 2 months after discontinuing her medication she relapsed. Her life became dominated by her delusions and she spent her time pursuing or avoiding her cousin and his friend. They began to wear what she initially thought were horrible-looking masks with glaring eyes that were turned in her direction. Later she realized that these were their own faces. She looked into people's windows to discover where they changed their clothes and she interpreted changes at a local waste ground as evidence that her cousin hid stolen goods there that the local milkman distributed on his rounds. Exhausted and in danger of hypothermia from her efforts to catch her cousin and his henchmen red-handed in the early hours of the morning, she had to be readmitted to hospital.

In view of the EEG reports, she was prescribed carbamazepine 800 mg/day for 6 weeks, but with no improvement in her mental state despite a serum level of 36 $\mu\text{mol/l}$. Pimozide, built up to 10 mg/day, resulted in a gradual amelioration of her delusional convictions, but a full recovery was only achieved with the reintroduction of trifluoperazine. At follow-up 1 year

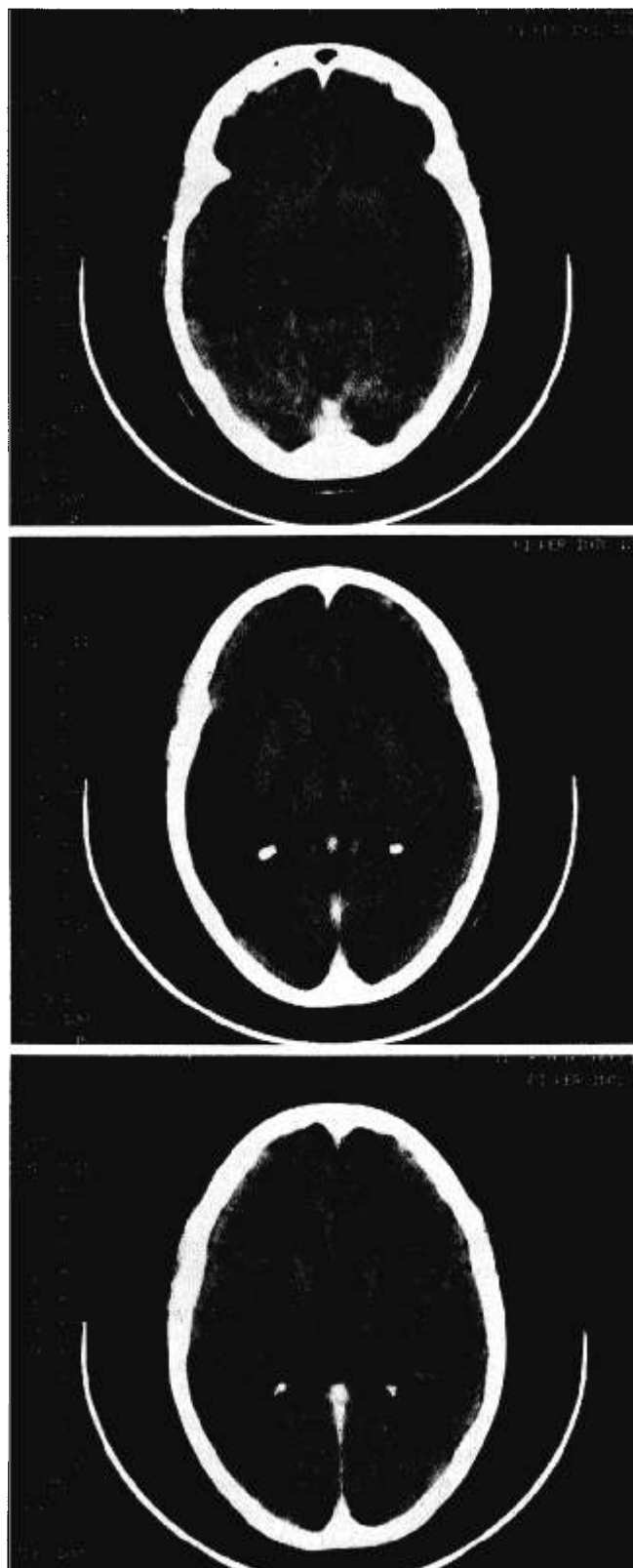


FIG. 1. CAT scan demonstrates low attenuation in the right posterior temporo-parietal area, consistent with an infarct, probably in the posterior temporal branch of the right middle cerebral artery. There is also a moderate degree of cortical atrophy (the right side of the head is on the left side of the scan).

later she was free of delusions but was troubled by tardive dyskinesia in the form of a persistent grinding of her teeth, despite a reduction of medication to 2 mg/day.

Discussion

Although the Frégoli syndrome is usually described in a setting of primary or secondary schizophrenia, our patient showed none of the characteristic symptoms, including thought disorder, bizarre delusions, prominent hallucinations, or marked affective deterioration. Her major symptom was a coherent delusional belief, which, although unusual in its content, was nevertheless closer to consensual reality than the delusions commonly held in schizophrenia. Therefore a diagnosis of paranoia or delusional disorder, secondary to predominantly right hemisphere pathology, would seem more appropriate.

Initial reports of reduced platelet monoamine oxidase activity in patients with delusional misidentification that suggested a common biochemical disorder underlying these syndromes (Barton *et al.*, 1980; Sullivan *et al.*, 1978) were not supported by our findings or by those of Alevizos and Christodoulou (1985). Finding that cortical atrophy rather than location or size of the lesion determined the presence of delusions in patients with right cerebral infarction, Levine and Grek (1984) speculated that such psychopathology depended on the interaction between a focal lesion and more diffuse brain atrophy. Our EEG and CAT investigations demonstrated bilateral cerebral pathology, predominantly affecting the right temporoparietal lobes. In a review of 21 cases of delusional misidentification with cerebral dysrhythmia, Christodoulou and Malliara-Loulakaki (1981) reported that bilateral paroxysmal bursts of slow waves were most commonly observed in the temporal areas. Noting similar results in his series, as well as a lack of lateralizing abnormalities on CAT scanning, Joseph (1986a) has argued in favor of bitemporal dysfunction as the minimal required lesion for the occurrence of these disorders. Other findings, however, raise the possibility that nondominant pathology alone may be sufficient to cause delusional misidentification (Stanton *et al.*, 1982; Wilcox and Waziri, 1983). The marked verbal-performance discrepancy on psychometric testing reported in previous cases that may also reflect underlying nondominant cerebral pathology (Kokkevi and Christodoulou, 1985) was absent in our patient. However, the results of Warrington's Recognition Memory Test (1984) did indicate a selective deficit of recognition memory for unfamiliar faces, an area of skills localized in the nondominant hemisphere.

A parallel can be drawn between the Frégoli syn-

drome and environmental reduplication, wherein the patient locates an unfamiliar environment near or in a familiar one. Indeed, several authors have reported the delusional misidentification of person and place occurring in the same patient (de Pauw and Szulecka, *in press*; Joseph, 1985, 1986b; Ruff and Volpe, 1981). Whereas bilateral cerebral lesions are necessary to cause prosopagnosia, the inability to recognize familiar faces (Damasio, 1985), impaired discrimination of unfamiliar faces is preferentially associated with damage to the nondominant hemisphere (Hamsher *et al.*, 1979; Warrington, 1984). Further support for the crucial role played by the nondominant hemisphere in delusional misidentification is provided by a report of the differential response to electroconvulsive therapy of a case of the Frégoli syndrome in a manic setting. The underlying affective disorder remitted after a course administered to the dominant hemisphere, but the Frégoli syndrome required bilateral ECT to resolve (Triccas *et al.*, 1985).

Merrin and Silberfarb (1976) noted the frequency with which depersonalization-derealization and false memories of familiarity occur in delusional misidentification. The assertions of some patients, ours included, that their persecutors wear various disguises, *e.g.*, masks, may therefore stem from such a state of derealization. If, as Todd *et al.* (1981) have speculated, the symptom of *jamais vu*, as a variant of derealization, facilitates the development of some cases of the Capgras syndrome, the Frégoli type may result from a delusional elaboration of an initial state of *déjà vu*. However, by itself, this would not suffice to explain the development of such delusions, because patients usually retain insight into the nature of this experience.

Clinical and EEG findings suggest that an epileptic discharge, interrupting nondominant cerebral activity, often precedes the acute onset of delayed psychosis after a temporoparietal insult (Levine and Finklestein, 1982). During the period of transient confusion or amnesia, percepts, whether consciously perceived or not, may be incorrectly integrated with relevant past experiences and memories (Price and Mesulam, 1985; Stanton *et al.*, 1982). From this initial state, delusional misidentification may evolve, facilitated by derealization phenomena, premorbid suspiciousness, wish fulfillment, or concurrent psychopathology or as a means of vicariously expressing intense emotions. The kindling effect of paroxysmal neuronal discharges may produce new, fortuitous connections, establishing complex and pervasive behavioral changes (McKenna *et al.*, 1985; Mesulam, 1981). Thus consolidated, the images portrayed as reality in a patient's mind by aberrant neuronal activity would account not only for the tenacity with which some of the delusional beliefs

are held, but for their individual psychopathological coloring as well. The individual's subsequent emotional and behavioral responses would depend on the extent and locality of any additional cerebral lesions, which may leave him or her apathetic, seemingly unconcerned due to an inability to convey feelings through prosody, or incapable of acting consistently on these beliefs.

The course and prognosis of any particular variant of delusional misidentification seem closely related to the resolution or effective treatment of the underlying condition in which setting it developed (Christodoulou, 1978). In some cases, however, it remits more slowly than or even achieves autonomy from the primary condition, which may itself resolve completely. Similarly to several of Christodoulou's cases, our patient's relapse manifested itself by a reappearance of her original delusions. Reviewing the physical treatment of 20 patients with delusional misidentification, Christodoulou (1977) noted partial or complete remissions of those with the Frégoli syndrome in response to electroconvulsive therapy, haloperidol, or trifluoperazine. Carbamazepine, an anticonvulsant particularly effective in temporal lobe epilepsy, selectively inhibits kindled limbic system activity and shows increasing evidence of therapeutic efficacy in atypical psychosis (McKenna *et al.*, 1985). In view of the EEG abnormalities noted in some patients with delusional misidentification, it is not surprising that it has proved useful in the treatment of individual cases (Bick, 1984; Chawla and Virmani, 1977). Pimozide, a diphenylbutylpiperidine neuroleptic, has been reported as particularly effective in various subtypes of paranoia, even when an element of cerebral dysfunction is present (Munro, 1982), but ours seems to be the first description of its use in a delusional misidentification.

MacCallum (1985) has conceptualized delusional misidentification in terms of the damaged patient's desperate attempts to make sense of and reduce his or her fears in a world perceived as disturbed, perhaps by escaping into what might appear as a delusion. Whereas cerebral dysfunction is predominant in some cases, in others it determines the particular symptomatology of the underlying disorder, changing the emphasis from other aspects of schizophrenia or affective disorders towards delusional misidentification. From several accounts it would appear that neither cerebral dysfunction in general nor a preexisting psychosis alone are sufficient to account for delusional misidentification, but that both are necessary to produce these symptoms. However, there are also reports of cases like ours with no prior history of psychosis in which delusional misidentification developed only after the patient had suffered a cerebral insult (Ruff and Volpe, 1981; Staton *et al.*, 1982). We would therefore argue

that delusional misidentification syndromes be conceptualized as neuropsychiatric disorders involving the behavioral expression of an acquired integrative defect, *i.e.*, disordered recognition, often in the presence of a primary (idiopathic) or secondary (symptomatic) psychopathological condition, *e.g.*, schizophrenia, paranoia, or an affective illness. Such an approach rather than the traditional dynamic/organic dichotomy should lead to a more fruitful clarification of the psychosocial and neurological correlates of behavioral disorders as well as the link between primary and secondary psychiatric conditions.

References

- Alevizos B, Christodoulou GN (1985) MAO activity in patients with delusional misidentifications. In P Pichot, P Berner, R Wolf, *et al* (Eds), *Psychiatry: The state of the art* (Vol 1, pp 851-855). New York: Plenum.
- Barton JL, Chaparala S, Barton ES, *et al* (1980) Delusional misidentification and platelet monoamine oxidase. *Biol. Psychiatry* 15:275-282.
- Berson RJ (1983) Capgras' syndrome. *Am J Psychiatry* 140:969-978.
- Bick PA (1984) The syndrome of intermetamorphosis. *Am J Psychiatry* 141:588-589.
- Chawla HM, Virmani V (1977) Capgras phenomenon in a case of temporal lobe epilepsy. *Folia Psychiatr Neurol Jpn* 31:615-617.
- Christodoulou GN (1976) Delusional hyper-identification of the Frégoli type. *Acta Psychiatr Scand* 54:305-314.
- Christodoulou GN (1977) Treatment of the "syndrome of doubles." *Acta Psychiatr Belg* 77:254-259.
- Christodoulou GN (1978) Course and prognosis of the syndrome of doubles. *J Nerv Ment Dis* 166:68-72.
- Christodoulou GN, Malliara-Loulakaki S (1981) Delusional misidentification syndromes and cerebral 'dysrhythmia.' *Psychiatr Clin* 14:245-251.
- Courbon P, Fail G (1927) Syndrome d'"illusion de Frégoli" et schizophrénie. *Bull Soc Clin Med Ment* 15:121-125.
- Damasio AR (1985) Prosopagnosia. *Trends Neurosci* 8:132-135.
- de Pauw KW, Szulecka TK (in press) Dangerous delusions: Violence and the misidentification syndromes. *Br J Psychiatry*.
- Folstein MF, Folstein SE, McHugh PR (1975) "Mini-mental state": a practical method for grading the cognitive state of patients for the clinician. *J Psychiatr Res* 12:189-198.
- Hamsher KdeS, Levin HS, Benton AL (1979) Facial recognition in patients with focal brain lesions. *Arch Neurol* 36:837-839.
- Joseph AB (1985) Bitemporal atrophy in a patient with Frégoli syndrome, syndrome of intermetamorphosis, and reduplicative paramnesia. *Am J Psychiatry* 142:146-147.
- Joseph AB (1986a) Focal central nervous system abnormalities in patients with misidentification syndromes. *Bibl Psychiatr* 164:68-79.
- Joseph AB (1986b) Capgras syndrome. *Br J Psychiatry* 148:749-750.
- Kokkevi A, Christodoulou GN (1985) Psychometric investigation of patients with delusional misidentification syndromes. In P Pichot, P Berner, R Wolf, *et al* (Eds), *Psychiatry: The state of the art* (Vol 1, pp 841-849). New York: Plenum.
- Levine DN, Finklestein S (1982) Delayed psychosis after right temporoparietal stroke or trauma: relation to epilepsy. *Neurology* 32:267-273.
- Levine DN, Grek A (1984) The anatomic basis of delusions after right cerebral infarction. *Neurology* 34:577-582.
- MacCallum WAG (1985) An expanded Capgras syndrome. In P Pichot, P Berner, R Wolf, *et al* (Eds), *Psychiatry: The state of the art* (Vol 1, pp 831-840). New York: Plenum.
- McKenna PJ, Kane JM, Parrish K (1985) Psychotic syndromes in epilepsy. *Am J Psychiatry* 142:895-904.

- Merrin EL, Silberfarb PM (1976) The Capgras phenomenon. *Arch Gen Psychiatry* 33:965-968.
- Mesulam M-M (1981) Dissociative states with abnormal temporal lobe EEG, multiple personality and the illusion of possession. *Arch Neurol* 38:176-181.
- Munro A (1982) Paranoia revisited. *Br J Psychiatry* 141:344-349.
- Price BH, Mesulam M-M (1985) Psychiatric manifestations of right hemisphere infarctions. *J Nerv Ment Dis* 173:610-614.
- Ruff RL, Volpe BT (1981) Environmental reduplication associated with right frontal and parietal lobe injury. *J Neurol Neurosurg Psychiatry* 44:382-386.
- Staton RD, Brumback RA, Wilson H (1982) Reduplicative paramnesia: A disconnection syndrome of memory. *Cortex* 18:23-35.
- Sullivan J, Cavenar JO, Maltbie AA, *et al* (1978) Capgras syndrome: A biochemical marker? *J Nerv Ment Dis* 166:275-279.
- Todd J, Dewhurst K, Wallis G (1981) The syndrome of Capgras. *Br J Psychiatry* 139:319-327.
- Triccas GM, Karkanas AP, Christodoulou GN (1985) Frégoli syndrome in a manic setting. In P Pichot, P Berner, R Wolf, *et al* (Eds), *Psychiatry: The state of the art* (Vol 1, pp 825-829). New York: Plenum.
- Warrington EK (1984) *Recognition Memory Test*. Windsor: NFER-Nelson.
- Wilcox J, Waziri R (1983) The Capgras syndrome and non-dominant cerebral dysfunction. *J Clin Psychiatry* 44:70-72.