

Peduncular Hallucinosi:s Magnetic Resonance Imaging Confirmation of Mesencephalic Infarction During Life

Thomas J. Geller, MD,* and Srinath N. Bellur, MD†

We describe a patient with peduncular hallucinosi:s and a mesencephalic infarct; the infarct was diagnosed during life by magnetic resonance imaging.

Geller TJ, Bellur SN: Peduncular hallucinosi:s magnetic resonance imaging confirmation of mesencephalic infarction during life. *Ann Neurol* 21:602-604, 1987

The occurrence of acute visual hallucinosi:s does not generally aid in localizing the site of central nervous system dysfunction except in the instance of peduncular hallucinosi:s. Peduncular hallucinosi:s is characterized by vivid, nonstereotypical, colorful imagery that is nonthreatening to the patient. The hallucinations occur in the presence of mesencephalic dysfunction. Well-documented cases are few, and most of these have included autopsy findings. We report a case of peduncular hallucinosi:s in which the anatomical diagnosis was confirmed *during life* by magnetic resonance imaging (MRI).

Case Report

A 61-year-old man with insulin-dependent diabetes mellitus and atherosclerotic cardiovascular disease was admitted to the West Side Veterans' Hospital, Chicago, with a 1-day history of inability to open his right eye and clumsiness and weakness of the left side of his body. During this time his family noticed that he was drowsy and his speech was slurred. They also noted that the patient spoke of visual images that were clearly hallucinatory.

When questioned, the patient described seeing images of cats running about the floor, flowery outdoor scenes in bright purple colors, and the faces of neighbors and friends. These images appeared continuously in all areas of the visual fields and lasted for minutes to hours. The patient was aware that the visual images were not real and was not apprehensive about them.

From the *Department of Neurology, University of Illinois at Chicago, and the †Neurology Service, West Side Veterans' Administration Hospital, Chicago, IL.

Received July 28, 1986, and in revised form Oct 7. Accepted for publication Oct 10, 1986.

Address correspondence to Dr Geller, Department of Neurology, University of Illinois at Chicago, 912 S Wood St, Chicago, IL 60612.

He had had diabetes for the past 21 years, and diabetic retinopathy in the right eye had been treated by laser therapy. The patient had had two previous "silent" myocardial infarctions and had had his left great toe amputated because of severe peripheral vascular disease. The patient had no prior history of stroke.

General physical findings were unremarkable except for the healing amputation site on his left foot. On neurological examination, the patient was found to be mildly somnolent and time-disoriented, but his language functions were intact. His visual acuity was 20/40 in the left eye and he could see only hand movements in the right. His visual acuity was unchanged from a previous examination 18 months before. The patient had bilateral ptosis, but it was much more evident on the right. Also noted were a complete right third-nerve paralysis with absent pupillary light response, a left central seventh-nerve palsy, and a left hemiparesis. Occasional opsoclonic eye movements were seen, along with asterixis in the upper extremities, which was more pronounced on the left.

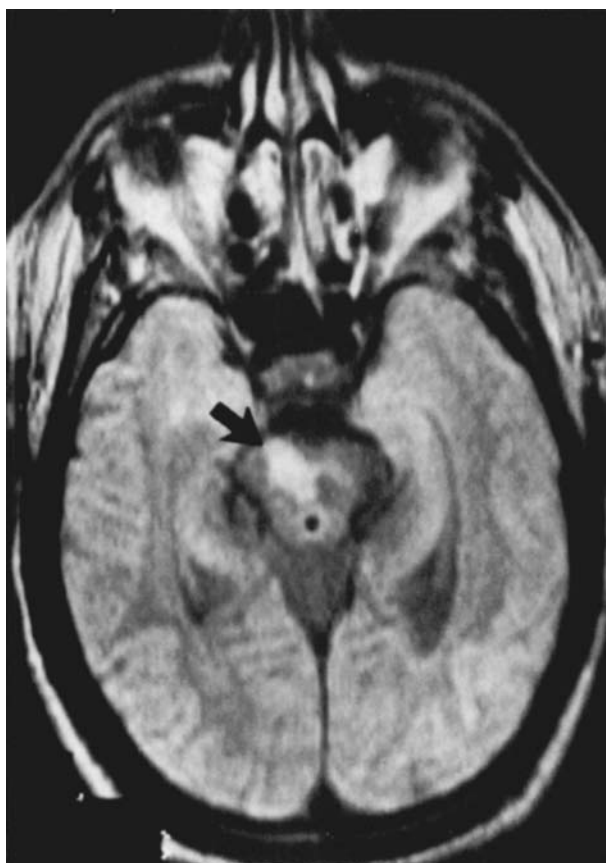
Computed tomographic (CT) brain scan failed to demonstrate clearly any brainstem abnormalities. An MRI scan using a 0.3-Tesla source demonstrated an area of hyperdense signal intensity on the T₂-weighted phase in the right midbrain tegmentum and cerebral peduncle, most consistent with a bland infarction in the distribution of one of the small mesencephalic branches of the posterior cerebral or superior cerebellar arteries (Figure).

The patient's somnolence and hallucinations slowly resolved over an approximate 10-day period, and he was left with mild right ptosis and left hemiparesis.

Discussion

Peduncular hallucinosi:s is an unusual but well-described phenomenon that has been noted in vascular lesions involving the cerebral peduncles or adjacent midbrain structures. The earliest postmortem studies of this disorder were published by Lhermitte and associates [10] and van Bogaert [12]. The hallucinations usually appear as isolated vivid visual images, often in bright colors, which do not invoke fear in the patient. In fact, the patient is usually amused by the imagery and is aware of the "unreality" of the phenomenon [11]. Our patient's hallucinations were consistent with this pattern.

A number of explanations have been proposed for the origin of visual hallucinations in vascular lesions that are so distant from the visual system. None to date seems entirely satisfactory. Cogan's theory of visual hallucinations posits two separate mechanisms of hallucinogenesis: "irritation" and "release" [4]. In the irritative type, stereotypical paroxysmal disturbances in cortical function occur, sometimes associated with other dysfunction in the motor or sensory realms. It is believed that, when the irritative focus is occipital, brief stereotypical flashes of light or color are described by the subject. When the focus is in the temporal lobe, the subject reports complex stereotypical formed images.



Axial view of midbrain structures using magnetic resonance imaging. Arrow indicates area of hyperdense signal intensity in the right midbrain tegmentum and cerebral peduncle. (R = right.)

The release type of visual hallucinosis is characterized by more continuous visual images that change from one episode to the next, but it is not characterized by an association with any other motor or sensory disturbance. The hallucinations are attributed to a loss of normal visual input occurring as a consequence of a lesion anywhere in the visual system or as a consequence of sensory deprivation. Generally, release hallucinations are therefore less valuable in localizing central nervous system lesions. One exception, however, is the phenomenon of peduncular hallucinosis. When peduncular hallucinosis occurs, it is associated with other signs of midbrain dysfunction, as in our patient.

Although midbrain infarction is common, peduncular hallucinosis is rare. It is tempting to speculate that visual system dysfunction, coexisting with midbrain reticular formation dysfunction, precipitates peduncular hallucinations. Our patient had a preexisting visual dysfunction (functional blindness, left eye; visual acuity, 20/40, right eye) prior to his midbrain infarction. A review of 10 previously published confirmed cases of peduncular hallucinosis reveals that there was definite

visual system dysfunction in only 3 [2, 7, 8]. In 4 cases there was no comment or uncertain evidence of visual impairment [1, 9, 12], and in 3 cases visual acuity and visual fields were entirely normal [5, 6, 11]. The exact mechanism involved in the occurrence of peduncular hallucinosis is therefore unclear, but the continuous and nonstereotypical nature of the phenomenon suggests a release mechanism.

Peduncular hallucinations are described in association with hemorrhagic or thrombotic midbrain stroke [3, 4, 7, 9]. A report of peduncular hallucinosis with angiographically diagnosed hypoplasia of the vertebral artery was published in the Italian literature [3]. Similarly, the phenomenon was described as a complication of vertebral angiography by Rozanski in 1952 [11]. A single report of an extraaxial compressive lesion of the midbrain with surgically reversible peduncular hallucinosis appears in an article by Dunn and colleagues [7]. However, to our knowledge, this is the first clinicoradiological documentation (using MRI) of a mesencephalic infarct during life in a case of peduncular hallucinosis.

Even though formed visual hallucinations do not generally have a strong localizing value, any overt or subtle signs of a brainstem disorder should be carefully sought in patients with acute formed visual hallucinations. Radiological confirmation of the brainstem disorder in peduncular hallucinations can be better accomplished by MRI than by CT studies.

We would like to thank Nona C. Flores, PhD, for her editorial assistance in the preparation of this article.

References

1. Alajouanine T: Lésion protrubérantielle basse d'origine vasculaire et hallucinose. *Rev Neurol (Paris)* 76:90-91, 1944
2. Alajouanine T, Copcevitch M: Hallucinose, préhypnique, automatisme ambulateur et verbal nocturne, éclipses confusionnelles paroxystiques chez une malade atteinte d'un syndrome parkinsonien postencephalitique, avec syndrome de Parinaud respectant les mouvements automatico-reflexes, et crises toniques des membres à type de crampes vespérales. *Rev Neurol (Paris)* 50:714-718, 1928
3. Bossi L, Nobili M, Benedetto P: [Peduncular hallucinosis in a young woman with vertebrobasilar insufficiency.] *Arch Sci Med (Torino)* 137:347-350, 1980
4. Cogan DG: Visual hallucinations as release phenomena. Albrecht Von Graefes *Arch Klin Exp Ophthalmol* 188:139-150, 1973
5. DeMorsier G: Pathogenie de l'hallucinose pedonculaire. *Rev Neurol* 64:606, 1935
6. DeMorsier G: Pathogenie de l'hallucinose pedonculaire: à propos d'un nouveau cas. *Schweiz Med Wochenschr* 66:645, 1936
7. Dunn DW, Weisberg LA, Nadell J: Peduncular hallucinations caused by brainstem compression. *Neurology* 33:1360-1361, 1983
8. Lhermitte J: Les fondements anatomo-physiologiques de certaines hallucinations visuelles. *Conférence Neurologique* 9:43-57, 1949

9. Lhermitte J, Bineau R: Les hallucinations visuelles consecutives aux lésions pedonculaires en foyer. *Rev Neurol (Paris)* 68:827, 1937
10. Lhermitte J, Levy G, Trelles J: L'hallucinosse pedonculaire (étude anatomique d'un cas). *Rev Neurol (Paris)* 1:382, 1932
11. Rozanski J: Peduncular hallucinosis following vertebral angiography. *Neurology* 2:341-349, 1952
12. van Bogaert L: L'hallucinosse pedonculaire. *Rev Neurol (Paris)* 47:608-617, 1927

No Sex-Related Differences in Human Corpus Callosum Based on Magnetic Resonance Imagery

Jeffrey S. Oppenheim, AB, Benjamin C. P. Lee, MD, Ruth Nass, MD, and Michael S. Gazzaniga, PhD

Recent studies have reported sex-related differences in the morphology of the human corpus callosum in cadaver brains. To further investigate these reports, sagittal magnetic resonance image scans from 40 male and 40 female subjects were used to compare callosal morphology. Relative callosal measurements were calculated by morphometric analysis. Significant sex-related differences were not found for callosal areas, maximal callosal width, or callosal curvature. These results indicate the need for further study before claims of sex-related differences can be accepted.

Oppenheim JS, Lee BCP, Nass R, Gazzaniga MS:
No sex-related differences in human corpus callosum based on magnetic resonance imagery.
Ann Neurol 21:604-606, 1987

Neuropsychological studies suggest that males show greater cerebral lateralization of language and spatial skills, whereas females evidence greater bilateralization of function, particularly for language [1]. Sex-related anatomical differences between the cerebral hemi-

From the Division of Cognitive Neuroscience, Department of Neuroscience, Cornell University Medical College, New York, NY.

Address correspondence to Dr Gazzaniga, Division of Cognitive Neuroscience, Cornell University Medical College, 525 E 68th St, New York, NY 10021.

Received Aug 29, 1986, and in revised form Oct 27. Accepted for publication Oct 28, 1986.

spheres have also been reported. Wada and associates [8] found that the left planum temporale—a brain region closely associated with language skills [2]—is likely to be larger in adult men than in adult women.

Recent interest has focused on morphological sex-related differences of the corpus callosum. deLacoste-Utamsing and Holloway [6] reported greater splenial width and area (the posterior fifth of the callosum), but not greater callosal length, in 5 female versus 9 male cadaver brains. In addition, the total cross-sectional area, although indistinguishable as an absolute value, was larger in the females when calculated relative to brain weight.

Witelson [9], who examined 12 male and 21 female cadaver brains, found no sex-related difference in callosal or splenial areas. Consistent with the previous finding [6], however, females had a larger callosal area only when calculated relative to brain weight. Witelson also reported that ambidextrous subjects had a slightly larger callosal area than those who were right-handed (0.75 cm²), but this difference was unrelated to sex.

deLacoste-Utamsing and Holloway [6] defined the splenium by dividing the maximal callosal length into fifths and calculating the area of the most posterior fifth. They argued that the female splenium is more bulbous, but offer no quantitative evidence. Alternatively, a larger splenium might be observed if the callosum had a greater curvature. Since the area subtended by an arc increases with the curvature of the arc, a callosum with a greater curvature should be subtended by a larger area.

The poor replication and uncertain interpretation of these earlier studies indicated the need for a larger study. Magnetic resonance imagery (MRI) offers the advantage of an *in vivo* analysis on a larger number of subjects. In this study, MRI was used to examine callosal morphology for several sex-related differences.

Method

The sagittal images evaluated were produced by a 0.5-T Teslacon MRI system at the Cornell University Medical Center (see [5]). The subjects, 40 men and 40 women, were patients at the New York Hospital-Cornell Medical Center, and were suffering from diseases that did not involve either the cerebral hemispheres or the corpus callosum. The MR images had a nominal in-phase resolution of 1.0 × 1.3 mm, enabling detailed observation of callosal morphology.

Tracings of the MR images were enlarged, and morphometric area measurements were made using a Zeiss MOP-3 X;Y image digitizer. The methods of measurement previously employed [6, 9] were not accurately described; however, a similar method was estimated. Measured areas were determined as follows (Figure). A straight line (line A) was drawn through the most inferior borders of the splenium and rostrum. From this line, perpendicular lines were drawn