

Abnormal Cerebral Cortical Neurons in a Child With Maternal PKU Syndrome

Daniel J. Lacey, MD, PhD; Kornel Terplan, MD

Abstract

A child born to a phenylketonuric (PKU) woman not on dietary treatment was microcephalic and had congenital heart and other physical anomalies consistent with the maternal PKU syndrome. After a repeat cardiac catheterization at 3 months of age, he suffered an embolic left cerebral infarct and seizures. He was found by his mother dead in bed at 4 months of age; general autopsy revealed *Klebsiella* sepsis and pneumonia. Neuropathologic studies of the right cerebral hemisphere showed neuronal loss of the third cortical layer; Golgi studies revealed persistently immature cortical pyramidal cell somata and dendritic spines. This is the first report of specific neuronal abnormalities in a child with the maternal PKU syndrome and may, in part, account for the clinical features of microcephaly, mental retardation, and seizures seen in affected children. (*J Child Neurol* 1987;2:201-204).

Children born to phenylketonuric (PKU) mothers not on dietary restriction of phenylalanine during pregnancy have a high incidence of microcephaly, mental retardation, and congenital anomalies.¹⁻⁴ These children have not inherited the metabolic disease but express manifestations of the teratogenicity of maternal hyperphenylalaninemia, the incidence and spectrum of which relate to maternal phenylalanine levels early in gestation. Because more PKU women are having children, terminating their diet prior to conception, neurodevelopmental concerns regarding the maternal PKU child are becoming more frequently expressed.⁵

To date, pathologic reports⁶ of the brains of these children have consisted of only scattered case reports (Gilles, personal communication). Similar to the findings reported in brains of human PKU patients processed by conventional histologic methods, little has been found (ie, delayed myelination) that would correspond to the clinical features of maternal PKU.

Applications of the Golgi methods to the brains of PKU patients,⁷ and in animal models of PKU,⁸⁻¹² have shown alterations of neuronal and dendritic architecture that may account for the retardation and seizures. We have recently studied the brain of a 4-month-old child with the maternal PKU syndrome, using routine and Golgi histologic techniques.

Case Report

A male infant was born to a 25-year-old PKU woman who was off her diet for many years until the pregnancy was confirmed in the sixth week. She was then placed on a phenylalanine-restricted diet, but serum phenylalanine levels were not measured throughout her pregnancy. (Details regarding maternal history were not available to the authors.) Delivery was at 36 weeks, birth weight was 2,900 g, and Apgar scores were 9/9. On the third day, "dusky spells" were noticed when the child became agitated, and an echocardiogram diagnosed a single ventricle. A cardiac catheterization at our hospital at 7 days of life revealed a single ventricle, *truncus arteriosus*, and total anomalous pulmonary venous return; oxygenation was normal. Neurologic exam was significant by the presence of microcephaly; head circumference was 31.3 cm. After being discharged on digoxin, and with an interval history of poor feeding and "blue spells" when crying, a repeat cardiac

Received May 20, 1986, Received revised Sept 2, 1986.
Accepted for publication Sept 11, 1986.

From the departments of Neurology and Pediatrics, State University of New York at Buffalo, and the Brain Laboratory, Children's Hospital of Buffalo, Buffalo, NY.

Address correspondence to Daniel J. Lacey, MD, PhD, Department of Neurology, Children's Medical Center, One Children's Plaza, Dayton, OH 45404.

catheterization was performed at 3 months of life. Results were identical to those detailed above, with normal oxygen saturations. Within 2 hours of the procedure, right focal seizures occurred, which were stopped by intravenous phenobarbital. An immediate computed tomographic (CT) scan was normal, but a scan 4 days later showed a large infarct of the left parietal lobe. No further seizures were noted, and the child was discharged on phenobarbital and digoxin. One month later, at age 4 months, his mother found him dead in bed in the early morning.

General autopsy was performed 8 hours later. External examination revealed microsomia with microcephaly, micrognathia, left hydrocele, and a right undescended testicle. Additional diagnoses included complex congenital heart disease, passive congestion of the liver, *Klebsiella* septicemia and bronchopneumonia, pneumoperitoneum, and left parietal brain softening.

Neuropathologic Methods and Results

Brain weight was 540 g (expected 620 g) with normal development. No visible brain swelling or herniation was present. As mentioned above, left parietal brain softening and a slightly yellowish discoloration were evident. Fresh blocks were taken from the right frontal cortex, right occipital cortex, right hippocampus, basal ganglia, midbrain, pons, medulla, and spinal cord. These were embedded in celloidin and stained by Nissl, H & E, and Weil-Weigert methods. Blocks were also obtained from the right middle frontal gyrus, hippocampus, and cerebellum for Golgi-Cox and rapid Golgi methods. All blocks were sectioned coronally (celloidin-embedded material at 20 μm and Golgi blocks at 90 μm). These slides were compared to those of comparable areas from a normal 4-month-old infant who was a crib death and a 5-month-old who had similar congenital cardiac anomalies.

The cellular stains showed neuronal loss in the third cortical layer, especially of the central and parieto-occipital gyri. Betz cells in these regions were hypoplastic with only minimal enlargement of their perikarya. No other significant changes were found in any of the other regions examined. Specifically, areas usually affected by chronic hypoxia, ie, hippocampus and cerebellum, were normal. Weil-Weigert myelin stains of brain sections from our patient were qualitatively similar to those from the two control brains. In particular, it was not possible to differentiate blinded slides of the optic chiasm and

tracts of the maternal PKU child from those of the other two infants.

Golgi sections of hippocampus and cerebellum of the child detailed above showed normal pyramidal and Purkinje cells for age. Changes of chronic hypoxia, most notably dendritic spine loss, were not present on hippocampal pyramidal cells of our patient, although spine loss was evident in the other infant with congenital heart disease. Cortical pyramidal cells of the maternal PKU child showed prominent perikaryal spines and dendritic spines that were longer and thinner (ie, immature) than normal for age (see Figures 1 and 2). These findings were not present in brains of the two other infants who served as controls (see Figure 3). The morphological dendritic spine alterations were primarily qualitative; spine counts did not reveal significant differences between controls and the maternal PKU child.

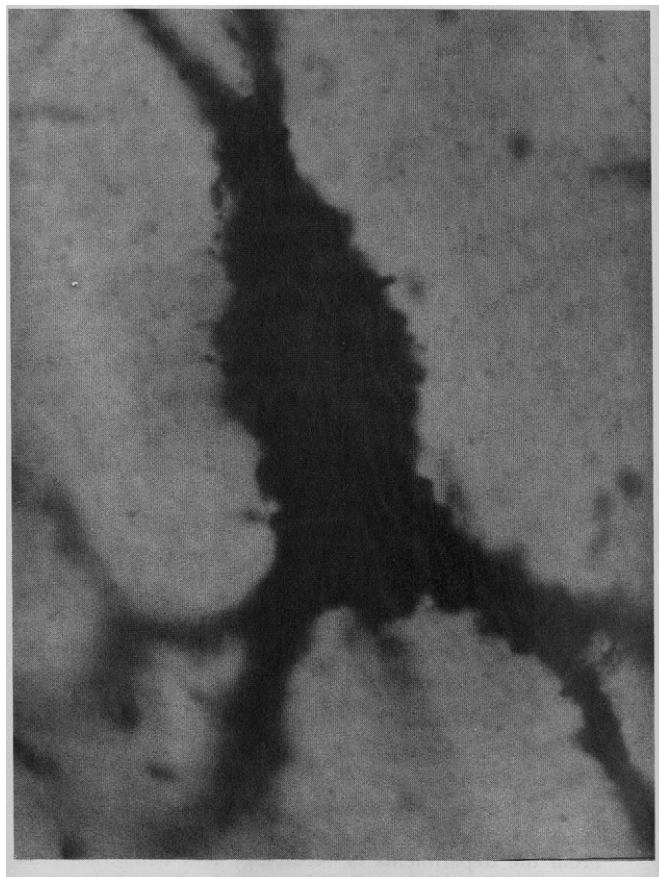


FIGURE 1
Cortical pyramidal cell of maternal PKU child, rapid Golgi stain. Prominent perikaryal spines are present. Magnification $\times 1,000$.

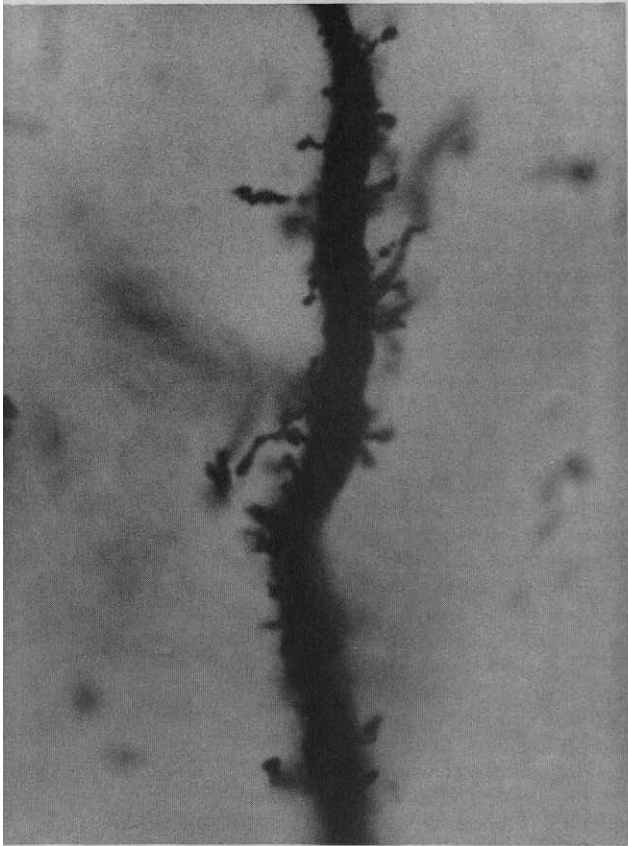


FIGURE 2
Cortical pyramidal cell dendritic shaft of maternal PKU child, rapid Golgi stain. Abnormally long and thin dendritic spines are evident. Magnification $\times 1,000$.

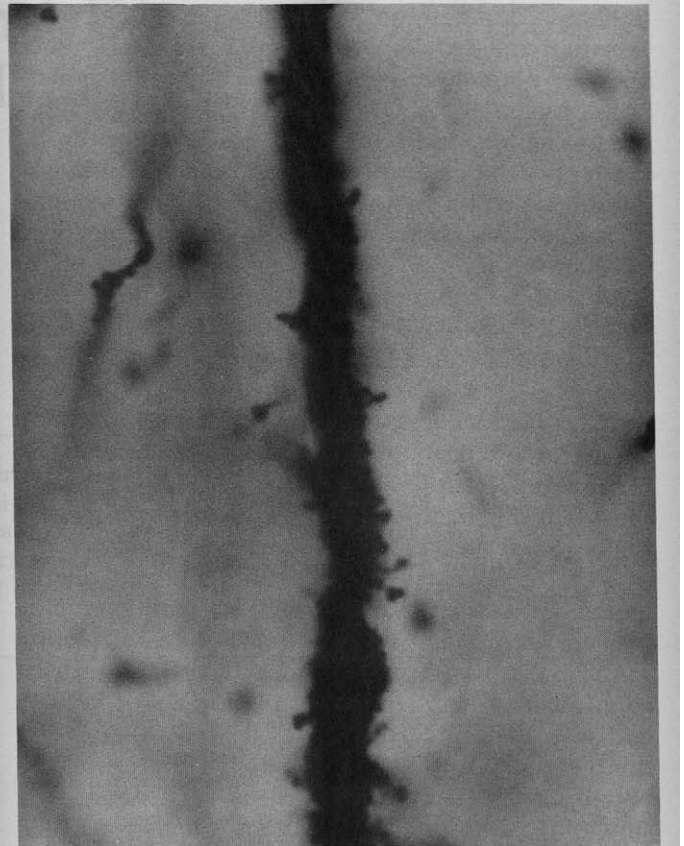


FIGURE 3
Dendritic shaft of cortical pyramidal cell from age-matched infant with congenital heart disease, rapid Golgi stain. Dendritic spines have normal numbers and morphology. Magnification $\times 1,000$.

Discussion

The major findings in the brain of this child with maternal PKU syndrome include neuronal loss in the third cortical layer, normal myelination for age, and cortical pyramidal cells with persistently immature perikaryal and dendritic spines. Because this report details the findings of only one case, and the literature contains only a few isolated postmortem examinations, conclusions regarding the pathologic substrates of the clinical features of the maternal PKU syndrome remain tenuous. Golgi studies in a few patients with PKU have shown reduced cortical synaptic densities, lack of maturation of pyramidal cell dendritic arborization, and reduced numbers of dendritic spines.^{7,13} The hypomyelination reported in human PKU patients was not present in our patient.

Two factors that may bear upon the interpretation of the pathologic data are the interval between death and autopsy, and the possibility of chronic hypoxia in

this child with complex congenital heart disease. Postmortem examination was performed approximately 8 hours after death was discovered. Although this interval clearly did not create difficulty for the gross and routine microscopic analysis of the brain, Golgi staining can be profoundly affected by delays in fixation of 6 hours or more.¹⁴ The autolytic, degenerative neuronal changes in humans consist of shrunken perikarya, beaded dendritic shafts, reduced density of dendritic spines, and incomplete impregnation. Some autolytic changes were found in our Golgi material, but the overall quality of the sections was satisfactory, according to the criteria of Williams et al.¹⁴ Only well-impregnated and stained neurons were studied, and our Golgi results do not mimic those from suboptimally fixed and impregnated human brains.

The possibility of chronic hypoxic-ischemic central nervous system injury affecting our results seems

unlikely. Although the child became dusky or cyanotic when agitated, repeated cardiac catheterizations showed normal oxygenation. Also, routine microscopic examination of the brain did not show evidence of chronic hypoxic-ischemic neuronal injury, eg, to the hippocampus and cerebellum. Finally, although dendritic alterations to the brain in human neonates and infants with hypoxia and ischemia have not been adequately studied, our unreported Golgi observations in these children are not similar to those of the maternal PKU child. Rather, asphyxiated infants have reduced numbers of short, stubby dendritic spines.

The perikaryal spines and long, thin dendritic spines in our patient probably represent delayed maturational changes from fetal to postnatal life.¹⁵ This dendritic maturational arrest has been found in human adult PKU patients and also in animal models of PKU.^{7,11} We have recently reported an animal model of maternal PKU in which pregnant rats were injected with phenylacetate. Brains of their offspring were smaller than controls and had cortical dendritic abnormalities.¹⁶ Cortical pyramidal cells of layer 5 had few dendritic spines which were longer and thinner than controls. Although the findings were not precisely identical to those of our patient, the similarities suggest that an animal model may be useful in the experimental study of neuropathologic correlates of the clinical features of maternal PKU syndrome.

References

1. Lenke RR, Levy HL: Maternal phenylketonuria and hyperphenylalaninemia. An international survey of the outcome of untreated and treated pregnancies. *N Engl J Med* 1980; 303:1202-1208.
2. Lenke RR, Levy HL: Maternal phenylketonuria—Results of dietary therapy. *Am J Obstet Gynecol* 1982;142:548-552.
3. Levy HL, Waisbren SE: Effects of untreated phenylketonuria and hyperphenylalaninemia on the fetus. *N Engl J Med* 1983;309:1269-1274.
4. Lipson A, Buehler B, Bartley J, Walsh D, et al: Maternal hyperphenylalaninemia fetal effects. *J Pediatr* 1984;104:216-220.
5. Committee on Genetics, American Academy of Pediatrics: Maternal phenylketonuria. *Pediatrics* 1985;76:313-314.
6. Smith I, Erdohazi M, Macartney EJ, et al: Fetal damage despite low-phenylalanine diet after conception in a phenylketonuric woman. *Lancet* 1979;1:17-19.
7. Bauman ML, Kemper ThL: Morphologic and histoanatomic observations of the brain in untreated human phenylketonuria. *Acta Neuropathol* 1982;58:55-63.
8. Nigman MP, Yagnik P: The effect of hyperphenylalaninemia on rat neocortex: A Golgi study. *Ann Neurol* 1979;6:183.
9. Wen GY, Wisniewski HM, Shek JW, et al: Neuropathology of phenylacetate poisoning in rats: An experimental model of phenylketonuria. *Ann Neurol* 1980;7:557-566.
10. Robain O, Wen GY, Wisniewski HM, et al: Purkinje cell dendritic development in experimental phenylketonuria. A quantitative analysis. *Acta Neuropathol* 1981;53:107-112.
11. Lacey DJ: Hippocampal dendritic abnormalities in a rat model of phenylketonuria (PKU). *Ann Neurol* 1984;16:577-580.
12. Lacey DJ: Normalization of dendritic spine numbers in rat hippocampus after termination of phenylacetate injections (PKU model). *Brain Res* 1985;329:354-355.
13. Williams RS, Hauser SL, Purpura DP, et al: Autism and mental retardation. Neuropathologic studies performed in four persons with autistic features. *Arch Neurol* 1980;37:749-753.
14. Williams RS, Ferrante RJ, Caviness VS: The Golgi rapid method in clinical neuropathology: The morphologic consequences of suboptimal fixation. *J Neuropathol Exp Neurol* 1978;37:13-33.
15. Purpura DP: Normal and aberrant neuronal development in the cerebral cortex of human fetus and young infant, in Buckwald NA, Brazier, MAB (eds): *Brain Mechanisms in Mental Retardation*. New York, Academic Press, 1975, pp 141-169.
16. Lacey DJ: Cortical dendritic spine loss in rat pups whose mothers were prenatally injected with phenylacetate ("Maternal PKU" model). *Dev Brain Res* 1986;27:283-285.