

Tohoku Journal of Experimental Medicine

Advance Publication by J-STAGE

Received August 23, 2022

Accepted September 12, 2022

J-STAGE Advance publication date: September 23, 2022

DOI: 10.1620/tjem.2022.J079

**Sjögren's Syndrome Presenting with Temporary Hemiplegia Mimicking Transient
Ischemic Attack**

Yukiko Kamogawa,¹ Kanae Akita,¹ Hiroko Sato,¹ Tsuyoshi Shirai,¹ Tomonori

Ishii,² Hideo Harigae³ and Hiroshi Fujii¹

¹Department of Rheumatology, Tohoku University Hospital, Sendai, Miyagi, Japan

²Department of Clinical Research, Innovation and Education Center, Tohoku University Hospital, Sendai,
Miyagi, Japan

³Department of Hematology, Tohoku University Graduate School of Medicine, Sendai, Miyagi, Japan

Correspondence: Hiroshi Fujii M.D., Ph.D., Department of Rheumatology, Tohoku University Hospital, 1-1
Seiryō-machi, Aoba-ku, Sendai, Miyagi 980-8574, Japan.

e-mail: hfujii@med.tohoku.ac.jp

Case report

**Sjögren's syndrome presenting with temporary hemiplegia mimicking transient
ischemic attack**

Short title; Temporary hemiplegia in Sjögren's syndrome

Yukiko Kamogawa¹, Kanae Akita¹, Hiroko Sato¹, Tsuyoshi Shirai¹, Tomonori Ishii,²

Hideo Harigae³, Hiroshi Fujii^{1*}

¹Department of Rheumatology, Tohoku University Hospital, Sendai, Japan

²Department of Clinical Research, Innovation and Education Center, Tohoku University
Hospital, Sendai, Japan

³Department of Hematology, Tohoku University Graduate School of Medicine, Sendai,
Japan

Hiroshi Fujii MD, PhD, on behalf of the authors*

** Corresponding author: Hiroshi Fujii at Department of Rheumatology, Tohoku
University Hospital,
1-1 Seiryomachi, Aoba-ku, Sendai 980-8574, Japan.
Telephone: +81-22-717-7165; Fax: +81-22-717-7497
E-mail: hfujii@med.tohoku.ac.jp*

Abstract

Sjögren's syndrome manifests with a wide variety of neurologic symptoms. This case report presents a 53-year-old woman with Sjögren's syndrome associated with temporal hemiplegia, which was suspected to be a transient ischemic attack. After induction of immunosuppressive therapies (high-dose prednisolone (1mg/kg) and intravenous cyclophosphamide (total 5g)), the hemiplegia did not reappear and the blood flow abnormalities remarkably improved as depicted on electroencephalography and single photon emission computed tomography. This case suggests that temporal hemiplegia presenting with transient ischemia-like attack symptoms may be a neurologic manifestation of Sjögren's syndrome and responsive to immunosuppressive therapy.

Key words: Sjögren's syndrome, immunosuppressive therapy, transient ischemic attack, neurological symptom, extraglandular manifestation

Introduction

Sjögren's syndrome (SS) is a chronic autoimmune disease characterized by destruction of the lacrimal and salivary glands, as a result of lymphocytic infiltration; thus, the primary symptoms of SS are dry eyes and dry mouth. However, SS may also manifest with various extraglandular symptoms, including peripheral and central nervous system (CNS) involvement (Brito-Zeron et al. 2016).

CNS is involved in 2-5% of cases of primary SS (pSS), while peripheral neuropathy in 5–15% of cases of pSS (Alunno et al. 2019). The CNS complications of primary SS (pSS) are rare and manifested by a wide range of simple symptoms, such as meningitis, seizure, cerebral vasculitis, and transverse myelitis (Delalande et al. 2004; Margaretten 2017; Mekinian et al. 2020). Cerebral vasculitis causes arterial stroke, accompanied by abnormalities on MRI (Ferreiro et al. 1987). In contrast, some pSS patients have subjective cognitive difficulties referred to as “brain-fog,” which often precede the diagnosis of pSS (Manzo et al. 2019). These diverse clinical manifestations may lead to delayed diagnosis of SS (Soliotis et al. 2004). The pathophysiology of CNS involvement in pSS is yet to be elucidated, and immunosuppression may have a therapeutic effect on neurologic symptoms of SS

(Kampylafka et al. 2016). This case report presents a patient with pSS that manifested with repeated episodes of temporal hemiplegia, which was initially suspected to be a transient ischemic attack (TIA). Furthermore, the remarkable therapeutic effect of immunosuppressive therapies on this neurologic symptom is also described.

Case Presentation

A 53-year-old woman, diagnosed with Raynaud phenomenon and sicca symptoms 4 years before, initially evaluated for a 4-month history of several episodes of severe weakness and numbness of the left upper and lower extremities. Each episode lasted approximately 30 minutes, and the episodes occurred twice or thrice each month.

Moreover, during this 4-month period, the patient experienced symptoms of cognitive impairment, such as forgetting how to use her mobile phone and an inability in performing simple calculations.

The patient was admitted to a community hospital for similar TIA-like symptoms and underwent magnetic resonance imaging (MRI), magnetic resonance angiography of the brain, and angiocardiology to check for thrombi, which revealed no abnormalities. She had no history of diabetic mellitus, hyperlipidemia, or

hypertension. Thus, a collagen disease was suspected due to Raynaud symptom and sicca, despite the absence of any musculoskeletal, skin, and constitutional symptoms.

Antinuclear antibody testing was performed, for which the titer was strongly positive (1:2560, speckled) (<80). The patient was then referred to our institution for further evaluation and diagnostic testing.

The patient's laboratory test results were significant of the following: C-reactive protein was 1.2 mg/dL; serum immunoglobulin G (IgG) was slightly elevated at 2191 mg/dL (870-1700); complement levels (C3, C4, CH50) were normal; anti-SSA (Ro) (140 IU/mL) (<10), anti-SSB (La) (286 IU/mL) (<10), and rheumatoid factor (19 IU/mL) (<10) were positive; prothrombin time was 105.5% (70–130) and activated partial thromboplastin time was 31.9 s (24.3–36.0), protein C activity was 97% (70–150), protein S activity was 69% (56–162); and anti-RNP, Smith, double-stranded DNA, cardiolipin, beta2-glycoprotein antibodies, lupus anticoagulant, myeloperoxidase antineutrophil cytoplasmic antibody (ANCA), and proteinase 3-ANCA were negative. Schirmer test showed decreased tear secretion (right eye 2 mm, left eye 5 mm). Gum test showed reduced salivary flow rates (6 mL/10 min), and a lip biopsy revealed focal lymphocytic sialadenitis (Figure 1). Urinalysis revealed no proteinuria and occult blood.

Based on the 2016 American College of Rheumatology and European League Against Rheumatism criteria (Shiboski et al. 2017), the patient was diagnosed with pSS, and further testing was performed.

Cerebrospinal fluid (CSF) findings were as follows: white cell count 1 cell/ μ L (≤ 4), protein 120 mg/dL (10-40), IgG 20.6 mg/dL (0.5-4.0), IgG index 0.597 (< 0.8) and interleukin-6 (IL-6) < 8 pg/ml. Cerebral blood flow was evaluated with single photon emission computed tomography (SPECT), which showed hypoperfusion of the both hemispheres with slight left-sided dominance (Figure 2). Electroencephalography (EEG) demonstrated a slow wave activity (6.5–7.5 Hz) and an increase in delta power activity (Figure 3a). The diffuse brain hypoperfusion did not account for left-sided hemiplegia; hence, we considered that this hemiplegia was not caused by conventional TIA with stenosis of blood vessels or brain embolization. Although the temporal hemiplegia seemed to be a focal neurologic symptom, given the diffuse brain damage and the diagnosis of SS, we considered that the patient's neurologic symptoms were due to autoimmune-mediated mechanisms.

After sufficient informed consent, immunosuppressive treatments were started with prednisolone (PSL) (50 mg/day) and intravenous cyclophosphamide. After starting

immunosuppressive therapy, the temporal hemiplegia did not reappear. At 4-month follow-up, the brain hypoperfusion was improved as indicated on SPECT (Figure 2), and the delta power activity disappeared on the EEG (Figure 3b). After 10 administration of cyclophosphamide pulse therapy (total 5 g), azathioprine (50mg/day) was started; the PSL was decreased and maintained at 3 mg/day. At 8-year follow-up, the patient's neurologic symptoms had not recurred. Informed consent was obtained from the patient.

Discussion

In this case report, we describe a patient with pSS who experienced repeat episodes of temporal hemiplegia with a TIA-like presentation. The differential diagnosis of TIA is broad and includes brain tumors, CNS infection, trauma, hypoglycemia, migraines, multiple sclerosis, subarachnoid hemorrhage, and vertigo (Simmons et al. 2012). Although the patient's primary symptom was left-sided hemiplegia, the cerebral blood flow scintigraphy showed diffuse and EEG showed abnormal waves. The finding of hypoperfused brain lesions was inconsistent with the hemiplegia site; therefore, it was determined that she was not experiencing a conventional TIA. Neuropsychiatric

systemic lupus erythematosus (NPSLE) involves diffuse brain lesions and cognitive impairment (Simmons et al. 2012), and a wide range of neurologic involvement is also observed in pSS patients (Mekinian et al. 2020).

Although the pathophysiology of CNS involvement in pSS has yet to be elucidated, it can be caused by microvascular ischemic changes on brain associated with vasculitis and inflammatory cell infiltration (Jeltsch-David and Muller 2014). However, in this case, EEG recording during an episode of hemiplegia was not performed; therefore, the TIA-like symptom may be considered to be caused by epilepsy (Nadarajan et al. 2014), which is associated with NPSLE (Grasso et al. 2021). The pathogenesis of NPSLE involves brain-reactive autoantibodies, cell-mediated inflammation, and pro-inflammatory cytokines (Schwartz et al. 2019). Among these cytokines, IL-6 in brain was neurotoxic and associated with proconvulsive effects in animal models (Li et al. 2011) as well as functional diagnostic factor (Hirohata et al. 2009). Although our patient had low IL-6 in CSF, measuring the cytokine levels just after a neurological attack would help in clarifying the pathomechanism of neurological symptoms.

Although neurological symptoms were compatible to NPSLE, this patient did not develop skin rash, joint symptom, hematological disorder, and disease-specific

autoantibodies, therefore not meeting the diagnostic criteria for SLE (Aringer et al. 2019). CSF analysis showed albuminocytological dissociation in this patient. However, demyelinating diseases, such as Guillain-Barré syndrome and chronic inflammatory demyelinating polyneuropathy were unlikely since in the absence of peripheral neuropathy. This albuminocytological dissociation of CSF may indicate the dysfunction of blood brain barrier (Brooks et al. 2019). Brain MRI of our patient revealed no significant lesions. While CNS involvement in Sjögren's syndrome associated with vascular lesions and infarction show abnormalities in MRI (Ferreiro et al. 1987), some patients with non-focal/diffuse CNS disease had no abnormal MRI findings in pSS (Soliotis et al. 2004) and SLE (Luyendijk et al. 2011). These brain lesions are invisible in conventional MRI but might be detected in quantitative MRI (Luyendijk et al. 2011). Since this patient had no risks for atherosclerosis and embolism, we considered that this TIA-like symptom was caused by an autoimmune mechanism, and we then started her on immunosuppressive therapy.

The treatment for CNS involvement in pSS has yet to be established. Moreover, to the best of our knowledge, to date, no double-blind, placebo-controlled studies have been performed in this population. Thus, the treatment of CNS involvement in pSS is

typically based on case reports, uncontrolled studies, and similar reports of other rheumatic disease, such as systemic lupus erythematosus (SLE) (Bougea et al. 2015; Kampylafka et al. 2016). In this context, we selected high-dose steroids and cyclophosphamide, which were remarkably successful as an induction therapy for treatment of NPSLE (Bertsias et al. 2010).

Several cases with TIA in SS have been reported (Binder et al. 1988; Nagahiro et al. 1996; Sakata et al. 2014). In two cases (Nagahiro et al. 1996; Sakata et al. 2014), blood vessel stenosis occurred and treatment with bypass surgery was successful. In five cases (Binder et al. 1988), the treatment details were not described. To our knowledge, our case is the first report in which TIA-like symptoms of SS was successfully treated with immunosuppressive therapies.

This case suggests that pSS should be considered in the differential diagnosis for patients who present with TIA-like symptoms associated with diffuse brain damage on SPECT and/or EEG. In such a case, the patient should be examined for sicca symptoms and autoantibodies. The immunosuppressive therapies may be effective to treat the neurologic symptoms of SS.

Conflict of Interest

The authors declare no conflict of interests.

References:

- Alunno, A., Carubbi, F., Bartoloni, E., Cipriani, P., Giacomelli, R. & Gerli, R. (2019) The kaleidoscope of neurological manifestations in primary Sjogren's syndrome. *Clin Exp Rheumatol*, **37 Suppl 118**, 192-198.
- Aringer, M., Costenbader, K., Daikh, D., Brinks, R., Mosca, M., Ramsey-Goldman, R., Smolen, J.S., Wofsy, D., Boumpas, D.T., Kamen, D.L., Jayne, D., Cervera, R., Costedoat-Chalumeau, N., Diamond, B., Gladman, D.D., et al. (2019) 2019 European League Against Rheumatism/American College of Rheumatology Classification Criteria for Systemic Lupus Erythematosus. *Arthritis Rheumatol*, **71**, 1400-1412.
- Bertsias, G.K., Ioannidis, J.P., Aringer, M., Bollen, E., Bombardieri, S., Bruce, I.N., Cervera, R., Dalakas, M., Doria, A., Hanly, J.G., Huizinga, T.W., Isenberg, D., Kallenberg, C., Piette, J.C., Schneider, M., et al. (2010) EULAR recommendations for the management of systemic lupus

erythematosus with neuropsychiatric manifestations: report of a task force of the EULAR standing committee for clinical affairs. *Ann Rheum Dis*, **69**, 2074-2082.

Binder, A., Snaith, M.L. & Isenberg, D. (1988) Sjogren's syndrome: a study of its neurological complications. *Br J Rheumatol*, **27**, 275-280.

Bougea, A., Anagnostou, E., Konstantinos, G., George, P., Triantafyllou, N. & Kararizou, E. (2015) A Systematic Review of Peripheral and Central Nervous System Involvement of Rheumatoid Arthritis, Systemic Lupus Erythematosus, Primary Sjogren's Syndrome, and Associated Immunological Profiles. *Int J Chronic Dis*, **2015**, 910352.

Brito-Zeron, P., Baldini, C., Bootsma, H., Bowman, S.J., Jonsson, R., Mariette, X., Sivils, K., Theander, E., Tzioufas, A. & Ramos-Casals, M. (2016) Sjogren syndrome. *Nat Rev Dis Primers*, **2**, 16047.

Brooks, J.A., McCudden, C., Breiner, A. & Bourque, P.R. (2019) Causes of albuminocytological dissociation and the impact of age-adjusted cerebrospinal fluid protein reference intervals: a retrospective chart review of 2627 samples collected at tertiary care centre. *BMJ Open*, **9**,

e025348.

Delalande, S., de Seze, J., Fauchais, A.-L., Hachulla, E., Stojkovic, T., Ferriby,

D., Dubucquoi, S., Pruvo, J.-P., Vermersch, P. & Hatron, P.-Y. (2004)

Neurologic Manifestations in Primary Sjögren Syndrome. *Medicine*, **83**,

280-291.

Ferreiro, J.E., Robalino, B.D. & Saldana, M.J. (1987) Primary Sjogren's

syndrome with diffuse cerebral vasculitis and lymphocytic interstitial

pneumonitis. *Am J Med*, **82**, 1227-1232.

Grasso, E.A., Cacciatore, M., Gentile, C., Breda, L., Giacomelli, R. & Verrotti, A.

(2021) Epilepsy in systemic lupus erythematosus. *Clin Exp Rheumatol*,

39, 651-659.

Hirohata, S., Kanai, Y., Mitsuo, A., Tokano, Y., Hashimoto, H. & Subcommittee,

N.R. (2009) Accuracy of cerebrospinal fluid IL-6 testing for diagnosis of

lupus psychosis. A multicenter retrospective study. *Clin Rheumatol*, **28**,

1319-1323.

Jeltsch-David, H. & Muller, S. (2014) Neuropsychiatric systemic lupus

erythematosus and cognitive dysfunction: the MRL-lpr mouse strain as a

model. *Autoimmun Rev*, **13**, 963-973.

Kampylafka, E.I., Alexopoulos, H., Dalakas, M.C. & Tzioufas, A.G. (2016)

Immunotherapies for Neurological Manifestations in the Context of
Systemic Autoimmunity. *Neurotherapeutics*, **13**, 163-178.

Li, G., Bauer, S., Nowak, M., Norwood, B., Tackenberg, B., Rosenow, F., Knake,

S., Oertel, W.H. & Hamer, H.M. (2011) Cytokines and epilepsy. *Seizure*,
20, 249-256.

Luyendijk, J., Steens, S.C.A., Ouwendijk, W.J.N., Steup-Beekman, G.M., Bollen,

E.L.E.M., van der Grond, J., Huizinga, T.W.J., Emmer, B.J. & van
Buchem, M.A. (2011) Neuropsychiatric systemic lupus erythematosus:
Lessons learned from magnetic resonance imaging. *Arthritis &
Rheumatism*, **63**, 722-732.

Manzo, C., Martinez-Suarez, E., Kechida, M., Isetta, M. & Serra-Mestres, J.

(2019) Cognitive Function in Primary Sjogren's Syndrome: A Systematic
Review. *Brain Sci*, **9**.

Margaretten, M. (2017) Neurologic Manifestations of Primary Sjogren

Syndrome. *Rheum Dis Clin North Am*, **43**, 519-529.

Mekinian, A., Tennenbaum, J., Lahuna, C., Dellal, A., Belfeki, N., Capron, J.,

Januel, E., Stankoff, B., Alamowitch, S. & Fain, O. (2020) Primary

Sjogren's syndrome: central and peripheral nervous system involvements.

Clin Exp Rheumatol, **38 Suppl 126**, 103-109.

Nadarajan, V., Perry, R.J., Johnson, J. & Werring, D.J. (2014) Transient

ischaemic attacks: mimics and chameleons. *Pract Neurol*, **14**, 23-31.

Nagahiro, S., Mantani, A., Yamada, K. & Ushio, Y. (1996) Multiple cerebral

arterial occlusions in a young patient with Sjogren's syndrome: case

report. *Neurosurgery*, **38**, 592-595; discussion 595.

Sakata, H., Fujimura, M., Sato, K., Shimizu, H. & Tominaga, T. (2014) Efficacy

of extracranial-intracranial bypass for progressive middle cerebral artery

occlusion associated with active Sjogren's syndrome: case report. *J Stroke*

Cerebrovasc Dis, **23**, e399-e402.

Schwartz, N., Stock, A.D. & Putterman, C. (2019) Neuropsychiatric lupus: new

mechanistic insights and future treatment directions. *Nat Rev Rheumatol*.

Shiboski, C.H., Shiboski, S.C., Seror, R., Criswell, L.A., Labetoulle, M., Lietman,

T.M., Rasmussen, A., Scofield, H., Vitali, C., Bowman, S.J., Mariette, X.

& International Sjogren's Syndrome Criteria Working, G. (2017) 2016
American College of Rheumatology/European League Against
Rheumatism Classification Criteria for Primary Sjogren's Syndrome: A
Consensus and Data-Driven Methodology Involving Three International
Patient Cohorts. *Arthritis Rheumatol*, **69**, 35-45.

Simmons, B.B., Gadegbeku, A.B. & Cirignano, B. (2012) Transient ischemic
attack: Part II. Risk factor modification and treatment. *Am Fam
Physician*, **86**, 527-532.

Soliotis, F.C., Mavragani, C.P. & Moutsopoulos, H.M. (2004) Central nervous
system involvement in Sjogren's syndrome. *Ann Rheum Dis*, **63**, 616-620.

Figure Legends

Figure 1. Histopathology of minor salivary gland

Lymphocytic sialadenitis with periductular aggregates of >50 lymphocytes, compatible with Sjögren's syndrome (hematoxylin-eosin staining, $\times 40$). Scale bar is 100 μm long.

Figure 2. Single photon emission computed tomography. Brain blood flow was

evaluated before (upper panels, axial section) and 7 months after immunosuppressive therapies (lower panels, coronal section) in each coronal (a) and transverse (b) section.

Blood flow was remarkably improved after the treatments.

SPECT: Single photon emission computed tomography

Figure 3. Electroencephalography recorded before (a) and 7 months after

immunosuppressive therapies (b). Slow wave activity (6.5–7.5Hz) was improved to 8–9 Hz and delta power activity disappeared after immunosuppressive treatments.

Figure 1

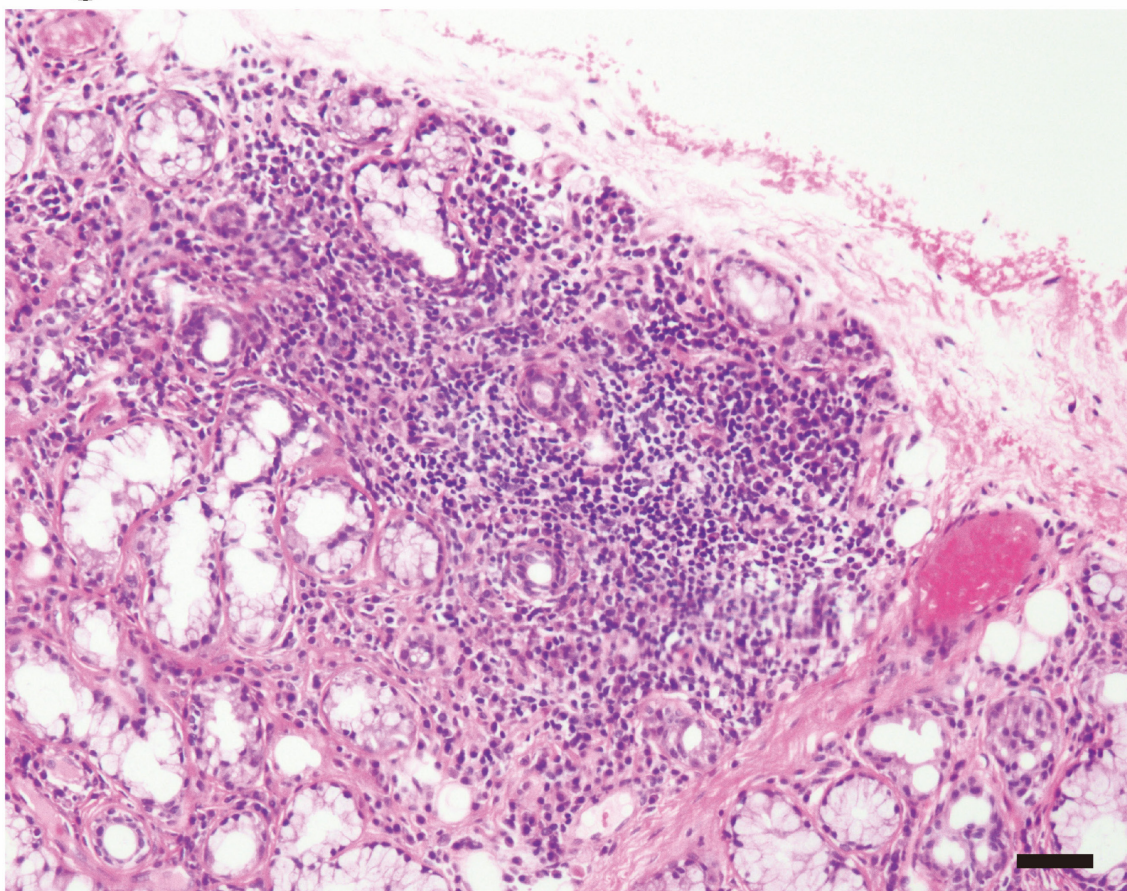
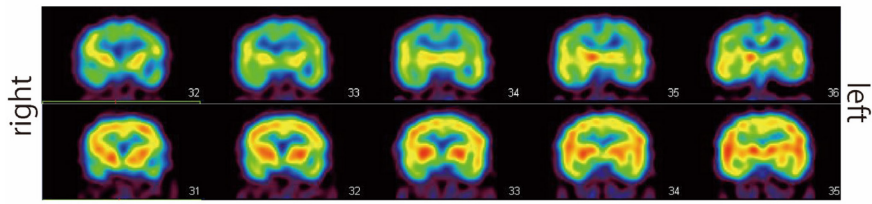


Figure 2

a



b

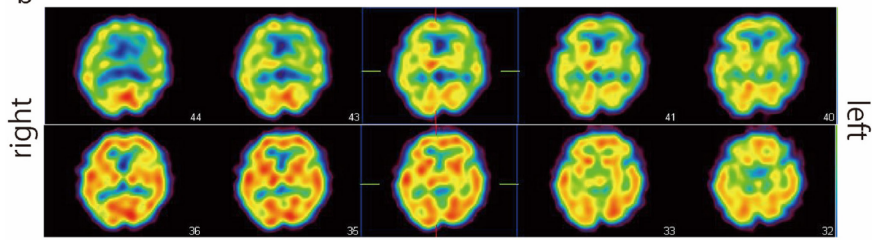
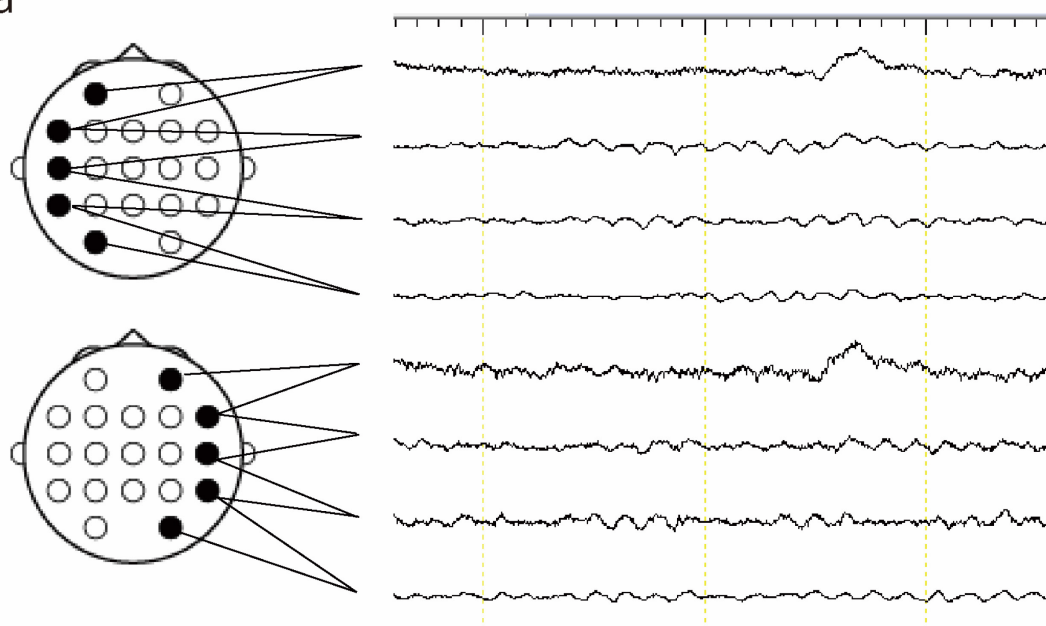


Figure 3

a



b

