

CASE REPORT

Open Access



Binary effects of intravascular laser irradiation of blood on motor recovery and homocysteine reduction in a case with ischemic hemiparesis: portrayed with brain perfusion images

Sheng-Wen A. Li^{1†} , Yen-Po Lin^{2†} , Shih-Po Hsieh¹  and Shin-Tsu Chang^{3,4*} 

Abstract

Background: Stroke is a burdensome cerebral event that affects many aspects of daily activities such as motion, speech, memory, vision, and cognition. Intravascular laser irradiation of blood (ILIB) is a novel therapy, going beyond conventional rehabilitation modalities, that is effective in stroke recovery. Homocysteine is an important risk factor associated with stroke. However, there are few studies that examine the relationship between ILIB treatment and the level of homocysteine. In recent years, researchers use the single-photon emission computed tomography (SPECT) scan of the brain to evaluate stroke patients and patients with a neurologic deficit. The present report investigates the clinical effect of ILIB treatment on the level of serum homocysteine, the perfusion change of impaired brain region via SPECT, and the patient's neurologic appearance.

Case presentation: We focus on a case of a 62-year-old man with subacute stroke accompanied with left hemiparesis and hyperhomocysteinemia, who showed dramatic improvement in muscle power, a decreasing level of homocysteine, and increased blood flow of the right cerebral after three-course ILIB treatment.

Conclusion: We found that ILIB is effective in lowering serum levels of homocysteine and facilitating cerebral circulation for the patient with subacute stroke.

Keywords: Intravascular laser irradiation of blood, Homocysteine, Corona radiata, Hemiparetic stroke, Cerebral hemisphere, Single photon emission computed tomography

Background

Stroke is a common cerebral event that occurs to millions of people globally, which may provoke partial paralysis, affect speech function, memory, or visual loss. People who have a stroke may be unable to perform daily activities, consequently becoming a burden to family caregivers, which affects their physical, emotional, social, and financial wellbeing [1]. Rehabilitation plays an important role in helping patients achieve their best recovery and return to normal daily activities. Physical therapy,

[†]Sheng-Wen A. Li and Yen-Po Lin contributed equally to this work.

*Correspondence: ccdivlaser1959@gmail.com

³ Department of Physical Medicine and Rehabilitation, Kaohsiung Veterans General Hospital, No.386, Dazhong 1st Rd., Zuoying Dist., Kaohsiung 813414, Taiwan

Full list of author information is available at the end of the article



occupational therapy, and speech therapy were common rehabilitation disciplines. Complementary and alternative interventions such as intravascular laser irradiation of blood, acupuncture, Chinese herbal medicine, yoga, and Tai-Chi also offer efficacy in improving patient outcomes [2].

Homocysteine is an amino acid derived from the metabolism of dietary methionine, and it is a well-known risk factor associated with atherothrombotic vascular events. Deleterious effects on vascular endothelial cell function were discovered in both animal models and human studies with a high level of homocysteine [3]. An elevated homocysteine level increases the risk of recurrent ischemic stroke in patients experiencing the convalescent phase of acute stroke [4]. Therefore, it is vital to understand how to decrease the level of homocysteine in clinical practice.

Intravascular laser irradiation of blood (ILIB) is an alternative therapy for various illnesses such as stroke, pain, spinal cord injury, diaschisis [5], sleep disturbance [6], delayed neurological sequelae [7], cognitive dysfunction after brain tumor [8], and Sjögren's syndrome [9]. However, the association between ILIB and the level of homocysteine remains unknown. In this report, we present a case of a patient with subacute stroke accompanied by left hemiparesis and hyperhomocysteinemia, who underwent ILIB treatment.

Case presentation

The 62-year-old male patient has no underlying disease. He found his left-hand fingers clumsy and had difficulty performing adduction and flexion while washing his hair on July 23, 2021. Symptoms progressed to his left leg, and he could not maneuver his left leg. He was sent to NCKUH Emergency Room (ER), where the ER doctor considered his symptom as an episode of stroke and arranged a brain computed tomography (CT) scan soon. The CT image showed no sign of intracerebral hemorrhage (ICH). The patient's initial National Institutes of Health Stroke Scale score was 2 points, and, as a result, he did not receive thrombolytic therapy.

After inpatient admission on July 24, the carotid duplex test showed mild to moderate atherosclerosis without significant hemodynamic change. Dual antiplatelet therapy (aspirin and clopidogrel) was given for stroke. Unfortunately, his symptoms worsened on July 25, 2021, and the patient was paralyzed on the left side of his body with left facial palsy and mild dysarthria. Repeated CT was conducted due to progression of left limb weakness and numbness, and still showed no sign of ICH. Instead, magnetic resonance imaging (MRI) of the brain without contrast showed acute infarction in right corona radiata, together with stenosis of left vertebral artery and basilar

artery. Titrated hydration with dual anti-platelet was kept. Statin was applied for newly diagnosed dyslipidemia, as well as an antihypertensive drug was given.

The patient was transferred to the Ministry of Health and Welfare Tainan Hospital for Post-Acute Care on August 6, 2021, where he achieved partial recovery of muscle power. The patient called at our outpatient department for advanced recovery on August 26, 2021, where neurologic examination revealed muscle power grade 3 at left upper limb and 5 at left lower limb. The patient could walk slowly without a cane but had a limited range of motion for flexion and extension of the left foot. He was strenuous for him to raise his hand by himself. He was admitted for neurologic and motor recovery. Laboratory data revealed normal values in most items (included C reactive protein 0.1 mg/d, Creatinine 1.16 mg/dl, Mean corpuscular volume 89.4 fl), except homocysteine as 15.97 $\mu\text{mol/L}$ (normal range: 5-15 $\mu\text{mol/L}$).

The brain single-photon emission computed tomography (SPECT) showed a decrease in right cerebral blood flow of right sensorimotor strip, anterior and posterior cingulate gyri, left medial temporal lobe, corona radiata, basal ganglion, and thalamus, as revealed in Fig. 1A.

The comprehensive care plan, including physical therapy, occupational therapy, and language therapy, attained limited improvement of the patient's condition. Thus, ILIB therapy was added as an alternative treatment. After three courses of ILIB therapy, the patient's condition improved. The following muscle strength was grade 5 over his left arm and grade 4 over his elbow and wrist. Motion range of his lower left feet increased, and muscle power improved to grade 5. The second SPECT showed mild improvement of right cerebral hemisphere blood flow, e.g., frontal lobe, anterior cingulate gyrus, corona radiata, basal ganglion, and thalamus, as shown in Fig. 1B. The patient's homocysteine level decreased from 15.97 to 10 $\mu\text{mol/L}$, with stable data result of C reactive protein (0.11 mg/d), Creatinine (1.01 mg/dl), and Mean corpuscular volume (91.0 fl).

Discussion and conclusions

A comprehensive rehabilitation program is critical to optimize post-stroke outcomes. With the development of new treatment modalities for stroke, ILIB is proposed for cognitive dysfunction, motor dysfunction, and crossed cerebellar diaschisis after acute stroke [5, 10]. However, homocysteine, which has been confirmed as the risk factor of stroke, is not mentioned before and after ILIB treatment in existing literature [11]. To the best of our knowledge, this is the first report using both SPECT and homocysteine to track the efficacy of ILIB in ischemia stroke. Our case is a subacute stroke with left hemiparesis and a high level of homocysteine. Even under physical

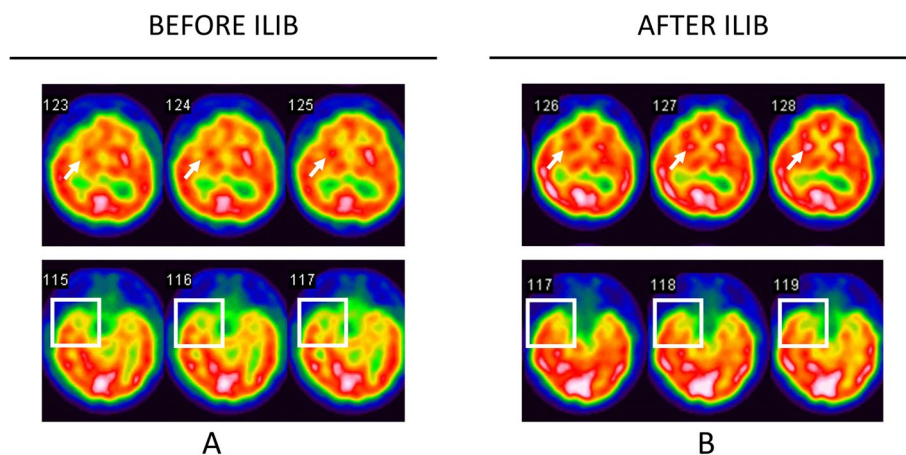


Fig. 1 The brain SPECT images of the patient. In **A**, SPECT showed a decrease of the right cerebral blood flow in the right sensorimotor strip, frontal lobe, anterior and posterior cingulate gyri, left medial temporal lobe (white box), corona radiata, basal ganglion (white arrow), and thalamus. In **B**, there is increased uptake in the frontal lobe, temporal lobe, basal ganglion, amygdala, and pons

therapy and occupational therapy, recovery was still limited. To our surprise, after ILIB therapy, the muscle power increased from grade 3 to 5; homocysteine levels decreased from 15.97 to 10 $\mu\text{mol/L}$, and the following SPECT demonstrate an obvious improvement of right cerebral hemisphere blood flow e.g., anterior cingulate gyrus, basal ganglion, and thalamus.

In the past decades, homocysteine is considered an indicator of vascular disease worldwide [12]. Increasing evidence has confirmed that patients with acute stroke and hyperhomocysteinemia are at an increased risk of early neurological deterioration [13]. Considering our case treated with ILIB, the homocysteine level reduced to the normal range. This result was similar to, but not the same with a recently published article reporting a hemorrhagic stroke survivor, which examined serum level of the homocysteine before and after the ILIB and concluded that ILIB might possess a dual effect to increase thalamic perfusion and simultaneously enhance catabolism of homocysteine [14]. In contrast to the aforementioned study regarding ICH, our case is ischemic stroke, which is approximately 87% of stroke, as reported by Grysiwicz et al. [15]. However, medical use of statins, as a secondary stroke prevention, may also cause lower homocysteine concentrations in patients, reported by a latest meta-analysis [16], leading difficulty to clarify the individual effectiveness of ILIB. Despite that further cohort study is required, our result offers an insight into ILIB to reduce serum level of homocysteine in patients with both types of strokes.

Brain SPECT is an effective clinical method, although it is often ignored. The imaging modality has been used in assessing prognosis, in evaluating response to therapy,

and in monitoring many neurologic and psychiatric recovery [17]. A prospective study conducted in 1988 first applied SPECT in patients with brainstem stroke and confirmed a significant difference in frontal and parietal hypoperfusion when compared mean counts with age-matched controls [18]. In recent years, researchers use this feasible tool to present the issue of stroke in patients and obtain huge clinical information. In our case, the second SPECT images show remarkable improvement in blood perfusion after the ILIB. Simultaneously, the patient showed a diminish of left hemiparesis and numbness. Moreover, he demonstrated better functional activities in daily life compared with that of the initial evaluation by neurologic examination of muscle power, range of motion and ADL Index. The improvement in our patient symptoms should be correlated with an increase in blood flow of the right frontal lobe, in which the mechanism has been approved by previous study [19]. The injured ischemic motor cortex has a reduced cortical excitability at the acute phase and a suspension of the topographic representation of affected muscles, contributing to worsening of neurological deficit. Thus, when we improve blood perfusion in ischemic stroke patients using ILIB therapy, a great clinical improvement was recorded.

In the present study, the post-treatment imaging study revealed that the ILIB was effective in facilitating circulation. Another case report shows a similar progression in an Impaired blood flow of the basal ganglion after the ILIB [20]. In the case by Sun et al., the patient has a limited improvement of speech, comprehension, and limbs movement after 1 month of intensive physical, occupational, and speech therapy. However, after ILIB

intervention, the patient's overall functions improved, and SPECT improved before perfusion deficit at the right frontal and parietal regions. Their result may be consistent with ours, indicating that ILIB could be a novel technique to treat patients with ischemic infarction.

Concerning the mechanism of circulation and metabolism of ILIB in an animal study, some new neuronal cells were generated in the subventricular zone of the infarcted hemisphere in stroke rats, which received ILIB [21]. Regarding the human study, several pieces of evidence confirm that ILIB promotes and induces a photobiological response inside cells, activates the production of adenosine triphosphate, and red blood cells deformability to pass through tiny blood vessels, and amplifies microcirculation [22]. Although further studies are needed to extend ILIB into treating other diseases, it could be an alternative treatment for patients with stroke.

Our case concerns a subacute stroke with left hemiparesis and a high level of homocysteine. The intervention of ILIB could help the patient to achieve some degree of neurologic recovery and reduce homocysteine, which is considered a risk factor. Brain SPECT plays an important role in appraising recovery. Our case demonstrated a useful method in scintigraphic rehabilitation.

Abbreviations

MRI: Magnetic resonance imaging; ICH: Intracerebral hemorrhage; CT: Computed tomography; ER: Emergency Room; ILIB: Intravascular laser irradiation of blood; SPECT: Single-photon emission computed tomography.

Acknowledgements

Not applicable.

Authors' contributions

SWL and YPL drafted the main manuscript and contributed equally to this work. SPH participated in the edition of the manuscript. STC conceptualized and executed the case report. All authors read and approved the final manuscript.

Funding

The study was not funded.

Availability of data and materials

The datasets used and/or analyzed during the current study are available from the corresponding author on reasonable request.

Declarations

Ethics approval and consent to participate

The patient gave written informed consent prior to obtain the data.

Consent for publication

Written informed consent was obtained from the patient after treatment for publication of this case report and any accompanying images.

Competing interests

The authors declare that they have no competing interests.

Author details

¹School of Medicine, National Defense Medical Center, Taipei, Taiwan. ²School of Medicine, Chung-Shan Medical University, Taichung, Taiwan. ³Department

of Physical Medicine and Rehabilitation, Kaohsiung Veterans General Hospital, No.386, Dazhong 1st Rd., Zuoying Dist., Kaohsiung 813414, Taiwan. ⁴Department of Physical Medicine and Rehabilitation, Tri-Service General Hospital School of Medicine, National Defense Medical Center, Neihu District, No. 161, Section 6, Minquan East Road, Taipei 114201, Taiwan.

Received: 25 February 2022 Accepted: 15 September 2022

Published online: 27 September 2022

References

- Caro CC, Costa JD, Da Cruz DMC. Burden and quality of life of family caregivers of stroke patients. *Occup The Health care*. 2018;32(2):154–71. <https://doi.org/10.1080/07380577.2018.1449046>.
- Venkatasubramanian N. Complementary and alternative interventions for stroke recovery - a narrative overview of the published evidence. *J Complement Integr Med*. 2021;18(3):553–9. <https://doi.org/10.1515/jcim-2020-0062>.
- Lai WK, Kan MY. Homocysteine-induced endothelial dysfunction. *Ann Nutr Metab*. 2015;67(1):1–12. <https://doi.org/10.1159/000437098>.
- Shi Z, Liu S, Guan Y, Zhang M, Lu H, Yue W, et al. Changes in total homocysteine levels after acute stroke and recurrence of stroke. *Sci Rep*. 2018;8(1):6993. <https://doi.org/10.1038/s41598-018-25398-5>.
- Yang WH, Lin SP, Chang ST. Case report: Rapid improvement of crossed cerebellar diaschisis after intravascular laser irradiation of blood in a case of stroke. *Medicine*. 2017;96(2):e5646. <https://doi.org/10.1097/md.00000000000005646>.
- Chang YL, Chang ST. The effects of intravascular photobiomodulation on sleep disturbance caused by Guillain-Barré syndrome after AstraZeneca vaccine inoculation: Case report and literature review. *Medicine*. 2022;101(6):e28758. <https://doi.org/10.1097/md.00000000000028758>.
- Liu CC, Hsu CS, He HC, Cheng YY, Chang ST. Effects of intravascular laser phototherapy on delayed neurological sequelae after carbon monoxide intoxication as evaluated by brain perfusion imaging: A case report and review of the literature. *World J Clin cases*. 2021;9(13):3048–55. <https://doi.org/10.12998/wjcc.v9.i13.3048>.
- Liu PY, Liu CC, Liu IT, He HC, Chang ST. Advancement of the cognitive function on laser exposure after tumor removal in a case with neoplasm. *J Light Laser Curr Trends*. 2019;2(006):001-6.
- Liu EY, Chang ST. Benefits of intravascular laser irradiation of blood on motor and sensory recovery viewing from brain function images: portrait of a case with chronic Sjögren's syndrome, transverse myelitis, and Guillain-Barré syndrome. *Biomed J Sci Tech Res*. 2019;14:10738–41.
- Hsieh TDL, Hsieh PF, He HC, Cheng YY, Chang ST. Swift improvement of prolonged motor deficit: cumulative effect of phototherapy in a survivor from hemorrhagic stroke. *Jpn J Med Sci*. 2021;2(4):75–8.
- Chrysant SG, Chrysant GS. The current status of homocysteine as a risk factor for cardiovascular disease: a mini review. *Expert Rev Cardiovasc Ther*. 2018;16(8):559–65. <https://doi.org/10.1080/14779072.2018.1497974>.
- McCully KS. Homocysteine, vitamins, and prevention of vascular disease. *Mil Med*. 2004;169(4):325–9. <https://doi.org/10.7205/milmed.169.4.325>.
- Kwon HM, Lee YS, Bae HJ, Kang DW. Homocysteine as a predictor of early neurological deterioration in acute ischemic stroke. *Stroke*. 2014;45(3):871–3. <https://doi.org/10.1161/strokeaha.113.004099>.
- Chang JY, Liu LC, Liu IT, Chang ST. Effects of intravascular laser irradiation of blood on cognitive function in a stroke survivor with hyperhomocysteinemia: dual recuperations in thalamus and serum homocysteine. *Biomed J Sci & Tech Res*. 2019;16:11864–8.
- Grysiwicz RA, Thomas K, Pandey DK. Epidemiology of ischemic and hemorrhagic stroke: incidence, prevalence, mortality, and risk factors. *Neurol Clin*. 2008;26(4):871–95, vii. <https://doi.org/10.1016/j.ncl.2008.07.003>.
- Zinellu A, Mangoni AA. Effect of statin treatment on homocysteine concentrations: an updated systematic review and meta-analysis with meta-regression. *Expert Rev Clin Pharmacol*. 2022;1–17; doi: <https://doi.org/10.1080/17512433.2022.2072293>.
- Camargo EE. Brain SPECT in neurology and psychiatry. *J Nucl Med*. 2001;42(4):611–23.

18. Hoffmann M, Watts A. Cognitive dysfunction in isolated brainstem stroke: a neuropsychological and SPECT study. *J Stroke Cerebrovasc Dis.* 1998;7(1):24–31. [https://doi.org/10.1016/s1052-3057\(98\)80018-9](https://doi.org/10.1016/s1052-3057(98)80018-9).
19. Thompson PD. Frontal lobe ataxia. *Handb Clin Neurol.* 2012;103:619–22. <https://doi.org/10.1016/b978-0-444-51892-7.00044-9>.
20. Chang ST, Sung JH. Reversal of impaired blood flow of the basal ganglion from the prior focal perfusion defect in a case of ischemic infarction: observation during the two stages of administration of intravenous laser irradiation of blood. *JMedStud Res.* 2019;2(1):01–5. <https://doi.org/10.24966/msr-5657/100011>.
21. Oron A, Oron U, Chen J, Eilam A, Zhang C, Sadeh M, et al. Low-level laser therapy applied transcranially to rats after induction of stroke significantly reduces long-term neurological deficits. *Stroke.* 2006;37(10):2620–4. <https://doi.org/10.1161/01.STR.0000242775.14642.b8>.
22. Kazemi Khoo N, Iravani A, Arjmand M, Vahabi F, Lajevardi M, Akrami SM, et al. A metabolomic study on the effect of intravascular laser blood irradiation on type 2 diabetic patients. *Lasers Med Sci.* 2013;28(6):1527–32. <https://doi.org/10.1007/s10103-012-1247-4>.

Publisher's Note

Springer Nature remains neutral with regard to jurisdictional claims in published maps and institutional affiliations.

Ready to submit your research? Choose BMC and benefit from:

- fast, convenient online submission
- thorough peer review by experienced researchers in your field
- rapid publication on acceptance
- support for research data, including large and complex data types
- gold Open Access which fosters wider collaboration and increased citations
- maximum visibility for your research: over 100M website views per year

At BMC, research is always in progress.

Learn more biomedcentral.com/submissions

