

anomalies of the eye as illustrated in the 'Transactions' of the Society. *Trans Ophthalmol Soc UK* 1898;18:1-16.

9. Valentin B: Die Korrelation (Koppelung) von Missbildungen, erläutert am Beispiel der Akrocephalosyndaktylie. *Acta Orthop Scand* 1938;9:235-316.

10. Martischinig E, Thalhammer O: Akrocephalosyndaktylie (Erörterung der Genese von Gesichtspunkt der Embryopathie). *Helv Paediatr Acta* 1952;7:257-271.

11. Gross H: Zur Kenntnis der Beziehungen zwischen Gehirn und Schädelkapsel bei den turriciphalen, craniostenotischen Dysostosen. *Virchows Arch A* 1957;330:365-383.

12. Hogan GR, Bauman ML: Hydrocephalus in Apert's syndrome. *J Pediatr* 1971;79:782-787.

13. Maksem JA, Roessmann U: Apert's syndrome with central nervous system anomalies. *Acta Neuropathol* 1979;48:59-61.

14. Stewart RE, Dixon G, Cohen A: The pathogenesis of premature craniosynostosis in acrocephalosyndaktyly (Apert's syndrome): A reconsideration. *Plast Reconstr Surg* 1977;59:699-707.

15. Leonard CO, Daikoku NH, Winn K: Prenatal fetoscopic diagnosis of the Apert syndrome. *Am J Med Genet* 1982;11:5-9.

16. Tessier P: The definitive plastic surgical treatment of the severe facial deformities of craniofacial dysostosis: Crouzon's and Apert's diseases. *Plast Reconstr Surg* 1971;48:419-442.

17. Ortiz Monasterio F, Fuente del Campo A, Carrillo A: Advancement of the orbits and the midface in one piece, combined with frontal repositioning for the correction of Crouzon's deformities. *Plast Reconstr Surg* 1978;61:507-516.

18. Raulo Y, Tessier P: Fronto-facial advancement for Crouzon's and Apert's syndromes.

Scand J Plast Reconstr Surg 1981;15:245-250.

19. Patten BM: *Human Embryology*, ed 3. New York, McGraw-Hill International Book Co, 1968.

20. Friede H: Normal development and growth of the human neurocranium and cranial base. *Scand J Plast Reconstr Surg* 1981;15:163-169.

21. Zellweger H, von Murat G: Zur Pathologie des Septum pellucidum im Pneumoencephalogram (PEG). *Helv Paediatr Acta* 1952;7:229-252.

22. Gross H, Hoff H: Sur les malformations ventriculaires dépendantes des dysgénésies commissurales, in Heuyer G, Feld M, Gruner J (eds): *Les Malformations Congénitales du Cerveau*. Paris, Masson et Cie, 1959, pp 329-351.

23. Trzebicki J, Golabek R: Anomalies du septum pellucidum. *Ann Radiol* 1969;12:493-497.

24. Bruyn GW: Agenesis septi pellucidi, cavum septi pellucidi, cavum Vergae, and cavum veli interpositi, in Vinken PJ, Bruyn GW (eds): *Handbook of Clinical Neurology*. Amsterdam, North Holland Publishing Co, 1977, vol 30, chap 13, pp 299-336.

25. Norman RM: Malformation of the corpus callosum, in Blackwood W, McMenemey WH, Meyer A, et al (eds): *Grenfield's Neuropathology*, ed 2. Baltimore, Williams & Wilkins, 1963, pp 345-347.

26. Blank CE: Apert's syndrome (a type of acrocephalosyndaktyly): Observations on a British series of 39 cases. *Ann Hum Genet* 1960;24:151-164.

27. Vollmer DG, Park TS, Cail WS, et al: Hydromyelia complicating Apert's syndrome: A case report. *Neurosurgery* 1985;17:70-74.

28. Crome L, Stern J: *Pathology of Mental Retardation*, ed 2. London, Churchill Livingstone Inc, 1972.

29. Ettliger G, Blakemore CB, Milner AD, et

al: Agenesis of the corpus callosum: A further behavioural investigation. *Brain* 1974;97:225-234.

30. Gott PS, Saul RE: Agenesis of the corpus callosum: Limits of functional compensation. *Neurology* 1979;28:1271-1279.

31. Akelaitis AJ: A study of gnosis, praxis, and language following section of the corpus callosum and anterior commissure. *J Neurosurg* 1944;1:94-102.

32. Bogen JE: The callosal syndromes, in Heilman KM, Valenstein E (eds): *Clinical Neuropsychology*, ed 2. New York, Oxford University Press, 1985, chap 11, pp 295-338.

33. Loeser JD, Alvord EC Jr: Agenesis of the corpus callosum. *Brain* 1968;91:553-570.

34. Rakic P, Yakovlev PI: Development of the corpus callosum and cavum septi in man. *J Comp Neurol* 1968;132:45-72.

35. Leech RW, Shuman RM: Holoprosencephaly and related midline cerebral anomalies: A review. *J Child Neurol* 1986;1:3-18.

36. Klüver H, Bucy PC: Preliminary analysis of functions of the temporal lobes in monkeys. *Arch Neurol Psychiatry* 1939;42:979-1000.

37. Damasio AR, Van Hoesen GW: Emotional disturbances associated with focal lesions of the limbic frontal lobe, in Heilman KM, Satz P (eds): *Neuropsychology of Human Emotion*. New York, The Guilford Press, 1983, chap 4, pp 85-110.

38. Duyckaerts C, Derouesne C, Signoret JL, et al: Bilateral and limited amygdalohippocampal lesions causing a pure amnesic syndrome. *Ann Neurol* 1985;18:314-319.

39. Parrish ML, Roessmann U, Levinsohn MW: Agenesis of the corpus callosum: A study of the frequency of associated malformations. *Ann Neurol* 1979;6:349-354.

Neurologic, Audiologic, and Electrophysiologic Sequelae of Bilateral Temporal Lobe Lesions

Kennely J. Ho, MD; Paul Kileny, PhD; Daniel Paccioretti, MS; Donald R. McLean, MD

● A 67-year-old woman with demonstrated intact peripheral and brain-stem auditory pathways presented with sudden deafness secondary to sequential bilateral temporal lobe infarcts. Initial examination revealed no behavioral response to sounds and a mild Wernicke's aphasia. Hearing gradually returned but auditory

agnosia persists. Changes seen on the computed tomographic scan and the middle latency auditory evoked response over a seven-month period were analyzed and suggest that the peak component of the middle latency response arises from Heschl's gyrus.

(*Arch Neurol* 1987;44:982-987)

Auditory evoked responses have become useful clinical tools for the assessment of auditory dysfunction. Recently there has been renewed

interest in the audiologic and neurologic applications of scalp-recorded middle latency auditory evoked responses.¹⁻³ The middle latency response (MLR) occurs within 100 ms following an effective auditory stimulus. In adults the most prominent and robust component of this response is a vertex-positive peak with a latency of 25 to 35 ms, usually labeled *Pa*.^{4,5} The MLR may be recorded over wide regions of the scalp but is usually maximal in amplitude over frontocentral head regions near the vertex.^{4,6}

The generator source of the MLR in humans has not been clearly identified.¹ A myogenic source from overlying scalp muscles was ruled out as the MLR remained unaffected following administration of neuromuscular blocking agents.^{7,8} In an early review, Picton et al⁴ described several possible neural generator sources for the MLR: thalamus, primary auditory cortex, and association cortex in the frontal, parietal, and temporal lobes. To further isolate these neural substrates, the effects of unilateral human brain lesions in various locations were studied. Patients with confirmed unilateral temporal lobe lesion but not frontal or parietal lesion demonstrated amplitude reduction or absence of the *Pa* component of the MLR in surface recordings over the involved hemisphere.⁹ The observation that the MLR was intact in unilateral anterior temporal lobectomies

Accepted for publication June 8, 1987.

From the Division of Neurology, Department of Medicine, University of Alberta, Edmonton, Canada (Drs Ho and McLean); Glenrose Rehabilitation Hospital, Edmonton, Canada (Mr Paccioretti); and the Department of Otolaryngology, Head and Neck Surgery, University of Michigan Medical Center, Ann Arbor (Dr Kileny).

Reprint requests to the Division of Neurology, Department of Medicine, 2E3.16 Walter Mackenzie Centre, University of Alberta, Edmonton, Canada T6G 2B7 (Dr Ho).

further narrowed the source of the neural generators to the posterior temporal lobes.^{1,10} Additional analysis revealed that the midline recorded MLR was the sum of bilateral and symmetrical generators. A lesion in one temporal lobe may diminish, but usually does not abolish a vertex-recorded MLR due to contributions from the intact contralateral temporal lobe.^{6,9} The routine use of a coronal chain of recording electrodes was emphasized in determining the relative contributions from either temporal lobe.^{1,9,11}

The effects of bilateral temporal lobe lesions on the MLR and on the cortical processing of auditory information have rarely been studied, in part due to the rarity of such cases. The few reports in the recent literature have arrived at opposing conclusions with regard to the role of the primary auditory cortex in the generation of the MLR.^{1,12,13} This report documents the behavioral, electrophysiologic, and computed tomographic (CT) findings in a patient with bilateral temporal lobe infarctions presenting with sudden onset of cortical deaf-

ness. Follow-up evaluations in this patient correlating clinical, MLR, and CT scan changes over time help clarify the neural substrates underlying the MLR.

REPORT OF A CASE AND BEHAVIORAL ASSESSMENT

A 67-year-old right-handed woman with previously normal hearing was admitted to hospital with sudden onset of complete bilateral hearing loss. There was no dizziness, tinnitus, earache, recent upper respiratory tract infection, head injury, psychiatric disorder, or exposure to ototoxic drugs or excessive noise. Her medical his-

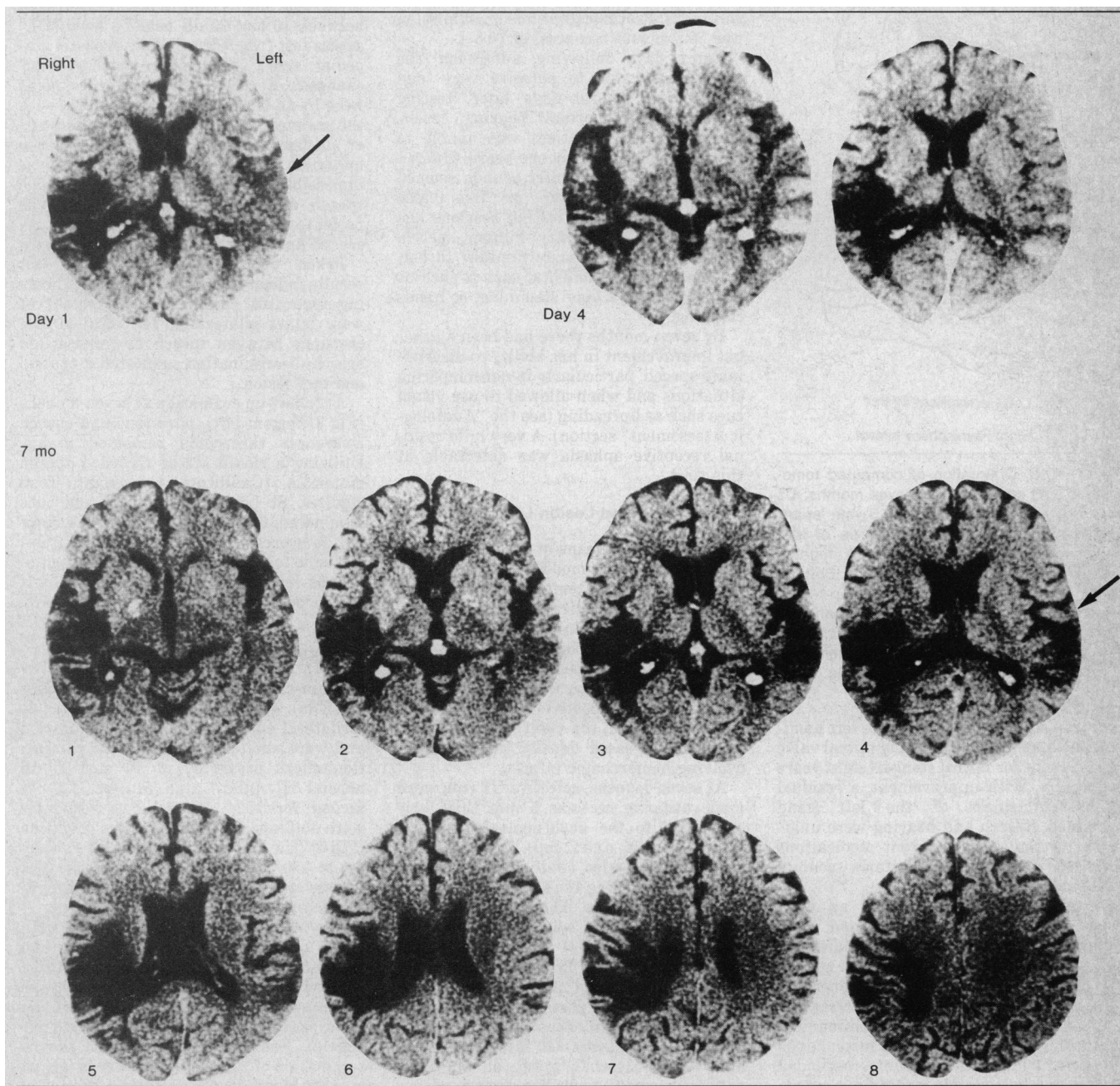


Fig 1.—Noncontrast computed tomographic scans in patient on admission (top left), at day 4 (top right), and at seven months (bottom). Arrows point to left primary auditory cortex in superior temporal gyrus. Note resolution of hypodensity in this area by seven months (hypodense is dark and hyperdense is light in shading).

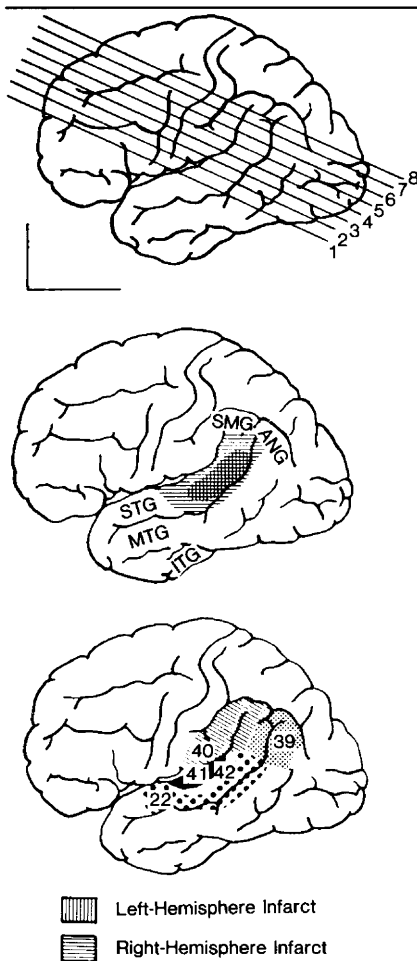


Fig 2.—Top, Orientation of computed tomographic (CT) scan slices at seven months; CT cuts are at 25° and spaced 5 mm apart. Middle, Reconstructed lateral views of left and right-sided lesions at seven months superimposed over left hemisphere. Bottom, Brodmann's cytoarchitectonic map over region of interest. ANG indicates angular gyrus; SMG, supramarginal gyrus; STG, superior temporal gyrus; MTG, middle temporal gyrus; and ITG, inferior temporal gyrus.

tory was significant for an acute left hemiparesis immediately following mitral valve replacement for mitral stenosis eight years previously. With improvement, a residual slight clumsiness of the left hand remained. Speech and hearing were unaffected at that time. Current medications included digoxin and warfarin sodium (Coumadin).

Initial examination revealed an alert oriented woman who spoke in a loud, poorly modulated voice. She gave no indication of being able to detect any words or sounds and did not startle to loud noises generated by the examiner. Ear canals were clear and tympanic membranes intact. Communication was attempted by written instructions and gesturing. The patient responded appropriately to simple written commands but inconsistently to more complex commands containing two or more steps. Spontaneous speech and oral reading were flu-

ent but contained frequent word-finding difficulties and paraphasic errors typical of mild Wernicke's aphasia. An initially noted mild right/left disorientation, acalculia, and finger agnosia resolved completely in a few days. A left homonymous visual field defect was detected. Aside from slow imprecise left hand and finger movements and a mild left hyperreflexia, the motor examination results were normal. There was astereognosis and tactile extinction of double simultaneous stimulation in the left hand. Cardiac auscultation revealed normal prosthetic valve sounds and a soft diastolic murmur. Echocardiography demonstrated a normally functioning mitral valve prosthesis, slight dilatation of the left atrium, and no evidence of thrombus. Prothrombin time on admission was 20.8 s, with a control of 10.6 s.

Eight days following admission the patient was able to perceive very loud noises, and several days later, testing revealed near normal hearing levels. Despite this, the patient was unable to make sense of anything she heard. Human voices and environmental sounds seemed "all mixed up together" or "like traffic noise." Over several testing sessions she was unable to identify human speech, musical tunes previously familiar to her, or common environmental sounds such as running water, a door slamming, or hands clapping.

By seven months there had been a gradual improvement in her ability to discriminate speech, particularly in noncompeting situations and when allowed to use visual cues such as lipreading (see the "Audiologic Assessment" section). A very mild residual receptive aphasia was detectable at this time.

CT Scan and Lesion Localization

Admission CT scans of the head (Fig 1, top left) revealed a moderately large hypodensity in the right temporoparietal cortex and adjacent subcortical white matter consistent with an old infarct. In addition, a smaller area of hypodensity was seen in the left posterior superior temporal region including Heschl's gyrus (arrow). This left-sided lesion on repeated CT scanning four days later (Fig 1, top right) demonstrated areas of increased density indicating an evolving hemorrhagic infarct.

At seven months, selective CT cuts were made utilizing sections 5 mm thick oriented 25° to the anthropologic baseline (Figs 1, bottom, and 2, top). This technique allowed for precise anatomic localization of the lesions using the templates of Gado et al¹⁴ as references. The older and larger right-sided infarct was seen to involve Brodmann's areas 41 and 42 (Heschl's gyrus), 22, 39, and 40. The smaller left-sided lesion at seven months included the majority of area 22 posteriorly and a small rim of the adjacent areas 39 and 42 (Fig 2, middle and bottom). Of interest is that area 41 of Heschl's gyrus on the left, previously noted to be hypodense on the admission CT scans, appeared to be normal in density at seven months. Other areas of the brain initially noted to be hypodense

remained so on the subsequent follow-up scan. No abnormality was seen in the brain stem on any of the CT studies.

Audiologic Assessment

Audiologic tests two days following admission revealed absence of response to pure tones and speech (Spondee word list) at the output limits of the audiometric equipment (Fig 3, top left). Tympanograms and acoustic stapedial reflex thresholds elicited by pure tone activators ranging in frequency from 500 to 4000 Hz were normal bilaterally.

A repeated audiogram 15 days following admission documented considerable improvement (Fig 3, top right). Pure tone thresholds at this time in both ears ranged between 10 and 20 dB hearing level (HL) across test frequencies, while acoustic stapedial reflex thresholds remained unchanged. Speech awareness thresholds were 15-dB HL bilaterally, consistent with the patient's pure tone thresholds. However, utilizing an open set of record speech materials (W22, lists 1B and 2B), it was impossible to obtain any measurable speech discrimination. In addition, the patient was unable to identify any recorded animal or instrumental sounds.

Taken together, the audiologic test results indicated that the peripheral hearing apparatus, cochlear, and eight nerves were intact bilaterally. The marked discrepancy between speech awareness and speech discrimination suggested a central auditory lesion.

At follow-up evaluation at seven months (Fig 3, bottom left), pure tone and speech awareness thresholds remained stable. Utilizing a closed set of recorded speech materials (California Consonant Test; Auditec, St Louis) and with visual cues eliminated, 60%- to 65%-correct discrimination scores were obtained. The patient was able to recognize a few environmental sounds (eg, telephone, doorbell, and airplane) but remained unable to recognize music.

EVOKED POTENTIAL STUDIES

Brain-stem auditory evoked responses (BAERs) were recorded with a vertex to ipsilateral earlobe electrode configuration and were elicited by broad-band rarefaction clicks presented at 70 and 80 dB normal HL (nHL) at a rate of 11.1 per second for 1024 sweeps. Two responses were obtained for each stimulus condition (Fig 4). The low- and high-pass filters were set at 150 and 3000 Hz, respectively. The patient was quietly asleep during the initial recording on day two.

The MLRs were elicited by 60-dB nHL clicks presented monaurally to left and right ears sequentially at a rate of 9.1 to 9.7 per second. The electroencephalogram was differentially amplified (40 000 times) and band-pass filtered (5 to 1500 Hz, 12 dB per octave). Each response consisted of the summation of 2000 accepted sweeps (grand average of two responses each consisting of 1000 accepted sweeps) with a duration of 102.4 ms. Responses were recorded simultaneously at three scalp locations in the

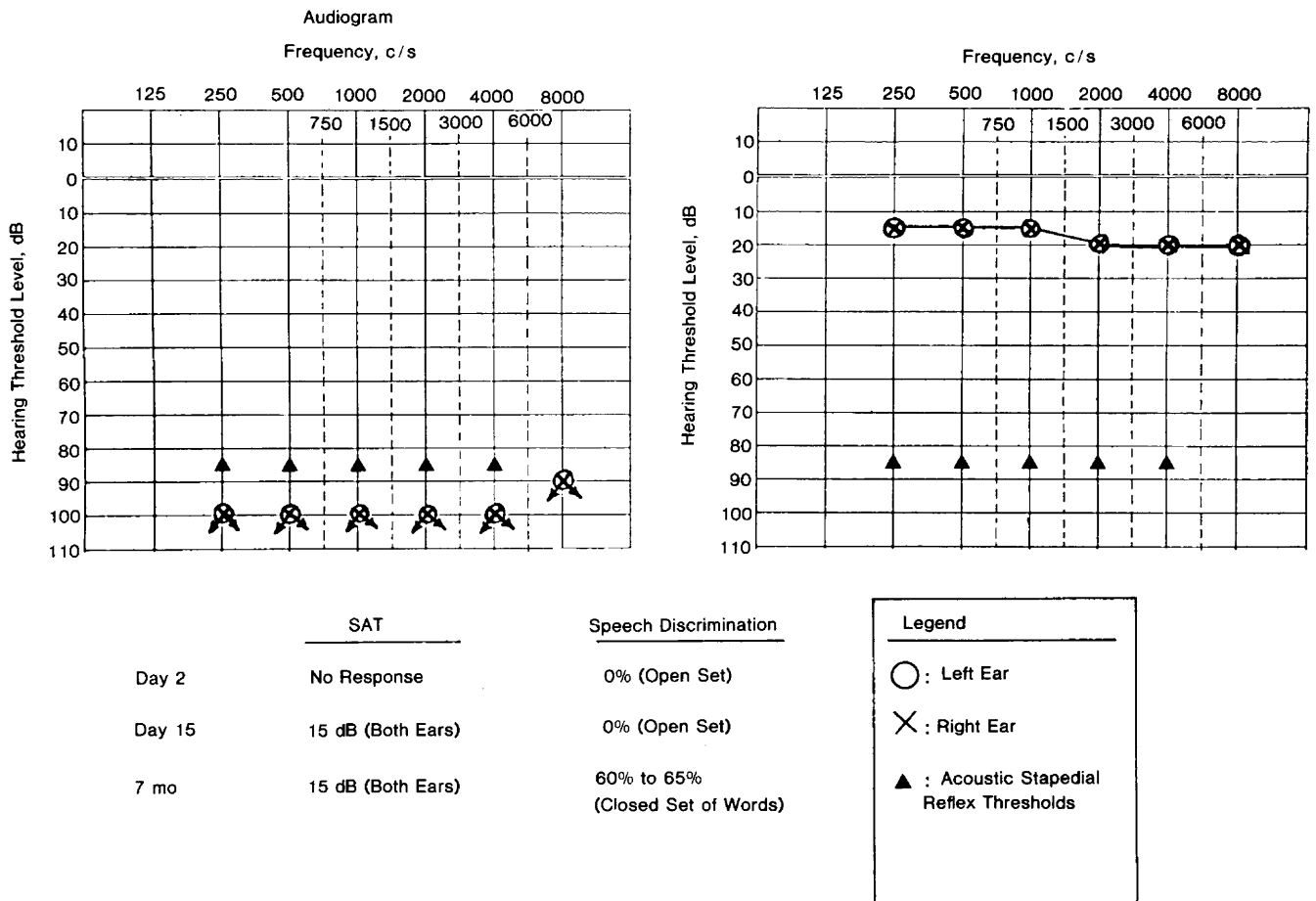


Fig 3.—Results of audiologic assessment on day 2 (top left), on day 15 (top right), and at seven months. SAT indicates speech awareness threshold.

coronal plane as follows (10- to 20-electrode system): vertex (C_2); right and left central electrodes just above the sylvian fissures (C_6 and C_5 , respectively). All active electrodes were referenced to common linked earlobe electrodes. During testing the patient was awake and resting comfortably.

For comparison purposes, Fig 5, top, illustrates MLRs elicited by left and right ear monaural stimulation from a normal subject recorded as described above. Vertex-positive peaks at 29.6 ms for left ear stimulation and 30.8 ms for right ear stimulation corresponded to the Pa component of the MLR. While the responses recorded at various electrode locations exhibited the same latency characteristics, the Pa peak amplitude was larger at the vertex than at the supratemporal electrode sites.

Mean Pa latency obtained from five neurologically normal individuals was 27.7 ± 2.1 ms SD for the left ear and 27.8 ± 2.2 ms for the right ear. Mean Pa amplitudes were 0.96 ± 0.48 μ V for the left ear and 0.94 ± 0.49 μ V for the right ear.¹¹

RESULTS

The BAERs recorded on day two in our patient are illustrated in Fig 4. The configuration and the latency measurements obtained (both inter-

peak and absolute) were within normal limits bilaterally, suggesting intact brain-stem pathways for auditory information. Subsequent BAERs recorded during convalescence utilizing the above technique as well as with simultaneous MLR recordings remained essentially unchanged.

The MLRs were first recorded 15 days following admission (Fig 5, middle). With right ear stimulation, no activity was recorded beyond the auditory brain-stem response complex over the right hemisphere and at the vertex. Over the left hemisphere, the brain-stem response complex was followed by a postauricular muscle reflex⁵ and a small (0.28 μ V) vertex-positive peak with a latency of 33 ms. This latter peak over the left hemisphere was evident with both left and right monaural stimulation and probably represented a delayed and markedly attenuated Pa component of the MLR.

The MLRs recorded at seven months (on the same date as the audiologic evaluation illustrated in Fig 3, bottom) are shown in Fig 5, bottom.

At this time a vertex-positive potential with a latency of just over 35 ms was evident at all electrode locations and was thought to represent a slightly delayed Pa component of the MLR. Its amplitude was largest (0.61 μ V) over the left hemisphere (C_2) with both left and right ear monaural stimulation.

COMMENT

The human auditory cortex is located in the posterior superior aspect of the temporal lobes bilaterally and the primary auditory cortex resides in the transverse temporal gyri of Heschl on each side. At the cortical level, hearing is bilaterally represented, although each temporal lobe receives a greater input from the contralateral ear.¹⁵ Unilateral lesions of the auditory cortex do not cause an elevation of hearing thresholds. Bilateral temporal lobe lesions, however, are known to produce a continuum of deficits ranging from auditory agnosia for speech or nonspeech sounds, with relatively normal hearing thresholds, to rare cases of cortical

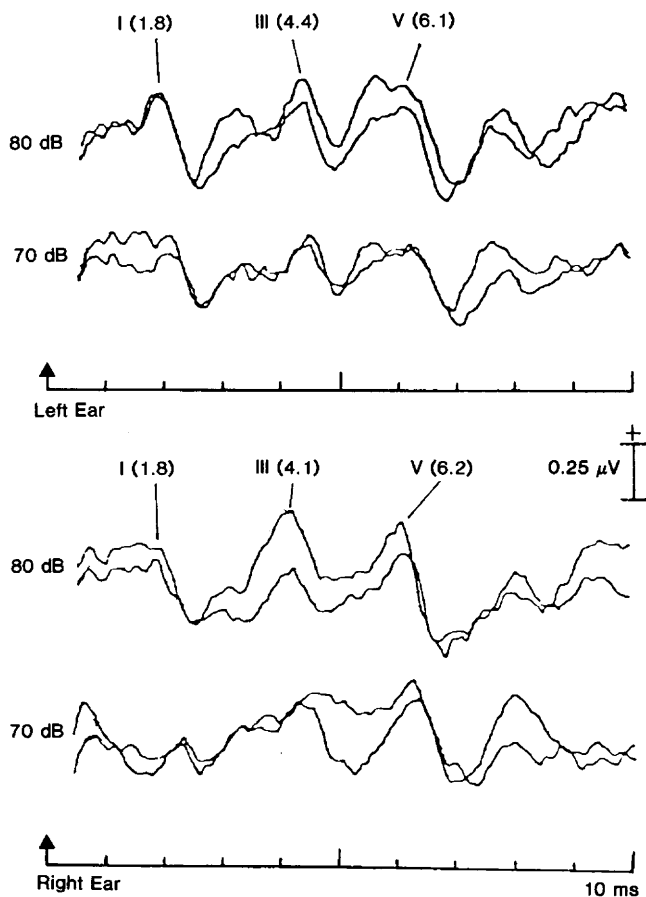
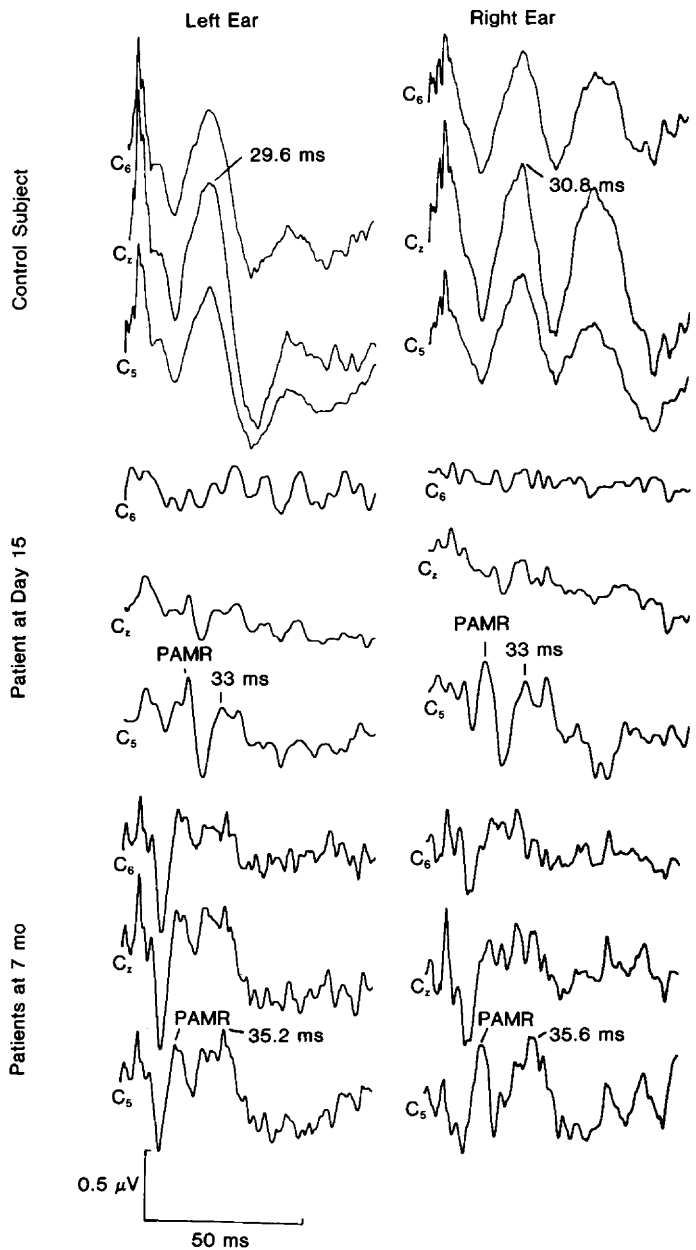


Fig 4.—Brain-stem auditory evoked responses elicited by 80-dB and 70-dB normal hearing level clicks on day 2.

Fig 5.—Middle latency auditory evoked responses with left and right monaural stimulation and recording from left central (C_2), vertex (C_z), and right central (C_6) electrodes. PAMR indicates postauricular muscle reflex.



deafness characterized by markedly elevated pure tone thresholds.¹⁶ There are over 20 well-documented cases of cortical deafness in the literature,^{13,17-26} usually the results of ischemic infarcts in both temporal lobes at different times,^{17,18,20-23,25} as in our case. A unique case of cortical deafness due to bilateral thalamic lesions has recently been published.²⁹

The patient in this report sustained an earlier right-hemispheric infarct that destroyed the primary auditory cortex but produced no apparent hearing deficit. However, following an acute left-hemispheric infarct that involved the remaining primary auditory cortex, a state of profound deafness resulted. A mild receptive aphasia

correlated with involvement of the adjacent Wernicke's area on the left. The location of the new infarct on the lower bank of the sylvian fissure, its later evolution to a hemorrhagic lesion, and the existence of a potential source of emboli from a prosthetic heart valve suggested an embolic mechanism.

The audiologic assessment including normal tympanograms, acoustic stapedial reflex thresholds, and BAERs ruled out the presence of significant middle ear, cochlear or eighth nerve, or brain-stem causes for the profound hearing impairment. The marked discrepancy between the awareness and discrimination of complex sounds including speech follow-

ing the progressive return of hearing in the second week suggested a central auditory lesion. The evolution from a state of cortical deafness (or extreme lack of awareness of any sounds) to a state of auditory agnosia for speech and environmental sounds has been noted by others.^{17,18,20,25} However, anatomic correlates of this change have not previously been demonstrated, to our knowledge.

In our patient there was a brief interval of no more than two weeks between the initial absence of any response to pure tones and speech (at the limits of the audiometric equipment) to a state characterized by normal hearing sensitivity yet marked impairment of speech recognition.

This was followed by gradually improving discrimination of both speech and environmental sounds over the ensuing weeks and months. This course of events suggests rapid and early reversibility of damage to the left primary auditory cortex but a more limited recovery in the adjacent auditory association cortex. Indeed, comparing the CT scan on admission to that obtained at seven months, one sees that the initial hypodensity in Heschl's gyrus on the left had subsequently become isodense in keeping with some return of viability to the primary auditory cortex (arrows, Fig 1, top left and bottom). This initial hypodensity likely represented edema and reversible ischemic change rather than infarction. On the other hand, persistent hypodensity noted in area 22 at seven months is taken to represent infarction in the adjacent auditory association cortex.

There has been one previously reported case²⁵ in which the authors described a patient with bilateral temporal lobe lesions in whom an initially absent cortical evoked response subsequently returned. Unfortunately, no latency measurements were reported to determine whether these were middle or long latency potentials. In our patient the Pa component of the MLR was barely detectable on the left (C₁) and absent on the right (C₂) on initial testing two weeks following the left-sided infarct and shortly after pure tone thresholds had returned to normal (15-dB HL). When MLRs were measured again at seven months, an increase in the amplitude of Pa was noted, especially over the left hemispheres (C₁), along with a slightly prolonged latency. Drawing a parallel between the improvement seen in the CT scan in Heschl's gyrus and the improvement noted in the MLR, we suspect that Heschl's gyrus (approximately Brodmann's areas 41 and 42) may be the generator site of the Pa component of the MLR. An alternative possibility is that the Pa component of the MLR originates from further afield in the auditory association cortex of area 22. This possibility is not as attractive, since the CT scan at seven months demonstrates that much of this area had been destroyed, nor is the MLR likely to arise from frontal or parietal opercular regions, association cortices, or the medial geniculate body of the thalamus, as these structures had been spared from the beginning.

Direct mapping of the human auditory cortex during operative procedures provides further support for

this localization.^{27,28} Vertex-positive potentials with a mean latency of 32.2 ± 4.1 ms, labeled P₂, were obtained with greatest consistency from recording electrodes directly over the transverse temporal gyrus (of Heschl),²⁷ whereas recording electrodes situated over the adjacent lateral surface of the superior temporal gyrus (area 22) and the frontal and parietal opercula gave rise to relatively longer latency potentials, which were labile, variable, and small. Subdurally located electrodes²⁸ recorded maximal amplitude auditory evoked responses with a major positive peak latency of 28.8 ± 0.3 ms when electrodes were placed parallel to the sylvian fissure adjacent to its halfway point corresponding to the region of Heschl's gyrus.

Our findings support the suggestion that the Pa component of the MLR in humans is a bilaterally generated response arising from the primary auditory cortex in Heschl's gyrus. It demonstrates that Heschl's gyrus is important in the basic perception of sounds, while the adjacent auditory association cortex probably mediates higher-level, more discriminatory roles in speech and sound perception. The case also demonstrates that cortical deafness can evolve over time into a state of auditory agnosia and that this change can be followed by clinical, anatomic, and electrophysiologic correlations. Additional study of clinical cases with unilateral and bilateral cortical lesions combining careful electrophysiologic techniques with precise anatomic localization using CT, magnetic resonance, or autopsy findings would help to shed further light on both the components of the middle and late latency auditory evoked responses and the cortical processing of auditory information.

References

1. Kileny P: Middle latency (MLR) and late vertex auditory evoked responses (LVAER) in central auditory dysfunction, in Pinheiro ML, Musiek FE (eds): *Assessment of Central Auditory Dysfunction, Foundations and Clinical Correlates*. Baltimore, Williams & Wilkins, 1985, pp 87-102.
2. Cohen MM, Rapin I: Evoked potential audiometry in neurologically impaired children, in Naunton R, Zerlin S (eds): *Evoked Electrical Activity in the Auditory Nervous System*. Orlando, Fla, Academic Press Inc, 1978, pp 551-572.
3. Mason SM, Mellor DH: Brainstem, middle latency and late cortical evoked potentials in children with speech and language disorders. *Electroencephalogr Clin Neurophysiol* 1984; 59:297-309.
4. Picton TW, Hillyard SA, Krausz HI, et al: Human auditory evoked potentials: I. Evaluation of components. *Electroencephalogr Clin Neurophysiol* 1974;36:179-190.
5. Kileny P: Auditory evoked middle latency responses: Current issues. *Semin Hear* 1983;

4:403-413.

6. Ozdamar O, Kraus N: Auditory middle latency responses in humans. *Audiology* 1983; 22:34-49.
7. Harker LA, Hosick E, Voots RJ, et al: Influence of succinylcholine on middle component auditory evoked potentials. *Arch Otolaryngol Head Neck Surg* 1977;103:133-337.
8. Kileny P, Dobson D, Gelfand ET: Middle latency auditory evoked responses during open-heart surgery with hypothermia. *Electroencephalogr Clin Neurophysiol* 1983;55:268-276.
9. Kraus N, Ozdamar O, Hier D, et al: Auditory middle latency responses (MLRs) in patients with cortical lesions. *Electroencephalogr Clin Neurophysiol* 1982;54:275-287.
10. Kileny P, Paccioretti D, Wilson AF: Effects of cortical lesions on middle-latency auditory evoked responses (MLR). *Electroencephalogr Clin Neurophysiol* 1987;66:108-120.
11. Michel F, Peronnet F: A case of cortical deafness: Clinical and electrophysiological data. *Brain Lang* 1980;10:367-377.
12. Parving A, Salomon G, Elberling C, et al: Middle components of the auditory evoked response in bilateral temporal lobe lesions. *Scand Audiol* 1980;9:161-167.
13. Ozdamar O, Kraus N, Curry F: Auditory brainstem and middle latency responses in a patient with cortical deafness. *Electroencephalogr Clin Neurophysiol* 1982;53:224-230.
14. Gado M, Hanaway J, Frank R: Functional anatomy of the cerebral cortex by computed tomography. *J Comput Assist Tomogr* 1979;3:1-19.
15. Sparks R, Goodglass H, Nickel B: Ipsilateral versus contralateral extinction in dichotic listening resulting from hemisphere lesions. *Cortex* 1970;6:249-260.
16. Bauer RM, Rubens AB: Agnosia, in Heilman KM, Valenstein E (eds): *Clinical Neuropsychology*, ed 2. New York, Oxford University Press Inc, 1985, pp 209-217.
17. Jerger J, Weikers NJ, Sharbrough FW, et al: Bilateral lesions of the temporal lobe. *Acta Otolaryngol* 1969;258(suppl):1-51.
18. Kanschepolsky J, Kelley JJ, Waggner JD: A cortical auditory disorder: Clinical audiologic and pathologic aspects. *Neurology* 1973;23:699-705.
19. Goldstein MN, Brown M, Hollander J: Auditory agnosia and cortical deafness: Analysis of a case with three year follow-up. *Brain Lang* 1975;2:324-332.
20. Earnest MP, Monroe PA, Yarnell PR: Cortical deafness: Demonstration of the pathologic anatomy by CT scan. *Neurology* 1977;27:1172-1175.
21. Graham J, Greenwood R, Lecky B: Cortical deafness: A case report and review of the literature. *J Neurol Sci* 1980;48:35-49.
22. Leicester J: Central deafness and subcortical motor aphasia. *Brain Lang* 1980;10:224-242.
23. Khurana RK, O'Donnell PP, Suter CM, et al: Bilateral deafness of vascular origin. *Stroke* 1981;4:521-523.
24. Tabira T, Tsuji S, Nagashima T, et al: Cortical deafness in multiple sclerosis. *J Neurol Neurosurg Psychiatry* 1981;44:433-436.
25. Kneebone CS, Burns RJ: A case of cortical deafness. *Clin Exp Neurol* 1981;18:91-97.
26. Woods DL, Clayworth CC, Knight RT, et al: Generators of middle- and long-latency auditory evoked potentials: Implications from studies of patients with bitemporal lesions. *Electroencephalogr Clin Neurophysiol* 1987;68:132-148.
27. Celesia GG: Organization of auditory cortical areas in man. *Brain* 1976;99:403-413.
28. Lee YS, Lueders H, Dinner DS, et al: Recording of auditory evoked potentials in man using chronic subdural electrodes. *Brain* 1984; 107:115-131.
29. Motomura N, Yamadori A, Mori E, et al: Auditory agnosia: Analysis of a case with bilateral subcortical lesions. *Brain* 1986;109:379-391.