

Infarction After Surgery for Focal Epilepsy: Manipulation Hemiplegia Revisited

Cathy M. Helgason, Donna Bergen, Thomas P. Bleck, Frank Morrell, and Walter Whisler

Department of Neurology, University of Illinois College of Medicine; and Rush Medical College, Chicago, IL, U.S.A.

Summary: The success of surgery for seizure focus resection depends on postoperative reduction or disappearance in number of seizures, improvement in psychosocial functioning, and low morbidity and mortality. Permanent neurologic sequelae are most often not discussed in this context. Deficits more than a superior quadrantanopsia are not expected after temporal lobectomy. Four cases of

ischemic stroke after seizure focus resection, each distant from the site of tissue removal, are reported. These are the first such radiologically documented reports of "manipulation hemiplegia." The permanent neurologic deficits are not attributed to resected tissue or edema. **Key Words:** Epilepsy—Neurosurgery—Prognosis—Temporal lobe—"Manipulation hemiplegia."

The success of surgery for seizure focus removal has usually been judged by postoperative evidence of a reduction or disappearance in number of seizures, improvement in psychosocial functioning, and low morbidity and mortality. Although of variable frequency (Cahan et al., 1984; Delgado-Escueta and Walsh, 1985; King et al., 1986; Falconer, 1953; Jensen, 1975; Maspes and Marossero, 1953; Ojemann, 1983; Penfield et al., 1961; Polkey, 1983; Spencer and Spencer, 1985) transient or long-lasting neurologic deficits after epilepsy surgery are not often discussed or, in some reports, even mentioned (Ganglberger, 1984; Goldring and Gregorie, 1984; Hahn, 1983; Hahn and Sellers, 1984; Lee et al., 1986; Penfield and Flanigin, 1950; Ravagnati et al., 1984; Ribaric, 1984; Ribaric and Sekulovic, 1984; Rossi, 1984; Walsh and Delgado-Escueta, 1984). We report four computed tomography (CT)-correlated cases of cerebral infarction after seizure focus resection with permanent neurologic deficit not attributed to resected tissue or edema.

CASE 1

A 29-year-old right-handed woman had intractable complex partial seizures since childhood and

a history of linear nevus sebaceum. In 1966, resection of <1.5 cm of the left temporal lobe tip resulted in no benefit. Fifteen years later, there were left temporal and inferior parietal EEG spike foci. An anterior left temporal lobectomy with resection backward from the temporal tip to the point of the intersection of the central sulcus with the sylvian fissure and multiple subpial transection of portions of the superior temporal gyrus, suprasylvian bank, and the supramarginal and angular gyria were performed, eliminating the electrocorticographic spike discharges. Immediately after surgery, a severe right hemiplegia was noted. No definite sensory loss was present. There was occasional stuttering. A right superior quadrantanopsia, believed to have been old was found. Postoperative CT scanning showed a new lucency in the posterior limb of the left internal capsule, not contiguous with the resection, in the territory of the anterior choroidal artery (AChA) (Fig. 1). During the ensuing months, most of the patient's deficits cleared, leaving mild clumsiness of the right hand and a right hyperreflexia.

CASE 2

A 29-year-old right-handed woman had intractable complex partial seizures, a left temporal spike focus on EEG, and preoperative magnetic resonance imaging (MRI) changes in the left temporal lobe. A left temporal lobectomy removed a low-

Received December 1986; revision accepted April 1987.

Address correspondence and reprint requests to Dr. C. M. Helgason, Director of Cerebrovascular Service, Department of Neurology, M/C 796; University of Illinois College of Medicine, 912 South Wood Street, Chicago, IL 60612, U.S.A.

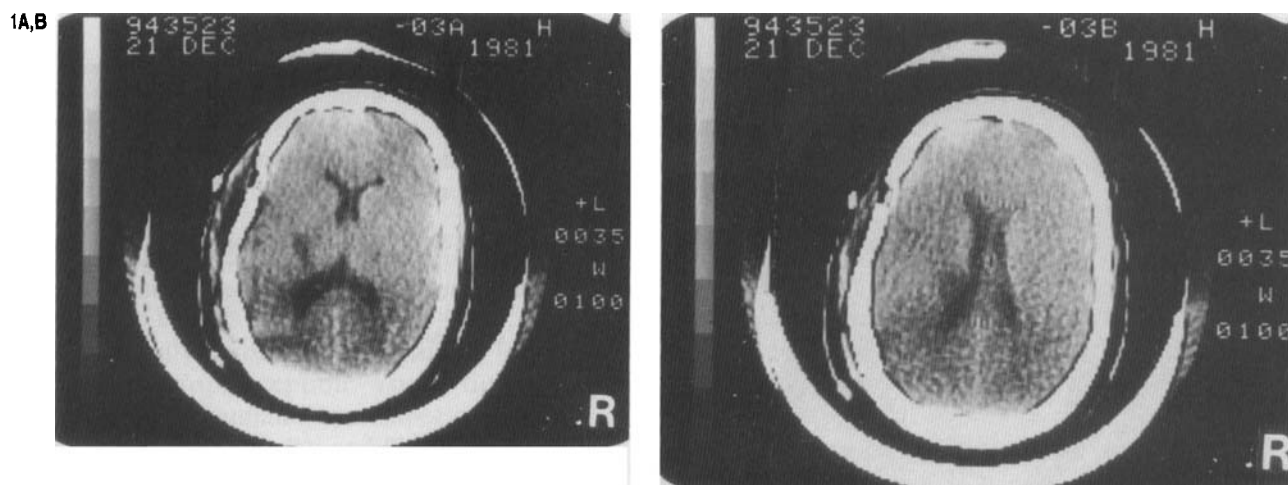


FIG. 1. Postoperative computed tomography (CT) scan of patient 1 showing lucency in (A and B) left posterior limb of the internal capsule in territory of the anterior choroidal artery (AChA).

grade astrocytoma, the inferior and middle temporal gyrus 5–6 cm backwards from and including the temporal tip, and the amygdala. Immediately after surgery, a severe right hemiplegia, right hemisensory loss, right homonymous hemianopsia with macular sparing, and a transient aphasia with anomia and mild difficulty with comprehension and preserved repetition were observed. CT scanning showed a new lucency in the posterior limb of the internal capsule and lateral thalamus in the territory of the left AChA, separate from the resection site (Fig. 2). Six weeks later, the aphasia and hemiplegia had markedly improved. A homonymous hemianopsia and mild sensory deficit remained.

CASE 3

A 17-year-old right-handed boy had a history of complex partial seizures from age 1 to 7 years, con-

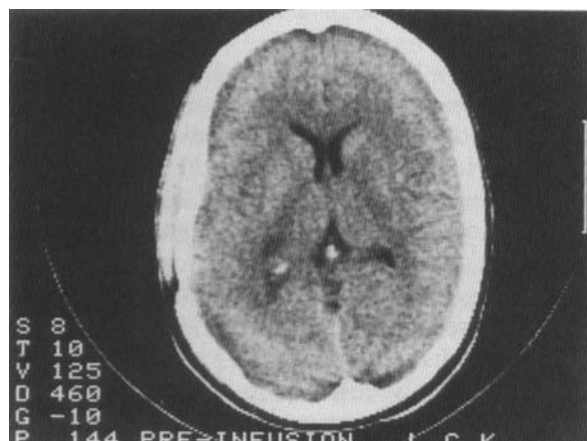


FIG. 2. Postoperative computed tomography (CT) scan of patient 2 showing lucency in left posterior limb of internal capsule and lateral thalamus in territory of the anterior choroidal artery (AChA).

trolled with phenobarbital (PB). He was seizure-free without antiepileptic drugs from age 7 to 10 years. From age 10–14 years, the patient again experienced complex partial seizures with automatisms and occasional generalization, requiring a variety of antiepileptic drugs for control. After age 14 years, his seizures became frequent and medically intractable. At age 17 years, a seizure focus resection removed 8 cm of temporal lobe backwards from the temporal tip to include the right posterior and middle temporal gyri and the hippocampus back to the posterior temporoparietal border and transection of the postcentral gyrus. Postoperatively the patient was lethargic and had a left homonymous hemianopsia and left hemiparesis involving the face and hand more than the leg. A CT scan revealed a new temporoparietal wedged-shaped lucency on the right, separate from the resected tissue area (Fig. 3). During the ensuing days, the lethargy resolved and the hemiparesis markedly improved. Nine months later, motor function was normal, but a left superior quadrantanopsia remained.

CASE 4

A 17-year-old right-handed girl had intractable complex partial seizures for 5 years. EEG studies demonstrated a left temporal spike focus. CT scanning and cerebral angiography revealed a densely calcified nonenhancing mass in the tip of the left temporal lobe. Under local anesthesia, 4 cm of lateral temporal cortex backward from and including the left temporal tip and seizure focus were removed. Postoperatively the patient had a mild right hemiparesis, word finding difficulty, difficulty with reading, and a right superior quadrantanopsia. CT

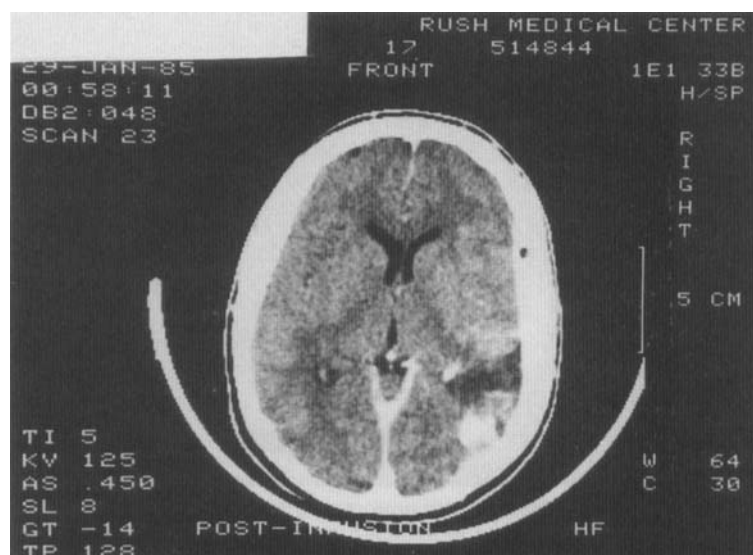


FIG. 3. Postoperative computed tomography (CT) scan of patient 3 showing wedge-shaped lucency in the right temporoparietal region in territory of middle cerebral artery (MCA) separate from the resection.

scanning revealed a new lucency in the anterior limb of the left internal capsule and basal ganglia, in the territory of the lenticulostriate branches of the middle cerebral artery (MCA) separate from the focus resection (Fig. 4). During the ensuing months, the speech difficulty and hemiparesis cleared, but the visual field deficit remained.

DISCUSSION

Postsurgical complications reported after seizure focus resection are rare. Persistent neurologic deficits more than a superior quadrantanopsia after temporal lobectomy are not expected (Falconer, 1953; Penfield, 1954).

Penfield et al. (1961) discussed intraoperative ma-

nipulation in the vicinity of certain arteries as cause for sudden hemiplegia during temporal lobectomy. Neurologic dysfunction that may occur after partial temporal lobectomy includes not only hemiplegia, but also homonymous hemianopsia, (Cahan et al., 1984; Falconer and Serafitinides, 1963; Jensen and Vaernet, 1975; Marino and Rasmussen, 1968; Ojemann, 1983; Penfield et al., 1961; Rasmussen, 1969; Spencer and Spencer, 1985; Spencer et al., 1984; Spencer, 1986) and aphasia (if the operation has been on the dominant side) (Falconer, 1953; Falconer and Serafitinides, 1963; Jensen, 1975; Jensen and Vaernet, 1975; Ojemann and Dodrill, 1985; Penfield et al., 1961; Spencer and Spencer, 1985; Spencer et al., 1984; Spencer, 1986). Sensory loss and cranial nerve palsy have been reported (Cahan et al., 1984; Jensen and Vaernet, 1975; Penfield et al., 1961; Penfield and Paine, 1955), and memory disturbance has been attributed by some (Penfield, 1954) but not solely (Ojemann, 1983) to hippocampal removal.

As noted by Penfield (Penfield, 1954), simple removal of the temporal lobe should not interfere with motor or sensory function, but the occurrence of a superior quadrantanopsia or homonymous hemianopsia depends on the size of the temporal lobe excision and its posterior extent (from the anterior end of the middle cranial fossa). Cases of hemiparesis (Penfield et al., 1961) appropriate to the side of resection after temporal lobectomy appeared after dissection near the MCA and were believed to occur secondary to vascular distortion with subsequent vasospasm and/or thrombosis, resulting in capsular infarction. Ligation of or hemorrhage from the MCA (or any other vessel) was not involved. Penfield's cases, as those of others, (Cahan et al., 1984; Jensen, 1975; Meyer et al.,

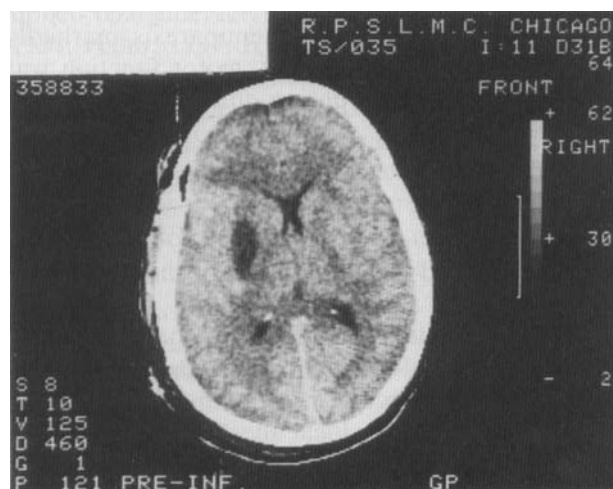


FIG. 4. Postoperative computed tomography (CT) scan of patient 4 showing lucency in left anterior limb of internal capsule and basal ganglia in territory of middle cerebral artery (MCA) lenticulostriate arteries.

1986; Ojemann, 1983; Spencer et al., 1984) had no autopsy or neuroradiologic confirmation. Our cases, confirmed by CT, show that what Penfield termed "manipulation hemiplegia" can occur not only in the MCA territory (as evidenced by cases 3 and 4), but also in the distribution of the AChA (cases 1 and 2).

Infarction in the territory of the AChA may produce a variable syndrome consisting of one or all of the following: hemiparesis (face, arm, and leg usually equally involved); hemisensory loss which may spare proprioception; visual field deficits (homonymous hemianopsia, superior quadrantanopsia, or sectoranopsia); and higher cortical function abnormalities of dominant or nondominant hemisphere types. Decreased language fluency, semantic paraphasic errors, perseveration despite preserved comprehension and repetition, dysarthria, short-term verbal and visual memory loss, visual neglect, constructional apraxia, anosognosia, and motor impersistence have all been reported (Helgason et al., 1986; Decroix et al., 1986).

Exposure of the AChA during seizure focus resection and its subsequent manipulation is not difficult to imagine in view of the course of the AChA, which passes by the optic tract, near the cerebral peduncle and the medial temporal lobe, to terminate in the lateral geniculate body (LGB) and the choroid plexus at the temporal horn (Helgason et al., 1986; Spencer and Spencer, 1985). Lende (1978) proposed manipulation as a cause of local vasospasm, which would be most prominent in those vessels closest to the carotid artery due to a gradient which may exist in the vasospastic response of vessels from the carotid distally. The AChA as well as the MCA branches would thus be likely sites of vasospasm from manipulation, especially in their proximal segments (Ojemann, 1983).

Hemiparesis and visual field changes resulting after temporal lobectomy have been conjectured to be due to MCA branch manipulation when cortex is removed both above and below the sylvian fissure or to postoperative edema (Lende, 1978; Penfield, 1954; Penfield, 1958; Penfield et al., 1961). Alternatively, it has been believed that direct damage to the internal capsule during removal of insular tissue deep within the sylvian fissure might occur (Penfield, 1954). Neither of these theories, however, would explain the thalamic involvement in our cases.

Damage to Meyer's loop, that part of the geniculocalcarine radiation which courses around the tip of the temporal horn of the lateral ventricle, is believed to account for most of the visual field changes associated with temporal lobectomy (Lende, 1978). Visual field changes are said by

these and other authors (Falconer and Wilson, 1958; Marino and Rasmussen, 1958; Penfield and Baldwin, 1952; Penfield and Paine, 1955; Spencer, et al., 1984) to occur on excision of tissue in the posterior temporal and occipital regions. Spencer and Spencer (1985), however, report that the occurrence of a homonymous hemianopsia in this setting does not correlate precisely with the amount of tissue removed. Resection in case 2 did not involve this area, and a lesion of the proximal geniculocalcarine tract or LGB as part of AChA territory infarction may be responsible for the hemianopsia.

Aphasia was attributed by Penfield and Paine (1955) to "neuroparalytic edema." We do not know which of their aphasic patients had other deficits, but this symptom may result from AChA territory ischemia secondary to involvement of thalamic, temporal lobe, or temporal isthmus white matter supplied by this artery (Helgason et al., 1986; Decroix et al., 1986).

Due to lack of pathologic or radiologic documentation, we are not certain how many of the postoperative deficits following epilepsy surgery are due to AChA territory pathology. Lindenberg (1955) proposed that AChA territory infarction could occur subsequent to AChA artery compression at the tentorial edge when increased intracranial pressure or brain edema exists. This mechanism rather than direct arterial manipulation or tissue ablation may explain infarction in this setting.

Lenticulostriate and other MCA branch territory, like AChA infarction, can cause hemiplegia (as in our cases 3 and 4). Patient 3 appears to have occluded an MCA branch. Patient 4 clearly had deep MCA involvement, which is rare after simple partial temporal lobectomy, as predicted by Penfield et al. (1961). Patients 3 and 4 had hemiparetic and visual field problems, each appropriate to the side and site of MCA branch involvement. Patient 4's aphasia, due to ischemia, is reminiscent of the symptoms that occur in deep basal ganglia hemorrhage and infarctions in this territory (Fromm et al., 1985; Hier et al., 1977; Ojemann and Heros, 1983).

In our 13-year series (1973–1986), 4 of 75 (5.3%) patients undergoing operative removal of seizure foci by procedures other than the standard temporal lobectomy including removal of the amygdala have suffered cerebral infarction. Current reports do not emphasize neurologic complications consequent to infarction when noting the success of epilepsy surgery. As postoperative CT scans may not have been systematically reviewed with this factor in mind, the cause of postoperative neurologic deficits in these patients remains obscure. Therefore, it is uncertain whether our series reflects an unusual rate of this particular (infarction) complica-

tion. As these are small infarcts, with a relatively good prognosis, they may be of minor importance when compared with the benefits of seizure control.

Penfield et al. (1961) reported a 5% incidence of postoperative manipulation hemiplegia and a 2.5% incidence of serious disability after standard temporal lobectomy. Falconer and Serafinides (1963) reported incidences of 6 and 3%, respectively. Ojemann (1983) reported a 7.5% complication rate [including transient (5%) and permanent (2.5%)] for cortical resections after standard temporal lobectomy for seizure control: the 2.5% permanent deficits were described as hemiparesis and attributed on clinical grounds to MCA manipulation. Jensen (1975) reported similar rates for postoperative neurologic deficits after temporal lobectomy for seizure resection. Other authors have noted higher rates of persistent neurologic deficit after temporal lobectomy (Polkey, 1983; Delgado-Escueta and Walsh, 1985; King et al., 1986).

Homonymous hemianopsia can cause significant disability, and avoidance of this and other complications is desirable (Spencer and Spencer, 1985). The preventive role of microsurgical technique with improved illumination, magnification, and need for minimal retraction in accessing the medial temporal structures is undefined. Its use might decrease the morbidity from seizure focus resection or might explain the lack of discussion of manipulation hemiplegia in current series reports (Ganglberger, 1984; Goldring and Gregorie, 1984; Hahn, 1983; Hahn and Sellers, 1984; Lee et al., 1986; Penfield and Flanigan, 1950; Ravagnati et al., 1984; Ribaric, 1984; Ribaric and Sekulovic, 1984; Rossi, 1984; Walsh and Delgado-Escueta, 1984) on the value and success of epilepsy surgery. On the other hand, its use may be limited by technical constraints of any given procedure. The observation by the Spencers (1985, 1986) of the unpredictability of homonymous hemianopsia, hemiplegia, and aphasia after resections extending >5.5 cm beyond the anterior temporal tip is understandable. That such deficits may not be entirely due to the amount of lateral temporal cortex ablated is now evident since AChA or deep MCA branch territory infarction may be their cause. Details of surgical technique and postoperative documentation by CT, MRI, or pathology of long-lasting neurologic deficits after surgery will clarify the cause and nature of ischemic complications after seizure focus resection.

REFERENCES

- Cahan LD, Sutherland W, McCullough MA, et al. Review of the 20 year UCLA experience with surgery for epilepsy. *Cleve Clin Q* 1984;51:313-8.
- Decroix JP, Graveleau PH, Masson M, Cambier J: Infarction in the territory of the anterior choroidal artery. A clinical and computerized tomographic study of 16 cases. *Brain* 1986; 109:1071-87.
- Delgado-Escueta AV, Walsh GO. Type I complex partial seizures of hippocampal origin: excellent results of anterior temporal lobectomy. *Neurology* 1985;35:143-54.
- Falconer M. Discussion of the surgery of temporal lobe epilepsy. *Proc R Soc Med* 1953;46:971-4.
- Falconer M, Serafinides EA. A follow-up of surgery in temporal lobe epilepsy. *J Neurol Neurosurg Psychiatry* 1963; 26:154-65.
- Falconer MA, Wilson JL: Visual field changes following anterior temporal lobectomy: their significance in relation to "Meyer's loop" of the optic radiation. *Brain* 1958;81:1-4.
- Fromm D, Holland AL, Swindell CS, Reinmuth OM. Various consequences of subcortical stroke. Prospective study of 16 cases. *Arch Neurol* 1985;42:943-50.
- Ganglberger JA. Additional new approach in treatment of temporal lobe epilepsy. *Acta Neurochir* 1984;(suppl 33):149-54.
- Goldring S, Gregorie EM. Surgical management of epilepsy using epidural electrodes to localize the seizure focus: review of 100 cases. *J Neurosurg* 1984;60:457-66.
- Hahn JF. The role of surgery in epilepsy. *Cleve Clin Q* 1983; 50:353-9.
- Hahn JF, Sellers M. Surgical techniques in relief from seizures. *Cleve Clin Q* 1984;51:307-11.
- Helgason CM, Caplan LR, Goodwin J, Hedges III, T: Anterior choroidal artery territory infarction: case reports and review. *Arch Neurol* 1986;43:681-6.
- Hier DB, Davis KR, Richardson EP, Mohr JP. Hypertensive putaminal hemorrhage. *Ann Neurol* 1977;1:152-9.
- Jensen J: Temporal lobe surgery around the world. *Acta Neurol Scand* 1975;52:354-73.
- Jensen J, Vaernet K. Temporal lobe epilepsy: follow-up investigation of 74 temporal lobe resected patients. *Acta Neurol Scand* 1975;17:90-103.
- King DW, Flanigan HF, Gallagher BB, et al. Temporal lobectomy for complex partial seizures. Evaluation, results and 1 year follow-up. *Neurology* 1986;36:334-9.
- Lee BI, Markano ON, Stewart WA, Worth RM, et al. Evaluation of patients with intractable seizures for epilepsy surgery at Indiana University Medical Center: *Indiana Med* 1986; 79:420-4.
- Lende RA. Local spasm in cerebral arteries. *J Neurosurg* 1978;17:90-103.
- Lindenberg R. Compression of brain arteries as a pathogenic factor for tissue necroses and their areas of predilection. *J Neuropathol Exp Neurol* 1955;14:223-43.
- Marino R, Rasmussen T. Visual field changes after temporal lobectomy in man. *Neurology* 1968;18:825-35.
- Maspe PE, Marossero F. Survey of 28 patients operated for temporal lobe epilepsy. *Rev Neurol* 1953;88:578-80.
- Meyer FB, Marsh WR, Laws ER, Sharbrough FW. Temporal lobectomy in children with epilepsy. *J Neurosurg* 1986; 64:371-6.
- Ojemann GA. Neurosurgical management of epilepsy: a personal perspective in 1983. *Appl Neurophysiol* 1983;46:11-8.
- Ojemann GA, Dodrill CB. Verbal memory deficits after left temporal lobectomy for epilepsy: mechanism and intraoperative prediction. *J Neurosurg* 1985;62:101-7.
- Ojemann RG, Heros RC. Spontaneous brain hemorrhage. *Stroke* 1983;14:458-75.
- Penfield W. Temporal lobe epilepsy. *Br J Surg* 1954;41:337-43.
- Penfield W. Pitfalls and success in surgical treatment of focal epilepsy. *Br Med J* 1958;1:669-73.
- Penfield W, Baldwin M. Temporal lobe seizures and the technique of subtotal temporal lobectomy. *Ann Surg* 1952; 136:625-34.
- Penfield W, Flanigan H. Surgical therapy of temporal lobe seizures. *Arch Neurol Psychiatry* 1950;64:491-500.
- Penfield W, Lende RA, Rasmussen T. Manipulation hemiplegia. *J Neurosurg* 1961;18:760-76.

- Penfield W, Paine K. Results of surgical therapy for focal epileptic seizures. *Can Med Assoc J* 1955;73:515-31.
- Polkey CE. Effects of anterior temporal lobectomy apart from the relief of seizures: a study of 40 patients. *J R Soc Med* 1983;76:354-8.
- Rasmussen T. The role of surgery in the treatment of focal epilepsy. *Clin Neurosurg* 1969;16:288-314.
- Ravagnati L, Sironi VA, Ettore G, Marossero F. Surgical management of partial epilepsies: a critical evaluation of electrical, CT scan, and pharmacologic studies of the Milan series. *Acta Neurochir* 1984;(suppl 33):139-43.
- Ribaric II. Excision of two and three independent and separate ipsilateral potential epileptogenic cortical areas. *Acta Neurochir*, 1984;(suppl 33):145-8.
- Ribaric II, Sekulovic NJ. Temporal lobectomy for epilepsy in the patients with ipsilateral extratemporal brain lesion. *Acta Neurochir* 1984;(suppl 33):133-8.
- Rossi GF. Indications, advantages, and limits of the different rationales of surgical treatment of epilepsy. *Acta Neurochir* 1984;(suppl 33):129-31.
- Spencer DD, Spencer SS. Surgery for epilepsy. *Neurol Clin* 1985;3:313-30.
- Spencer SS. Surgical options for uncontrolled epilepsy. *Neurol Clin* 1986;4:669-95.
- Spencer DD, Spencer SS, Mattson RH, et al. Access to the posterior medial temporal lobe structures in the surgical treatment of temporal lobe epilepsy. *Neurosurgery* 1984;15:667-71.
- Walsh O, Delgado-Escueta AV. Type II complex partial seizures: poor results of anterior temporal lobectomy. *Neurology (Cleveland)* 1984;34:1-13.

RÉSUMÉ

Le succès de l'exérèse chirurgicale d'un foyer épileptique se traduit par la réduction post-opératoire de la fréquence—ou par la disparition—des crises, une amélioration de l'insertion psycho-sociale, avec parallèlement faible morbidité et mortalité. Il est rare de discuter, dans ce contexte, de séquelles neurologiques permanentes. Après lobectomie temporale, une quadrantanopsie supérieure constitue le seul déficit attendu. Nous avons observé 4 cas d'infarctus cérébral ischémique après résection d'un foyer épileptogène, l'infarctus siégeant dans chaque cas à distance du champ de l'exérèse. Ces observations constituent les premiers cas documentés sur le plan radiologique d'hémiplégie post chirurgicale dans ce contexte. Le déficit neurologique permanent ne peut être rattaché ni à la résection parenchymateuse, ni à un oedème.

(P. Genton, *Marseille*)

RESUMEN

El éxito de la cirugía para la resección de un foco epiléptico depende de la reducción o desaparición del número de ataques en el periodo postoperatorio, la mejoría de la función sicosocial y la baja morbilidad y mortalidad. En general, las secuelas neurológicas permanentes no son analizadas en este tema. Déficits que superan una cuadrantonopsia superior no se tienen en cuenta después de una lobectomía temporal. Se presentan cuatro casos de infarto isquémico después de la resección de focos epilépticos y alejados del lugar del tejido extraído. Estos casos constituyen el primer informe radiológico documentado de "hemiplegia postmanipulación." Los defectos neurológicos permanentes no son atribuidos al tejido resecado o al edema.

(E. Portera-Sánchez, *Madrid*)