

## Alexia without Agraphia or Hemianopia

*Paolo Caffarra*

Department of Neurology, Fidenza/Parma, Italy

**Key Words.** Pure alexia · Reading · Nuclear magnetic resonance correlate · Cerebral haematoma

**Abstract.** The case of a right-handed man with pure alexia without hemianopia due to intraparenchymal haematoma is reported. Ct scan and nuclear magnetic resonance showed a lesion in the lateral temporo-occipital area confirming the assumption that the anatomic pathways responsible for reading run close to the lateral temporo-occipital or inferior temporal gyrus.

### Introduction

Alexia without agraphia or pure word blindness was first described by Déjerine [8] in 1892 as a result of lesions disconnecting the pathways between the occipital lobes and the temporoparietal association areas. Several other cases were reported later but it was Geschwind [10] who stressed the importance of disconnection to explain this syndrome.

Based on this assumption, any lesions preventing bilateral visual stimuli from reaching the left angular gyrus might produce alexia without agraphia. The clinical features of the syndrome generally include right-sided hemianopia but in principle no visual defects should be expected as a consequence of lesions sparing the optic tracts and radiations, the primary visual cortex, and part of the visual association areas.

Several cases of pure alexia without hemianopia have been reported [1, 2, 12–14, 16, 18, 20, 21]. However, Luhdorf and Paulson

[19] have questioned whether hemianopia was actually absent in some of these cases.

This study reports the case of a patient with pure alexia without hemianopia or colour-naming defects due to a small intraparenchymal haematoma verified by CT scan and nuclear magnetic resonance (NMR).

### Case Report

M.R., a 48-year-old right-handed man, was hospitalized in August 1984 because of progressive frontal headache lasting 3 days and sudden reading difficulties. The physical and neurological examinations upon admission were normal. In particular, no visual field defects were observed (fig. 1). The patient reported only great difficulties in reading ('I can see, I can write, but I can't read whole words') and in passing from one line to the next. His abilities in conversational speech, language comprehension, spontaneous and dictation writing were intact (fig. 2). In addition, the patient was able to read numbers and letters accurately and use a letter-by-letter decoding strategy to understand short words.



Paolo Caffarra

ALEXIA WITHOUT AGRAPHIA OR HEMIANOPIA

X Caro Arturo

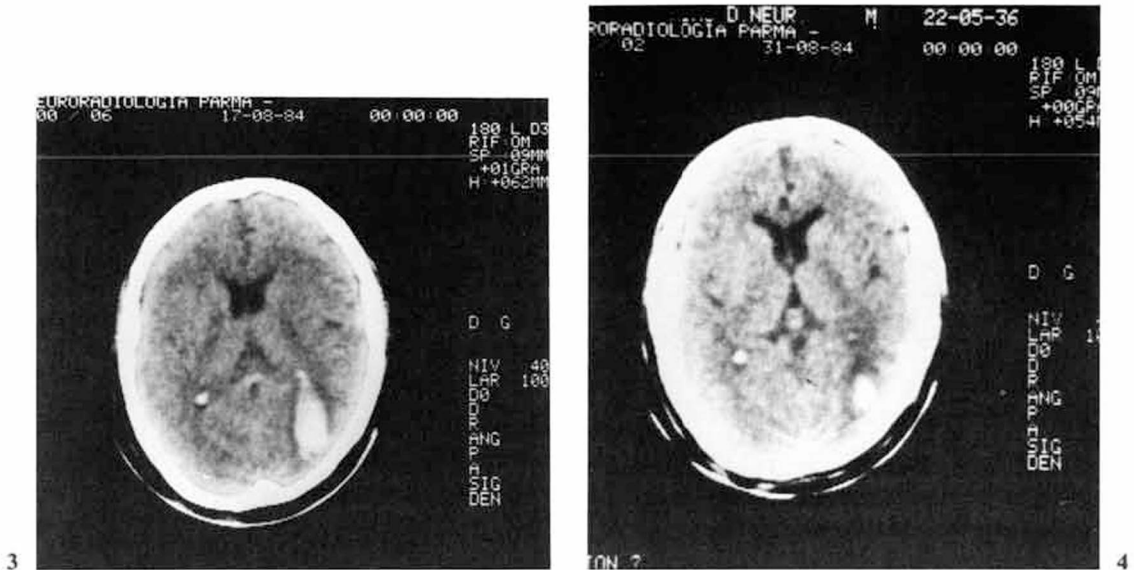
Ti scrivo questa lettera per  
informarti del mio buon stato  
di salute e così spero di te e  
famiglia.

Posso anche dirti che qui il lavoro  
non manca e perciò ti va  
abbastanza bene. E a voi come  
va, adesso chiudo sperando  
che possa venirmi a trovare.

Con attesa di salute

Rimè

Fig. 2. Spontaneous handwriting sample.



**Fig. 3.** CT scan taken 3 days after onset of symptoms, showing a left occipital haematoma with mild perifocal oedema.

**Fig. 4.** CT scan taken 17 days after onset of symptoms, showing a reduction in size of the haematoma located in the left paraventricular portion of the white matter with sparing of the corpus callosum and angular gyrus.

**Table I.** Standard neuropsychological examination

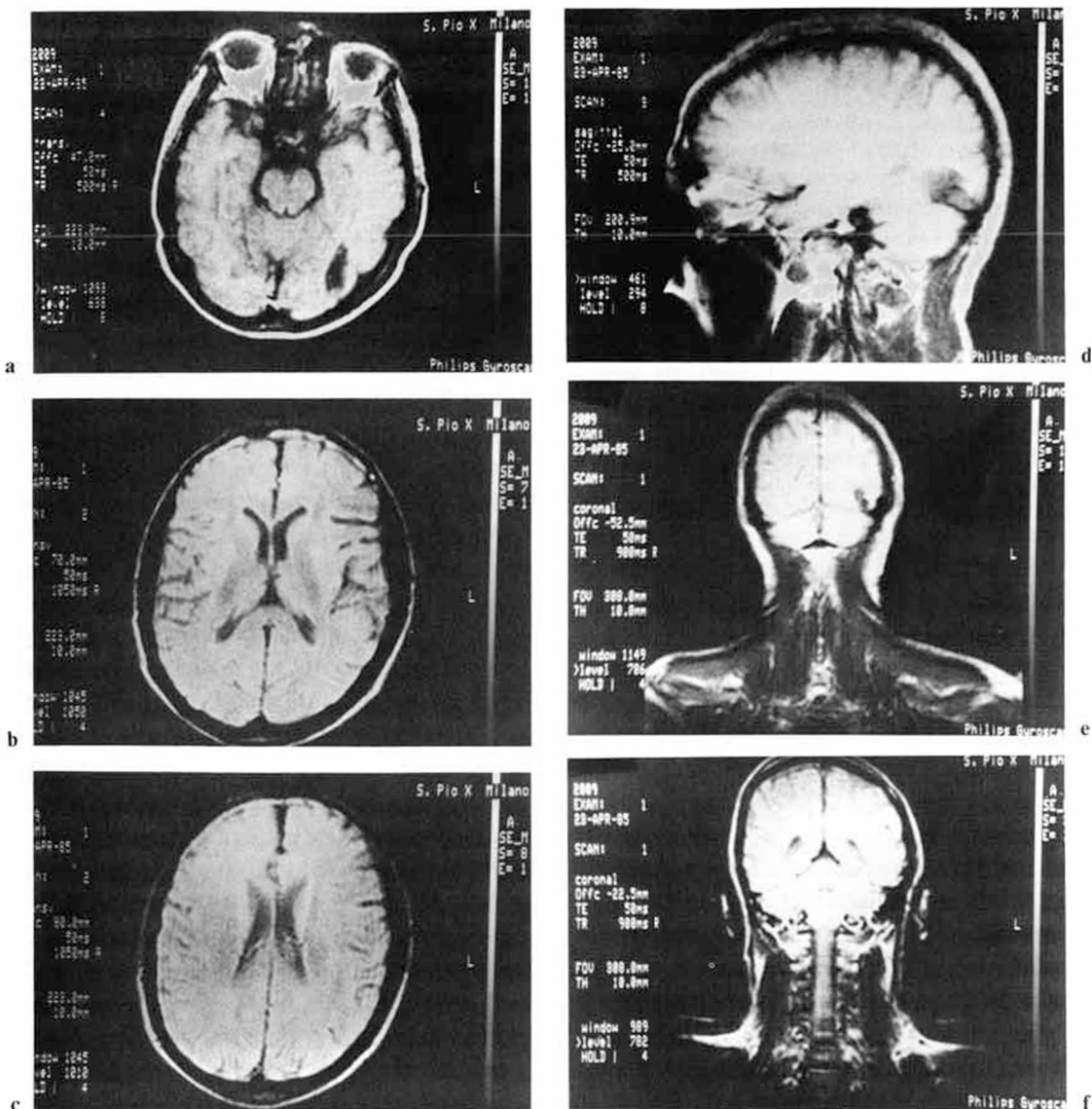
WAIS verbal	103
WAIS performance	104
WAIS total	104
WMQ	86 <sup>1</sup>
Logic memory (delayed recall)	60% <sup>1</sup>
Non-verbal memory (delayed recall)	100% <sup>1</sup>
Token test	34/36
Verbal fluency	24/36
Graphaesthesia (for single letters on the back and palm of both hand)	correct
Graphaesthesia (for bisyllabic abstract and concrete words)	
On the back	10/10
On the left hand	10/10
On the right hand	9/10
Object naming	20/20

<sup>1</sup> Wechsler Memory Scale.

**Table II.** Tachistoscopic tests

	Presenta- tion time, ms	Left	Right
Letter naming	30	25/25	25/25
Colour naming	100	12/12	12/12
Colour matching	100	12/12	12/12
Matching of non-verbal pictures	50 same different	8/10	10/10
Reading of numbers	50	12/12	12/12
Reading of trisyllables	50	6/10	4/10
Reading of bisyllables	200	1/14	0/14

The results of the tachistoscopic tests are expressed as correct responses. For each test several attempts with different target stimuli at different exposure times were made in order to obtain the best approximate performance with the lowest presentation time.



**Fig. 5.** MRI. Transverse section at three different levels: orbital plane (a); upper thalamus (b); bodies of the lateral ventricles (c). Cortical-subcortical lesion in the left lateral temporo-occipital junction without involvement of the corpus callosum, forceps major, angular gyrus and calcarine cortex, also evidenced in the left parasagittal view (d). (e, f) Coronal view (anteroposterior sequence): lacunar area involving the left lateral temporo-occipital gyrus.

#### *Laboratory Findings and Anatomic Localization*

Complete blood count, serum electrolytes and blood chemistry were all in the normal range. The ECG and EEG revealed no abnormalities. Skull X-rays were also normal.

A CT scan (fig. 3) taken 3 days after the stroke

showed a left occipital intraparenchymal haematoma. Left carotid and vertebral angiography revealed a small avascular mass in the left parieto-occipital area and no vascular malformations. A repeat CT scan taken 14 days after the first one (fig. 4) confirmed the previous findings and showed a reduction of the ha-

matoma, which now appeared to be located in the left paraventricular portion of the white matter, sparing the splenium of the corpus callosum and the left angular gyrus.

Ten months later, during a routine neurological follow-up examination, the patient was found to read normally and was submitted to magnetic resonance imaging (MRI) in order to better determine the size of the lesion and its relationship with the surrounding structures. The MRI (fig. 5) revealed a cortical and subcortical posthaemorrhagic lacuna in the posterior part of the lateral temporo-occipital gyrus. The splenium of the corpus callosum, forceps major, calcarine cortex, angular and parahippocampal gyri, thalamus and right hemisphere were intact.

## Discussion

According to the anatomical classification proposed by Greenblatt [15], alexia without agraphia can be (a) splenio-occipital with or without hemianopia; (b) lateral or medial occipital, and (c) subangular with or without hemianopia. Based on the CT scan and MRI findings, our case resembles more closely the lateral occipital form with sparing of the splenium fibres. This hypothesis seems to be confirmed by the absence of 'neighbourhood' parietal signs.

Following the classification introduced by Damasio and Damasio [7], this case could be a variety of type III, found in patients with intact visual field, without colour anomia, and with or without hemiachromatopsia. In this particular type, the lesion is located in the temporo-occipital area and includes the paraventricular portion of the white matter. The integrity of the visual field is uncommon in pure word blindness and to date only 7 cases have been reported in which anatomical classification is possible [2, 3, 5, 13, 14, 17, 21]. However, Luhdorf and Paulson [19] have pointed out that a complete visual field examination was not

taken in some other cases reported in the literature and have questioned whether hemianopsia was truly absent in those cases. In our patient visual perimetry performed 5 days after the stroke was normal and serial bedside visual field examinations taken during the acute stage showed no abnormalities. Though infrequently, normal colour perception or naming may actually be present in about 30% of the cases [11] with pure word blindness. As suggested by Damasio and Damasio [7], colour anomia probably appears under the 3 following conditions: (a) involvement of the left lingual gyrus; (b) damage to the left hippocampal region, and, (c) right-sided hemianopia. Neurological examination demonstrated that our patient had no lesions in those areas. Furthermore, it has been postulated that the absence of colour anomia may be due to the fact that the left dorsal fibres of the calcarine regions [2, 13] or even the dorsal fibres of the splenium are intact, which might actually be the case in our patient. In addition, the preserved ability to name letters or bisyllabic words by graphaesthetic stimulation in both hands and in the back indicates that the anterior part of the corpus callosum is also intact.

Based on some clinical observations and a review of the literature, Geschwind [10] suggested that some anatomic pathways from the non-dominant hemisphere might be involved in reading processes. A possible mechanism would be for the information to proceed from the right Brodmann area 17 to the ipsilateral visual association cortex and from there to the right angular gyrus and then across the corpus callosum to the left angular gyrus. A second mechanism would include fibres running from areas 18 and 19 on the right to areas 18 and 19 on the left and from there to the left angular gyrus. Finally,

Geschwind did not mention the non-homotopic interhemispheric connections which would transfer visual information from area 18 on the right to the right-sided association cortex and then to the left angular gyrus. This last mechanism is indeed possible but has not yet been demonstrated anatomically [4]. Pure alexia resulting from lesions of the left occipital lobe is usually transient in nature and Geschwind therefore concluded that the first two mechanisms were probably present and functionally independent of each other.

As regards functional anatomy, our case and that reported by Henderson et al. [17] seem to confirm this assumption and suggest that the visual connections responsible for reading run close to the lateral temporo-occipital gyrus or the inferior temporal gyrus.

### Acknowledgments

Our special thanks are due to Prof. P. Bassi and Prof. A. Mazucchi for their precious suggestions and valuable technical assistance.

### References

- 1 Adler, A.: Disintegration and restoration of optic recognition in visual agnosia. *Archs Neurol. Psychiat.* 51: 243–259 (1944).
- 2 Ajax, E.: Dyslexia without agraphia. *Archs Neurol.* 17: 645–652 (1967).
- 3 Assal, G.; Hadj-Djilani, M.: Une nouvelle observation d'alexie pure sans hémianopsie. *Cortex* 12: 169–174 (1976).
- 4 Benson, D.F.: Alexia; in *Handbook of clinical neurology*, vol. 45/1 (Elsevier, 1985).
- 5 Castro-Caldas, A.; Salgado, V.: Right hemifield alexia without hemianopia. *Archs Neurol.* 41: 84–87 (1984).
- 6 Cohen, D.; Salanga, V.; Hully, W.; Steinberg, M.; Hardy, R.: Alexia without agraphia. *Neurology* 26: 455–459 (1976).
- 7 Damasio, A.R.; Damasio, H.: The anatomic basis of pure alexia. *Neurology* 33: 1573–1583 (1983).
- 8 Déjerine, J.: Contribution à l'étude anatomo-pathologique et clinique des différentes variétés de cécité verbale. *C. r. Séanc. Soc. Biol.* 4: 61–90 (1892).
- 9 Farnsworth, D.: The Farnsworth dichotomous test for colour blindness panel D-15 manual (Psychol. Corporation, New York 1947).
- 10 Geschwind, N.: Disconnection syndrome in animals and man. Part II. *Brain* 88: 585–644 (1965).
- 11 Gloning, I.; Gloning, K.; Hoff, H.: Neuropsychological symptoms and syndromes in lesions of the occipital lobe and the adjacent areas. pp. 75–81 (Gauthier-Villar, Paris 1968).
- 12 Goldstein, M.; Joynt, R.; Goldblatt, D.: Word blindness with intact central visual fields. *Neurology* 123: 239–291 (1971).
- 13 Greenblatt, S.H.: Alexia without agraphia or hemianopia. *Brain* 96: 307–316 (1973).
- 14 Greenblatt, S.H.: Subangular alexia without agraphia or hemianopia. *Brain Lang.* 3: 229–245 (1976).
- 15 Greenblatt, S.H.: Localization of lesions in alexia; in Kertesz, *Localization in neuropsychology* (Academic Press, New York 1983).
- 16 Heilman, K.M.; Safran, A.; Geschwind, N.: Closed head trauma and aphasia. *J. Neurol. Neurosurg. Psychiat.* 34: 265–269 (1971).
- 17 Henderson, V.W.; Friedman, R.B.; Teng, E.L.; Weiner, J.M.: Left hemisphere pathways in reading: inferences from pure alexia without hemianopia. *Neurology* 35: 962–968 (1985).
- 18 Hoff, H.; Potzl, O.: Reine Wortblindheit beim Hirntumor. *Nervenarzt* 73: 385–393 (1937).
- 19 Luhdorf, K.; Paulson, O.B.: Does alexia without agraphia always include hemianopsia? *Acta neur. scand.* 55: 323–329 (1977).
- 20 Peron, N.; Goutner, V.: Alexie pure sans hémianopsie. *Revue neurol.* 76: 81–82 (1944).
- 21 Vincent, F.M.; Sadowsky, C.H. Saunders, R.L.; Reeves, A.G.: Alexia without agraphia, hemianopia, or color-naming defects: a disconnection syndrome. *Neurology* 27: 689–691 (1977).

Received: July 15, 1986

Accepted: November 19, 1986

Paolo Caffarra, MD, Department of Neurology, I-43036 Fidenza/Parma (Italy)