



Intracranial vascular stenosis in giant cell arteritis successfully treated by two balloon angioplasty procedures

Kensaku Takatsuki^a, Yuki Kojima^a, Yasuhito Ikeuchi^b, Jiro Kitayama^b, Atsushi Tanaka^a and Yasushi Inoue^{a,*}

^aDepartment of Rheumatology, Fukuoka Red Cross Hospital, Fukuoka, Japan

^bDepartment of Neurology, Fukuoka Red Cross Hospital, Fukuoka, Japan

*Correspondence: Yasushi Inoue; yinoue@fukuoka-med.jrc.or.jp; Department of Rheumatology, Fukuoka Red Cross Hospital, 3-1-1 Okusu, Minami-ku, Fukuoka 815-8555, Japan.

ABSTRACT

Intracranial vascular stenosis is rarely associated with giant cell arteritis (GCA), and the prognosis for stroke caused by GCA is poor. Despite its unfavourable outcome, the strategy to manage this involvement and the indication of endovascular treatment are not well defined in the latest guidelines or recommendations. Here, we present a case in a 68-year-old woman, which was refractory to medical therapy, but successfully treated by two balloon angioplasty procedures. She was admitted to our department with lower extremity stiffness and left visual disturbance. GCA was clinically diagnosed by the wall thickening of the temporal artery and the aorta. Hemiparesis and motor aphasia developed shortly after intravenous methylprednisolone pulse therapy, and magnetic resonance imaging revealed acute cerebral infarction with severe stenosis at the end of the left internal carotid artery. Balloon angioplasty was tried initially with improvement in her symptoms and additionally performed to treat restenosis without any significant adverse events. Her symptoms markedly improved with no recurrence until 8 months after discharge. We also review 10 similar cases reported in the literature. Although further evidence is needed to confirm the usefulness and safety of balloon angioplasty for intracranial GCA, this case report provides valuable information about the endovascular therapy for GCA.

KEYWORDS: Giant cell arteritis (GCA); intracranial vascular stenosis; balloon angioplasty

Introduction

Giant cell arteritis (GCA) is a chronic granulomatous arteritis that affects medium- to large-sized arteries and, along with Takayasu arteritis, is classified as a large-vessel vasculitis [1]. In about half of the cases, lesions are found in the aorta and its main extracranial branches such as the ophthalmic artery and external carotid artery [2]. Some 40–60% of strokes in the GCA occur in the extracranial vertebrobasilar artery system, and intracranial vessels are rarely involved [5]. The frequency of cerebrovascular disease due to intracranial vascular lesions is rare, ranging from 2.8% to 7.4% [3, 4]. The prognosis for stroke caused by GCA is generally poor, and the fatality rate is 100% with no treatment and 58% with glucocorticoids alone [5].

Balloon angioplasty is one of the endovascular therapies used to improve stenotic vessels, being an effective treatment option especially in intracranial vascular lesions that are refractory to drug therapy [6]. There are few reports about the usefulness of balloon angioplasty in intracranial GCA [5, 7–12]. Therefore, how and when to perform this procedure is not clear and not well described in the management guidelines or recommendations for GCA [13, 14].

Here, we report a case of intracranial vascular stenosis associated with GCA, which was refractory to drug therapy, but improved after two endovascular procedures. Furthermore, we review 10 similar cases reported in the literature.

Case presentation

A 68-year-old woman with a history of dyslipidaemia, hyperthyroidism in remission, and no history of smoking or diabetes mellitus type 2 was admitted to our hospital with complaints of lower extremity stiffness and left visual disturbance. Stiffness in the lower limbs appeared 2 months before admission, and C-reactive protein elevated to 10.3 mg/dl 1 month later. She visited an ophthalmologist 2 weeks before admission, due to an appearance of left visual field disturbance and decreased visual acuity. Contrast-enhanced magnetic resonance imaging (MRI) suggested an ischaemic optic neuropathy due to vasculitis; she was referred to our hospital after intravitreal administration of corticosteroids. Ultrasound showed wall thickening (halo sign) of bilateral temporal arteries (Figure 1), and contrast-enhanced computed tomography demonstrated wall thickening of the thoracic aorta (Figure 2). She was admitted to our department for further evaluation and treatment, 13 days after the onset of visual impairment.

On admission, the patient had a temperature of 36.5°C, blood pressure of 132/82 mmHg, and pulse of 82 beats/min. Consciousness was clear, the right visual field was normal, but the upper half of the left visual field was absent. General physical examination revealed tenderness in the right elbow, hip, and both knee joints. On neurological examination, she reported numbness in the lateral side of the left lower extremity without apparent motor paralysis.

Received 29 July 2022; Accepted 6 October 2022

© Japan College of Rheumatology 2022. Published by Oxford University Press.

This is an Open Access article distributed under the terms of the Creative Commons Attribution-NonCommercial License (<https://creativecommons.org/licenses/by-nc/4.0/>), which permits non-commercial re-use, distribution, and reproduction in any medium, provided the original work is properly cited. For commercial re-use, please contact journals.permissions@oup.com

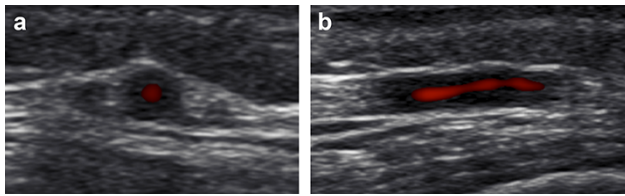


Figure 1. Ultrasonography showing wall thickening of the right temporal artery, halo sign (a, b).

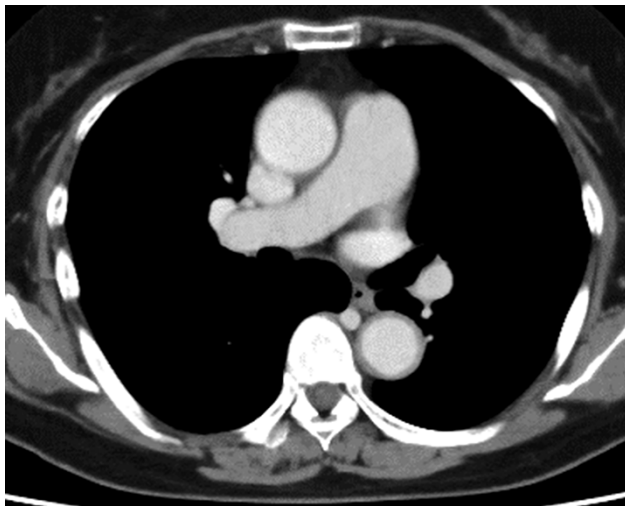


Figure 2. Contrast-enhanced computed tomography demonstrated wall thickening of the thoracic aorta.

Laboratory tests showed elevated inflammatory response with C-reactive protein level of 4.91 mg/dl and erythrocyte sedimentation rate of 73 mm/h. Antinuclear antibodies and antineutrophil cytoplasmic antibodies were negative. Her electrocardiogram sinus rhythm was normal without any evidence of atrial fibrillation. Echocardiography showed no significant abnormal findings. Ultrasonography of the carotid arteries showed no obvious findings of atherosclerosis. In the 1990 criteria for the classification of GCA [15], age and elevated erythrocyte sedimentation rate were applicable. In addition, a halo sign, regarded as the most relevant ultrasound finding in GCA, was observed on ultrasonography of the bilateral temporal arteries [16]. We made a diagnosis of GCA by the presence of above three criteria. This diagnosis was supported by the findings of contrast-enhanced MRI, which showed a contrast effect around the stenotic vessels reflecting vasculitis rather than thrombosis. A temporal artery biopsy was considered but could not be performed by the patient's refusal. Because GCA with visual loss was diagnosed, intravenous methylprednisolone pulse therapy (500 mg/body for 3 days) was promptly initiated on the day of admission (Figure 3).

On the second day, right upper limb weakness and motor aphasia appeared. Based on brain MRI and MR angiography, acute cerebral infarction due to intracranial vascular stenosis of GCA was diagnosed (Figure 4(a,b)). Dual antiplatelet therapy with aspirin (100 mg) and clopidogrel (75 mg) was started, and argatroban (60 mg) was also administered. Following intravenous methylprednisolone, oral prednisolone

(PSL) 60 mg was administered on the fourth day. Right hemiparesis developed suddenly and pre-existing aphasia worsened on the seventh day. A brain contrast-enhanced MRI showed an increase in the number of cerebral lesions and an augmentation effect in the stenotic vessel (Figure 4(c,d)). Although the high-intensity lesions on diffusion-weighted image were relatively small (Figure 4(d)), arterial spin labelling on MRI and single photon emission computed tomography (SPECT) studies showed reduced perfusion signals in the wide range of the left middle cerebral artery (MCA) territories (data not shown). This diffusion-perfusion mismatch is considered as an opportunity for improvement in cortical function; immunosuppressant therapy was reinforced with methotrexate (MTX). However, her symptoms gradually worsened under medical therapy; we decided to perform an urgent endovascular treatment. We considered intensifying treatment with the interleukin-6 receptor antagonist, but were concerned that it would mask one of the few therapeutic indicators by completely suppressing the C-reactive protein production. Cerebral angiography showed severe stenosis from the end of the left internal carotid artery to the origin of the left MCA, with delayed antegrade contrast filling (Figure 5(a)). A Gateway 1.5 mm × 9 mm (Boston Scientific) angioplasty balloon was inflated twice at the left MCA stenosis and once at the left internal carotid artery stenosis. Post-angioplasty angiographic images showed disappearance of the contrast delay and marked improvement in the delineation of the left MCA cortical branch (Figure 5(b)). The procedure was completed without any significant adverse events. Her symptoms were markedly improved with mild residual aphasia and paralysis.

Post-operative MRI on the 25th day showed no new cerebral lesions, but a follow-up SPECT on the 29th day revealed asymptomatic hypoperfusion in the left MCA region, suggesting restenosis of the treated vessels. Although blood tests were negative for C-reactive protein, we considered that restenosis appeared due to the remaining inflammation in the restricted area of the intracranial vessels. Despite intravenous methylprednisolone pulse therapy for an additional 3 days, mild consciousness disturbance with worsening of aphasia developed on the 36th day. Cerebral angiography showed restenosis of the vessels at the initial treatment site, as expected. Balloon angioplasty was repeated and successfully performed without any apparent adverse events. She was discharged home after tapering the corticosteroid dose, on the 60th day. The National Institutes of Health Stroke Scale was improved to 2 (at discharge) from 4 points (onset of stroke). At least until her follow-up visit, 8 months after discharge, she has had no recurrence of vascular stenosis due to GCA.

Discussion

Cerebrovascular attacks (CVAs) due to intracranial vascular lesions in GCA are considered rare compared with other complications. The frequency of CVAs with biopsy-proven GCA was reported to be as low as 2.8% in 287 patients by Gonzalez-Gay *et al.* and 7.4% in 175 patients by Neshar *et al.* [3, 4]. In addition, patients with stroke caused by GCA often have a poor prognosis. A review of the literature by Alsolaimani *et al.* found that among 47 patients with GCA complicated by CVAs, two untreated patients died

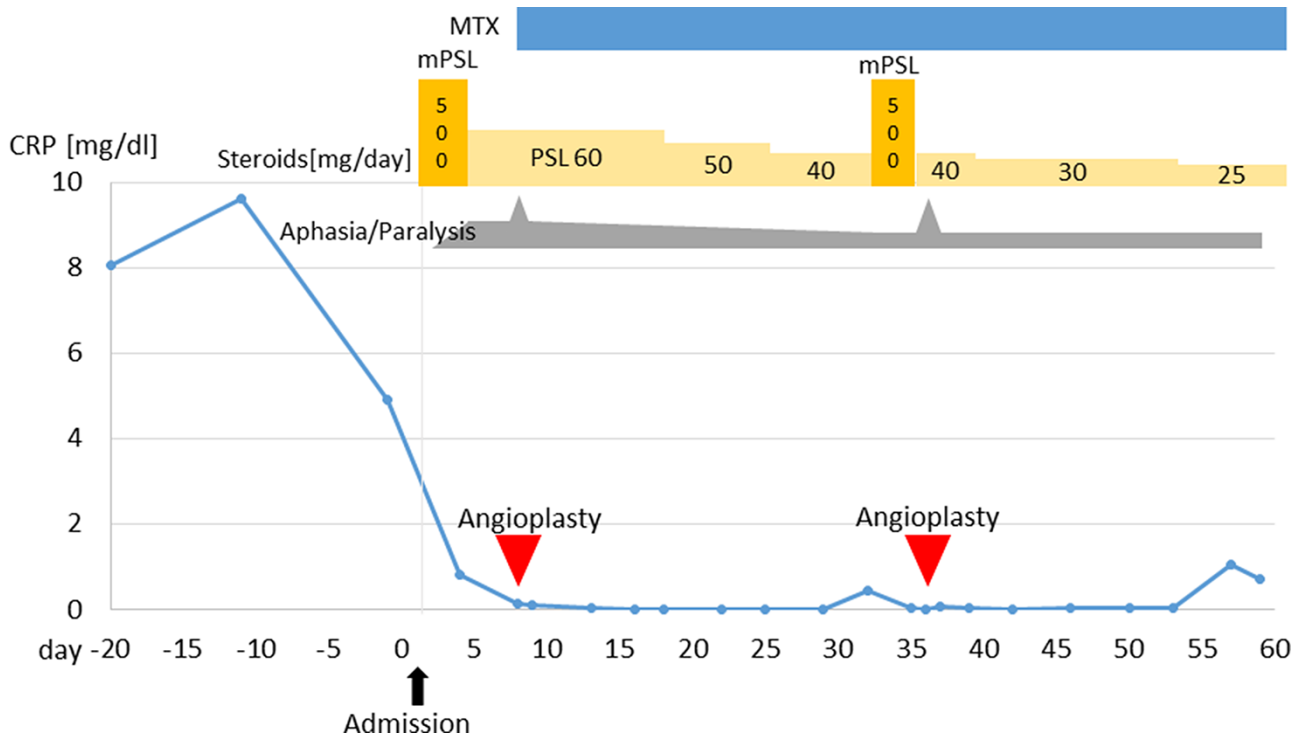


Figure 3. The clinical course of the case; the date of admission was set as the first sick day.

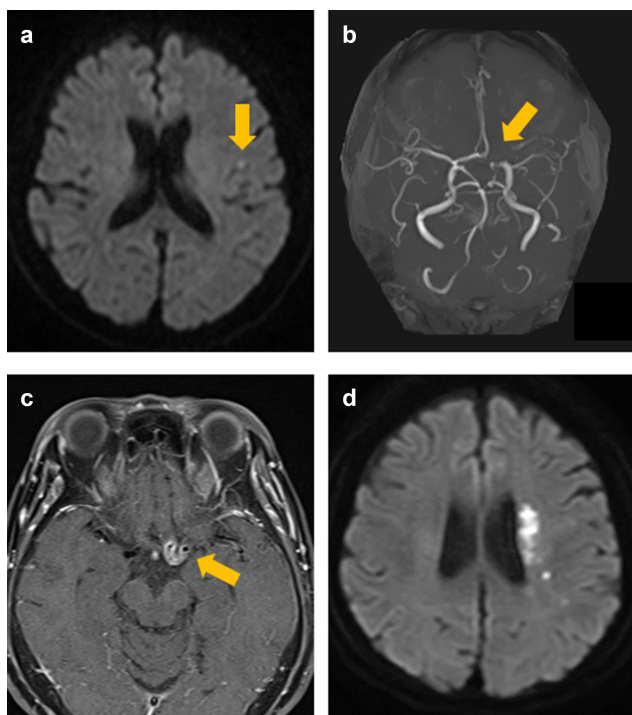


Figure 4. (a) Diffusion-weighted image (DWI), ischaemic lesion in the cerebral cortex of the left frontal lobe (Day 2); (b) MR angiography, severe stenosis from left internal carotid artery end to left MCA origin (Day 2); (c) contrast-enhanced T1-weighted image, augmentation effect corresponding to the vascular stenosis (Day 2); (d) DWI, the increase of ischaemic lesions (Day 7).

of exacerbations of CVAs within 2–5 days, and that 58% of patients treated with glucocorticoids alone died within a median of 10 days [5].

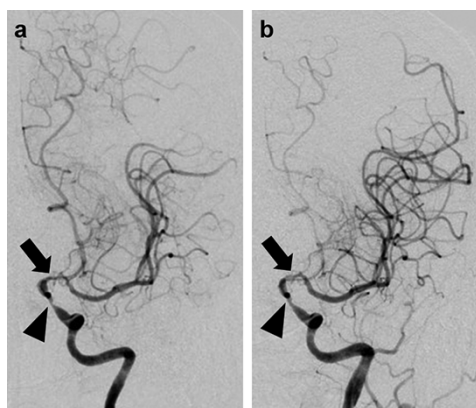


Figure 5. Antero-posterior view of digital subtraction angiography showing 69% stenosis in the distal left intracranial artery (arrowhead) and 84% stenosis in the left middle cerebral artery (arrow) before the first endovascular treatment (a); after the endovascular treatment, improved blood flow in distal left MCA was seen (b).

Although there are no treatment guidelines or clinical studies with a high level of evidence for the management of intracranial GCA, it is generally accepted that, as with general GCA, glucocorticoids should be the mainstay of treatment, followed by MTX or biological agents as needed [13, 14]. Aspirin antiplatelet therapy can reduce the risk of complications due to ischaemia [14]. Neshier *et al.* reported that after diagnosis and steroid therapy, patients receiving low-dose aspirin (100 mg) had a reduced frequency of cranial ischaemic complications from CVAs with an odds ratio of 0.18 compared with those who did not ($p = .03$) [17]. Balloon angioplasty is an endovascular treatment used to improve stenotic vessels and is an option for intracranial vascular lesions, especially when they are refractory to medication or

Table 1. Characteristics of 11 patients who underwent endovascular treatments for intracranial GCA.

Authors	Age (years)	Sex	Site of stenotic vessels	IV mPSL	Oral PDN/PSL	MTX	CPA	Others	APT	Stenting	Number of treatments	Number of vessels treated	Time between the date of initiation of medical therapy and the first stroke	Time between first stroke and treatment	Complication
Chausson et al.	78	F	Bilateral ICAs	(+)	(+)	(-)	(-)	(-)	(+)	(+)	1	2 (left ICA, right ICA)	19 days	26 days	(-)
Dementovych et al.	NA	NA	Bilateral VAs	(+)	(+)	(-)	(-)	AZP	(+)	(+)	1	2 (left VA, right VA)	2 months	3 weeks	(-)
Guerrero et al.	59	NA	Bilateral ICAs	(+)	(+)	(+)	(-)	(-)	(+)	(+)	1	2 (Left ICA, left distal M1)	0 day	12 days	(-)
Neutel et al.	65	M	Bilateral ICAs, VAs, BA	Only oral PDN	(+)	(+)	(-)	ASA	(+)	(-)	1	1 (left ICA)	3 months	1 month	(-)
Alsolaimani et al.	66	F	Bilateral ICAs	(+)	(+)	(-)	(+)	(-)	(+)	(-)	1	1 (left ICA)	NA	NA	(-)
Togo et al.	80	F	Bilateral VAs, right ICA	(+)	(+)	(-)	(+)	(-)	(+)	(-)	1	1 (right VA)	NA	28 days	(-)
Simonsen et al.	65	F	Bilateral ICAs	(+)	(+)	(-)	(+)	TCZ	NA	(-)	2	1 (left ICAx2)	0 day	10 days	(-)
Simonsen et al.	64	F	Bilateral ICAs	(+)	(+)	(-)	(+)	(-)	NA	(-)	3	2 (left ICAx3, right ICAx2)	2 days	2 days	Small dissection
Simonsen et al.	72	M	bilateral ICAs, left VA	(+)	(+)	(+)	(+)	(-)	NA	(-)	2	3 (left ICAx2, right ICAx1, left VAx1)	0 day	2 weeks	(-)
Simonsen et al.	71	F	Bilateral ICAs, left VA	(+)	(+)	(+)	(+)	(-)	NA	(-)	2	3 (left ICAx2, left VA x1)	0 day	Acute treatment	Small dissection
Takatsuki et al.	68	F	Left ICA, MCA	(+)	(+)	(+)	(-)	(-)	NA	(-)	2	2 (left MCAx2, left ICAx2)	2 days	7 days	(-)

IV mPSL, intravenous methylprednisolone; PDN, prednisone; CPA, cyclophosphamide; APT, antiplatelet therapy; AZP, azathioprine; ASA, aminosalicylic acid; TCZ, tocilizumab; ICA, internal carotid artery; VA, vertebral artery; BA, basilar artery; NA, not available.

when symptoms due to cerebrovascular disease are progressive [6], but few patients have undergone balloon dilation for intracranial vascular stenosis in GCA [5, 7–12] (Table 1), and it is unclear what types of lesions should be treated by balloon angioplasty. Especially with regard to GCA, the European Alliance of Associations for Rheumatology 2018 recommendation is that endovascular therapy should be performed in stable remission, while it is not contraindicated in emergent situations presenting neurological complications such as stroke. The American College of Rheumatology 2021 guideline also conditionally recommends surgical intervention with intensified immunosuppressive therapy in cases of worsening symptoms of organ ischaemia for patients already on immunosuppressive therapy [13, 14]. These recommendations are because invasive treatment in the active phase can lead to vascular complications. Asymptomatic vascular dissection occurred in two previous cases when the interval between the onset of stroke and endovascular treatment was short [8]. Although angioplasty should preferably be performed when inflammation has settled, it should be considered in urgent cases such as the following; poor response to immunosuppressive therapy, when there is a high probability of serious aftereffects due to stroke, and especially when restenosis occurs after angioplasty.

In order to examine the efficacy and safety of angioplasty for intracranial GCA, we found 10 previously reported cases and summarised them in Table 1 [5, 7–12]. The median age of the patients was 67 years, ranging from 59 to 80 years, and so, many of them were elderly, as is the case with GCA in general. The site of stenosis was the internal carotid artery system in five cases, the vertebrobasilar artery system in one case, and duplication in five cases, and 90.9% of cases showed stenosis of the internal carotid artery. Glucocorticoids were administered in all cases, and immunosuppressive drugs such as MTX and cyclophosphamide were also used in almost all cases. Antiplatelet therapy was administered in all patients whose cases were reported in the literature. Multiple angioplasties were required in 5 of the 11 patients, and 7 of the 11 patients had multiple vessels treated. The time from the start of medical treatment to the stroke onset due to GCA varied from 2 days to 3 months, except for patients whose medical treatment was started on the day of stroke onset. The interval from the onset of infarction to angioplasty was generally from 1 week to 1 month, and most patients underwent angioplasty after medical treatment was attempted, while 2 patients underwent angioplasty within 2 days. Both patients had an asymptomatic small dissection; therefore, angioplasty immediately after the onset of a cerebral infarct seemed to be associated with a higher risk of complications [8].

The efficacy and safety of endovascular treatment for cerebral infarction is generally considered to be high with a low risk of complications. The combined periprocedural stroke and death rate within 30 days was 5.8%, and the annual stroke recurrence rate in the treated area was 3.2%, in 120 patients after endovascular treatment for intracranial stenosis [18]. Although restenosis of the treated area is a problem associated with balloon angioplasty, multiple balloon dilations are considered to have been effective for our patient and in previous cases of GCA [8]. Dissection after this procedure for intracranial stenosis is another problem and has been reported to occur in 13.8% by meta-analysis of 25 clinical studies [6]. Asymptomatic dissections occurred in 2 (18.2%)

of 11 patients with GCA (Table 1), and the proportion is consistent with that of the meta-analysis [8]. From comparing previous studies with our case review, we consider that balloon angioplasty for intracranial GCA, as well as for intracranial atherosclerotic diseases, can be a safe and effective treatment option, although data are limited and further studies are needed to support this.

Conclusion

Even though intracranial GCA has a poor prognosis, the treatment recommendations for this rare disease are not well defined. Here, we reported a case in a patient with an intracranial GCA successfully treated with two endovascular treatments and reviewed similar cases reported in the literature. There was restenosis of the treated vessels in our patient; thus, this case may suggest that adequate immunosuppressive therapy is needed even if balloon angioplasty was performed.

Conflict of interest

None declared.

Funding

None declared.

Patient consent

We obtained written informed consent from the patient for the publication of this report. The signed consent form is retained by the corresponding author.

Ethical approval

Not applicable.

References

- [1] Salvarani C, Cantini F, Boiardi L *et al.* Polymyalgia rheumatica and giant-cell arteritis. *N Engl J Med* 2002;347:261–71.
- [2] Gonzalez-Gay MA, Vazquez-Rodriguez TR, Lopez-Diaz MJ *et al.* Epidemiology of giant cell arteritis and polymyalgia rheumatica. *Arthritis Rheum* 2009;61:1454–61.
- [3] Gonzalez-Gay MA, Vazquez-Rodriguez TR, Gomez-Acebo I *et al.* Strokes at time of disease diagnosis in a series of 287 patients with biopsy-proven giant cell arteritis. *Medicine (Baltimore)* 2009;88:227–35.
- [4] Neshar G, Berkun Y, Mates M *et al.* Risk factors for cranial ischemic complications in giant cell arteritis. *Medicine (Baltimore)* 2004;83:114–22.
- [5] Alsolaimani RS, Bhavsar SV, Khalidi NA *et al.* Severe intracranial involvement in giant cell arteritis: 5 cases and literature review. *J Rheumatol* 2016;43:648–56.
- [6] Kadooka K, Hagenbuch N, Anagnostakou V *et al.* Safety and efficacy of balloon angioplasty in symptomatic intracranial stenosis: a systematic review and meta-analysis. *J Neuroradiol* 2020;47:27–32.
- [7] Togo M, Kono T, Hoshi T *et al.* Successful endovascular therapy for multiple intracranial arterial stenosis associated with medically intractable giant cell arteritis. *J Neurol Sci* 2018;384:104–6.

- [8] Simonsen CZ, Speiser L, Hansen IT *et al.* Endovascular treatment of intracerebral giant cell arteritis. *Front Neurol* 2020;11:1–5.
- [9] Chausson N, Olindo S, Signaté A *et al.* Bilateral intracerebral angioplasty in a patient with stroke caused by giant cell arteritis. *Rev Neurol (Paris)* 2010;166:328–32.
- [10] Dementovych N, Mishra R, Shah QA. Angioplasty and stent placement for complete occlusion of the vertebral artery secondary to giant cell arteritis. *J Neurointerv Surg* 2012;4:110–3.
- [11] Guerrero AM, Sierra-Hidalgo F, Calleja P *et al.* Intracranial internal carotid artery angioplasty and stenting in giant cell arteritis. *J Neuroimaging* 2015;25:307–9.
- [12] Neutel D, Biscoito L, Campos J *et al.* Giant cell arteritis with symptomatic intracranial stenosis and endovascular treatment. *Neurol Sci* 2014;35:609–10.
- [13] Maz M, Chung SA, Abril A *et al.* 2021 American College of Rheumatology/Vasculitis Foundation Guideline for the management of giant cell arteritis and Takayasu arteritis. *Arthritis Care Res* 2021;73:1071–87.
- [14] Hellmich B, Agueda A, Monti S *et al.* 2018 Update of the EULAR recommendations for the management of large vessel vasculitis. *Ann Rheum Dis* 2020;79:19–130.
- [15] Hunder GG, Bloch DA, Michel BA *et al.* The American College of Rheumatology 1990 criteria for the classification of giant cell arteritis. *Arthritis Rheum* 1990;33:1122–8.
- [16] Dejaco C, Ramiro S, Duftner C *et al.* EULAR recommendations for the use of imaging in large vessel vasculitis in clinical practice. *Ann Rheum Dis* 2018;77:636–43.
- [17] Neshet G, Berkun Y, Mates M *et al.* Low-dose aspirin and prevention of cranial ischemic complications in giant cell arteritis. *Arthritis Rheum* 2004;50:1332–7.
- [18] Marks MP, Wojak JC, Al-Ali F *et al.* Angioplasty for symptomatic intracranial stenosis: clinical outcome. *Stroke* 2006;37:1016–20.