

CASE REPORT

Open Access



# Quantitative indices for an intracranial aneurysm and subarachnoid hemorrhage in early childhood: a case report

Kenichi Tetsuhara<sup>1,2,3</sup>, Noriyuki Kaku<sup>1,2\*</sup> , Koichi Arimura<sup>4</sup>, Yasunari Sakai<sup>1</sup> and Shouichi Ohga<sup>1</sup>

## Abstract

**Background:** Intracranial aneurysms (ICA) rarely occur in children under 3 years of age. Little is known for neuroimaging parameters that predict survival and clinical outcomes of patients with ICA in early childhood.

**Case presentation:** A 2-year-old girl showed intracranial hemorrhage due to a rupture of aneurysm at the middle cerebral artery. Quantitative measurements of ischemic damages on the head computed tomography (CT) marked an extremely low score of 2 points with modified Alberta Stroke Program Early CT Score (mASPECTS). She died 15 days after admission. In publications from 2021 to 2022, we found 21 children who were under 3 years of age at onset of ICA. None of them died, but two of three patients who had mASPECTS scores 0–8 showed developmental delay and/or epilepsy as neurological complications.

**Conclusion:** Early CT findings are applicable for predicting survival and neurological outcomes of young children with intracranial hemorrhage.

**Keywords:** Intracranial aneurysm, Modified Alberta stroke program early CT score (mASPECTS), Outcome, And children

## Background

Intracranial aneurysm (ICA) is a rare condition in children under 3 years of age [1, 2]. Infections, post-traumatic, and specific genetic conditions are more frequently associated with ICA and ICA-related brain hemorrhages in childhood than those in adults [3]. However, only a few reports have demonstrated details in neuroimaging features and clinical outcomes of patients with ICA in early childhood [4, 5]. Two neuroimaging parameters, simplified gray matter attenuation-to-white matter attenuation ratio (sGWR) and modified Alberta stroke program early CT score (mASPECTS), are known to be

useful for quantitatively analyzing parenchymal damages of the brain in children with cardiac arrest [6]. We thus asked whether these scoring systems might also provide critical values for the outcome of ICA in early childhood.

We herein report a young child who had a rupture of ICA at the middle cerebral artery (MCA) and characterize the neuroimaging feature of this patient in comparison with previously reported children under age 3 years.

## Case presentation

A 2-year-and-8-month-old girl was referred to the previous hospital because of altered consciousness. A head computed tomography (CT) indicated the urgent neurosurgical intervention for the intracranial hemorrhage with a midline shift. On arrival to our hospital, spontaneous breathing was absent, and Glasgow Coma Scale was evaluated to be E1V1M1. The contrast-enhanced CT in our hospital confirmed the hemorrhage

\*Correspondence: kaku.noriyuki.198@m.kyushu-u.ac.jp

<sup>2</sup> Emergency and Critical Care Center, Kyushu University Hospital, 3-1-1, Maidashi, Higashi-ku, Fukuoka 812-8582, Japan

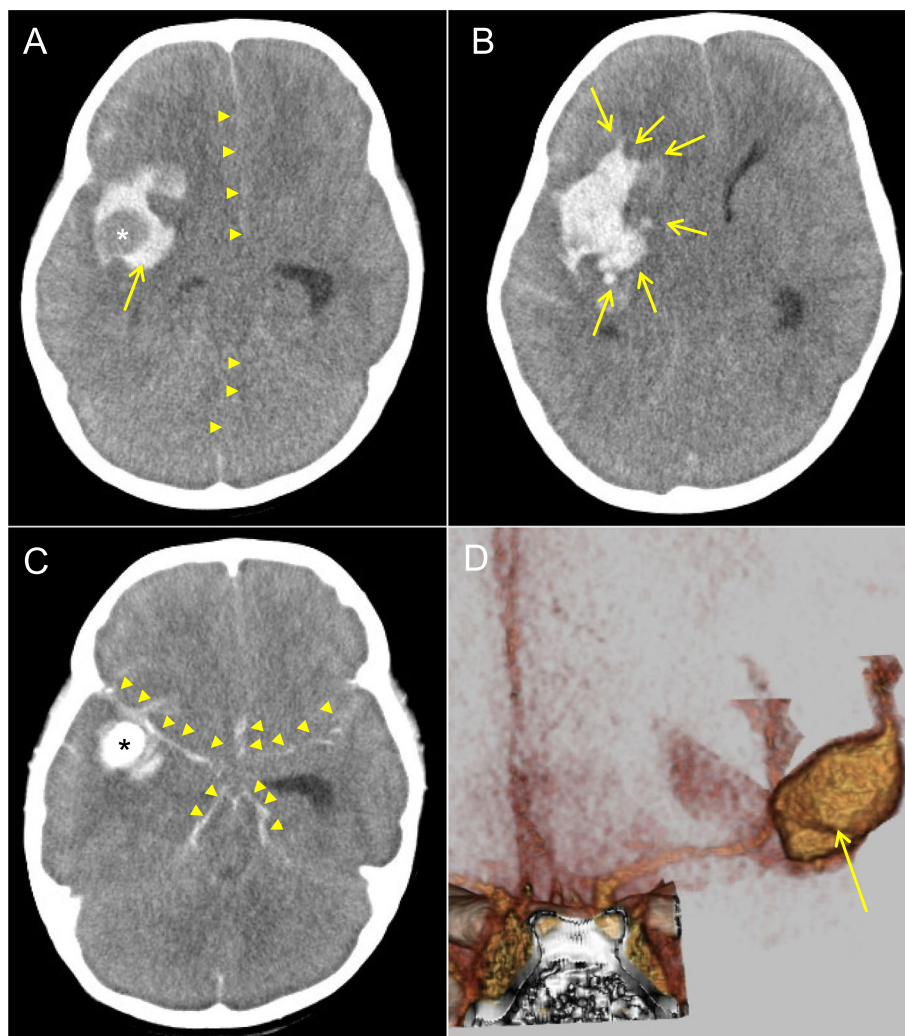
Full list of author information is available at the end of the article



extending to the subarachnoid space and disclosed an aneurysm of  $21 \times 13 \times 12$  mm at the right MCA (Fig. 1). We applied quantitative measurements of the sGWR and mASPECTS (range 0–24) for her neuroimaging data (Fig. S1). The modified sGWR scored 1.13, while mASPECTS gained only 2 points, both suggestive of poor prognosis [6]. Although decompressive surgery was immediately performed, her systemic conditions became unstable with uncontrollable pulmonary edema. She died on the 15th day after admission. The panel sequencing for *COL3A1*, *FBN1*, *TGFBR1*, *TGFBR2*, and *RNF213* excluded the diagnosis of Ehlers-Danlos syndrome,

Marfan syndrome, Loeys-Dietz syndrome, and Moyamoya disease. Blood culture was negative throughout the treatment course. Systemic imaging studies excluded malformation of great arteries, renal cysts, and tumors.

Through the literature search from 2021 to April 2022 in PUBMED (<https://pubmed.ncbi.nlm.nih.gov/>), we found 103 publication records with search terms, “intracranial”, “aneurysms” and “pediatric”. Among them, 21 patients were reportedly under 3 years of age (12 females; 1 months to 2 years) at onsets (Table 1) [4, 5, 7–12]. Although variable degrees of neurological deficits were left, none of them died or failed to receive neurosurgical



**Fig. 1** Plain and contrast-enhanced CT scans of the aneurysm in the present case. **A** A plain CT on admission in the present case. Arrow indicates the massive hemorrhage and the devoid of hemorrhagic signal (asterisk) in the right MCA region. Arrowheads indicate the prominent midline shift to the left hemisphere. **B** A plain CT on admission. The hemorrhagic lesion was extended to the surrounding parenchyma involving the caudate and lentiform nuclei (arrows). **C** A contrast CT shows the presence of an aneurysm located at the right MCA region (asterisk) and subarachnoid hemorrhage (arrowheads). **D** A stereographic reconstitution of the contrast head CT depicting the fusiform structure of MCA aneurysm (arrow:  $21 \times 13 \times 12$  mm in size)

**Table 1** Summary of patients with intracranial aneurysms less than 3 years of age (reports in 2021–2022)

No	Patient ID	Age at onset <sup>1</sup>	Location, morphology	Etiology	mASPECTS <sup>2</sup>	Outcome <sup>3</sup>	Year	Ref
1	Xu-1	1 m	L-cavernous, saccular	Unknown	–	mRS 0	2021	5
2	De Aguiar-1	1.5 m	R-MCA 10 mm, saccular	Idiopathic	–	–	2022	8
3	Clarke-7	2 m	R-MCA 11 mm, saccular	Idiopathic	L	DD, EP	2022	4
4	Clarke-3	3 m	R-MCA 9 mm, fusiform	Idiopathic	L	DD	2022	4
5	Clarke-6	3 m	L-PCA 16 mm, saccular	Idiopathic	–	DD	2022	4
6	Komuński-1	5 m	R-ICA, saccular	Idiopathic	M	–	2021	10
7	Clarke-5	6 m	R-MCA 2 mm, saccular	Idiopathic	–	Hemiparesis	2022	4
8	Clarke-9	6 m	L-MCA 14 mm, saccular	Idiopathic	–	Hemiparesis, VD	2022	4
9	Clarke-8	7 m	R-ICA 5 mm, saccular	Idiopathic	–	Hydrocephalus	2022	4
10	Sombo-1	8 m	Proximal basilar 8 mm, fusiform	Post-infectious	L	–	2021	12
11	Xu-2	9 m	L-MCA, pseudo	Unknown	–	mRS 2	2021	5
12	Barch-1	10 m	R-MCA, multiple, fusiform	Idiopathic	H	–	2021	7
13	Saraf-1	11 m	L-MCA, multi-lobular, dissecting	Post-traumatic	H	Hemiplegic gait	2021	11
14	Clarke-10	12 m	R-PCA 10 mm, saccular	Gaucher disease	–	Hemiparesis	2022	4
15	Xu-3	12 m	L-MCA	Unknown	M	mRS 1	2021	5
16	Clarke-1	1 y 2 m	L-MCA 4 mm, saccular	Idiopathic	–	Minor spasticity	2022	4
17	Clarke-4	1 y 5 m	R-MCA 18 mm, saccular	Idiopathic	H	Hemiparesis	2022	4
18	Xu-4	1 y 9 m	R-MCA, saccular	Unknown	M	mRS 1	2021	5
19	Xu-5	1 y 10 m	L-cavernous, giant	Unknown	–	mRS 0	2021	5
20	Clarke-2	1 y 10 m	R-ACA 3 mm	Post-traumatic	–	No deficit	2022	4
21	Demartini-1	2 y	R-ICA 5 mm, saccular	Post-traumatic	M	Asymptomatic	2021	9
22	Present case	2 y 8 m	R-MCA 21 mm	Idiopathic	L, 2	Died on day 15		

<sup>1</sup> Age represents years (y) and months (m)

<sup>2</sup> The mASPECTS scores were estimated and classified into the following three groups according to the presented images: L (low, 0–8), M (moderate, 9–16) and H (high, 17–24). –, no image available

<sup>3</sup> Comorbidities and neurological outcomes include epilepsy (EP) and measurements in modified Rankin scale (mRS)

–, No complication or normal development; DD, developmental delay; VD, visual defects; mASPECTS, modified Alberta Stroke Program Early CT Score; Ref, references

operations for their critical conditions. Thus, no clinical or neuro-imaging parameters were identified to predict the unfavorable outcome (death). Based on the neuroimaging data ( $n=10$ ), however, we estimated mASPECTS scores. We classified them into the three groups: L (low, mASPECTS 0–8), M (moderate, 9–16) and H (high, 17–24) (Table 1). Two (67%) of the three patients who belonged to the L group showed profound complications of developmental delay and/or epilepsy as neurological sequelae. On the other hand, two (29%) of seven patients with M and H scores showed hemiplegia. These data suggested that mASPECTS scores were useful for predicting postsurgical outcomes of ICA.

## Discussion

ICA in pediatric age accounts for 10–15% of the whole patient populations [13]. Patients under 3 years of age are extremely rare in prevalence [14, 15]. While it is difficult to perform angiography for infants and young children during the critical period, pediatric patients with successful outcomes have been increasingly reported in recent years [3–5, 8, 11, 12]. Nevertheless, data have been less

extensively analyzed for young children with unfavorable clinical courses. For this reason, the present case underscores the diagnostic value of neuroimaging findings for accurately detecting the ICA in early childhood.

In our previous study, lower scores (sGWR < 1.14 and mASPECTS < 20) were correlated with worse outcomes [6]. The present case showed low values of sGWR (1.13) and mASPECTS (2) on admission. Although further studies are required, these data may compensate insufficient prognostic values for survival and neurological outcomes of pediatric patients with intracranial hemorrhage.

Different patho-mechanisms have been considered to be involved in the development of ICAs in childhood and adults [1, 2, 4]. Childhood-onset ICAs are more frequently associated with trauma, infection, and particular genetic backgrounds than adult-onset ICAs [16]. In our patient, either the family information, past history, laboratory data or genetic analysis did not support evidence for common causes of ICAs. Thus, the patient was etiologically classified into the group of “idiopathic” ICA [1].

In conclusion, contrast-enhanced CT is a useful modality not only for detecting the source of hemorrhage, but

also for predicting survival and neurological outcomes of young children with massive ICA. Accumulating clinical and quantitative neuroimaging data will further dissect critical findings for both groups of children with successful and unfavorable outcomes.

#### Abbreviations

ICA: Intracranial aneurysm; CT: Computed tomography; mASPECTS: Modified Alberta Stroke Program Early CT Score; sGWR: Simplified gray matter attenuation-to-white matter attenuation ratio; MCA: Middle cerebral artery.

### Supplementary Information

The online version contains supplementary material available at <https://doi.org/10.1186/s12883-022-03022-4>.

#### Additional file 1.

#### Acknowledgements

We thank Kazusa DNA Research Institute (Kisarazu Chiba, 292-0818 Japan) for genetic analysis.

#### Authors' contributions

KT and NK managed the patient, conceptualized this report, and drafted the paper; KA performed surgical interventions; YS and SO organized the grand design of this report. All authors have read and approved the manuscript.

#### Funding

This study was supported in part by JSPS KAKENHI grant number JP20K10832 (N. Kaku). The funding body did not play any role in the design of the study and writing the text.

#### Availability of data and materials

The datasets supporting the conclusions of this article are all available in this manuscript.

#### Declarations

#### Ethics approval and consent to participate

Genetic analysis was performed in a compliance with the institutional guideline of Kyushu University Hospital. Written informed consent was obtained from the patients' parents.

#### Consent for publication

Written consent for publication was obtained from the patients' parents.

#### Competing interests

The authors have no conflicts of interest to declare.

#### Author details

<sup>1</sup>Department of Pediatrics, Graduate School of Medical Sciences, Kyushu University, 3-1-1, Maidashi, Higashi-ku, Fukuoka 812-8582, Japan. <sup>2</sup>Emergency and Critical Care Center, Kyushu University Hospital, 3-1-1, Maidashi, Higashi-ku, Fukuoka 812-8582, Japan. <sup>3</sup>Present address: Department of Critical Care Medicine, Fukuoka Children's Hospital, 5-1-1, Kashii-Teraha, Higashi-ku, Fukuoka 813-0017, Japan. <sup>4</sup>Department of Neurosurgery, Kyushu University, 3-1-1, Maidashi, Higashi-ku, Fukuoka 812-8582, Japan.

Received: 3 May 2022 Accepted: 10 December 2022

Published online: 19 December 2022

#### References

- Beez T, Steiger HJ, Hanggi D. Evolution of Management of Intracranial Aneurysms in children: a systematic review of the modern literature. *J Child Neurol*. 2016;31(6):773–83.
- Sorteberg A, Dahlberg D. Intracranial non-traumatic aneurysms in children and adolescents. *Curr Pediatr Rev*. 2013;9(4):343–52.
- Huang J, McGirt MJ, Gailloud P, Tamargo RJ. Intracranial aneurysms in the pediatric population: case series and literature review. *Surg Neurol*. 2005;63(5):424–32 discussion 432–423.
- Clarke JE, Luther E, Oppenhuizen B, Leuchter JD, Ragheb J, Niazi TN, et al. Intracranial aneurysms in the infant population: an institutional case series and individual participant data meta-analysis. *J Neurosurg Pediatr*. 2022;1:1–11.
- Xu R, Xie ME, Yang W, Gailloud P, Caplan JM, Jackson CM, et al. Epidemiology and outcomes of pediatric intracranial aneurysms: comparison with an adult population in a 30-year, prospective database. *J Neurosurg Pediatr*. 2021;28(6):685–94.
- Tetsuhara K, Kaku N, Watanabe Y, Kumamoto M, Ichimiya Y, Mizuguchi S, et al. Predictive values of early head computed tomography for survival outcome after cardiac arrest in childhood: a pilot study. *Sci Rep*. 2021;11(1):12090.
- Barchetti G, Di Clemente L, Mazzetto M, Zanusso M, Ferraresi P, Iannucci G. Republished: successful treatment of ruptured multiple fusiform middle cerebral artery aneurysms with silk vista baby flow diverter in a 10-months-old infant. *J Neurointerv Surg*. 2021;13(9):e17.
- de Aguiar GB, Ozanne A, Elawady A, Samoyeau T, Niknejad HR, Caroff J, et al. Intracranial aneurysm in the pediatric population: a single-center experience. *Pediatr Neurosurg*. 2022;57(4):9.
- Demartini Z Jr, Dos Santos de Alencar G, Cardoso-Demartini a, Sprengel SL, Zanine SC, Borba LAB: delayed diagnosis of intracranial aneurysm in pediatrics: the risk of misdiagnosis—a case report. *Childs Nerv Syst*. 2021;37(10):3245–9.
- Komunski P, Nowoslawska E, Zakrzewski K, Polis B, Swiatnicki W. Superior Hypophyseal artery ruptured aneurysm in a 5-month-old child presenting as an acute subdural hematoma: a case report. *Pediatr Neurosurg*. 2020;55(6):374–9.
- Saraf R, Garg T, Parvathi S. Endovascular therapy in Paediatric dissecting intracranial aneurysm: a case report. *Neurol India*. 2021;69(3):748–50.
- Somboonithiphol K, Chanthanaphak E, Singhara Na Ayudhaya SP, Khongkhatithum C, Sirlert B: successful endovascular treatment of pediatric basilar infectious (mycotic) aneurysm: a case report and review of the literature. *Childs Nerv Syst*. 2021;37(8):2687–93.
- Jordan LC, Johnston SC, Wu YW, Sidney S, Fullerton HJ. The importance of cerebral aneurysms in childhood hemorrhagic stroke: a population-based study. *Stroke*. 2009;40(2):400–5.
- Raisanen S, Frosen J, Kurki MI, Huttunen T, Huttunen J, Koivisto T, et al. von und Zu Fraunberg M, Jaaskelainen JE, Lindgren AE: impact of young age on the presentation of saccular intracranial aneurysms: population-based analysis of 4082 patients. *Neurosurgery*. 2018;82(6):815–23.
- van Lieshout JH, Fischer I, Kamp MA, Donders ART, Cornelius JF, Steiger HJ, et al. Subarachnoid hemorrhage in Germany between 2010 and 2013: estimated incidence rates based on a Nationwide Hospital discharge registry. *World Neurosurg*. 2017;104:516–21.
- Aeron G, Abruzzo TA, Jones BV. Clinical and imaging features of intracranial arterial aneurysms in the pediatric population. *Radiographics*. 2012;32(3):667–81.

#### Publisher's Note

Springer Nature remains neutral with regard to jurisdictional claims in published maps and institutional affiliations.