

PSYCHIATRIC PRESENTATION OF MEDICAL ILLNESS

Daniel W. Spaite, MD,* and Roger A. Smith, MD†

*Assistant Professor, Section of Emergency Medicine, Department of Surgery, University of Arizona, College of Medicine, Tucson; †University of Arizona College of Medicine, Tucson

Reprint address: Daniel W. Spaite, MD, Section of Emergency Medicine, University of Arizona Health Sciences Center, Tucson, AZ 85724

□ **Abstract**—A 37-year-old woman was seen in the emergency department for symptoms of depression. A careful mental status examination resulted in the discovery of an organic basis for the “psychiatric” presentation. As with any patient demonstrating behavioral abnormalities, this case illustrates the importance of an adequate history, physical, and mental status evaluation in ruling out organic etiology prior to labeling a patient’s complaints as functional. Medical illnesses that can present as apparent psychiatric disease and the clinical clues that lead to the diagnosis of such cases are discussed.

□ **Keywords**—organic brain syndrome; functional illness; disorientation; mental status exam; memory loss

Introduction

Frequently, the emergency physician encounters patients with behavioral abnormalities. Such patients may be confused, fearful, combative, psychotic, uncooperative, or manifest bizarre and inappropriate behavior. In this situation, it is incumbent upon the emergency physician to determine if the patient’s abnormal behavior is a manifestation of organic illness. This is important since many of the symptoms that lead to psychiatric referral may actually be manifestations of remedial organic pathology.

A large number of diseases may result in psychiatric symptoms and the incidence of medical illness in psychiatric patients is high.¹⁻⁶ Accurate identification of those patients with psychiatric complaints caused by organic illness requires careful attention to certain details of the history, physical, and mental status examinations. The following case illustrates such a patient.

Case Report

A 37-year-old woman arrived at the emergency department with a 1-week history of depression. Neighbors described the patient as having become very quiet over the past several days with noticeable social withdrawal. Some of her fellow workers became concerned when she failed to come to work for a week. They went to her home and found her to be alert but withdrawn, so they brought her to the emergency department. Upon questioning, the patient reported diminished appetite and some weight loss, but denied lethargy, early morning awakening, or other vegetative symptoms of depression. She had not contemplated suicide and had no prior psychiatric history. When asked about missing work, the patient stated that she thought someone else was work-

ing for her. During the previous week she had spent her time at home watching television and exercising. There was no history of headaches, visual changes, diplopia, hallucinations, nausea, vomiting, weakness, paraesthesias, or disturbances of gait or speech. Her medical history was unremarkable and she was currently taking no medications. Family history was significant for a younger brother with schizophrenia. She denied drug or excessive alcohol use and reported being gay. Recent stresses included a break up with her girlfriend, and an abortion one year previously. The patient had completed high school without difficulty, and her job entailed cleaning glassware in a biochemistry lab.

Physical examination revealed a cooperative, alert, well-appearing woman with good eye contact but a noticeably flat affect. Vital signs were: temperature, 98.6°F; pulse rate, 80 beats per minute; blood pressure, 106/74 mm Hg; respirations, 16/min. Head, eyes, ears, throat exams were within normal limits including round, equal, reactive pupils and a normal funduscopic examination. The neck was supple without thyromegaly, jugular venous distension, or carotid bruits. Auscultation of the chest revealed clear and equal breath sounds bilaterally. Examination of the heart revealed a normal S_1 and S_2 , with a regular rate and rhythm. There was a II/VI early to midsystolic murmur heard best at the left lower sternal border radiating to the apex. There were no gallops. The abdomen was soft and nontender with normal bowel sounds. No hepatosplenomegaly or palpable mass was present. There was no clubbing, cyanosis, or peripheral edema. Neurological examination revealed the patient to be alert and oriented to person, place, and time with good motor strength bilaterally and no sensory deficits. Reflexes were symmetrical bilaterally with cranial nerves II-XII intact. Her toes were down going bilaterally. Romberg test was negative, and cerebellar function was normal, as was her

gait. The patient exhibited poor recent memory and was only able to recall two of three objects immediately and one of three objects at five minutes. Although she was able to recall her birth date, there was a significant period of delay to "think about it." She was unable to interpret proverbs or do serial 7s or 3s. General knowledge was intact.

Initial laboratory values were: hemoglobin 13.7 g/dL; hematocrit 37.3%; WBC 7,500/ μ L with 74% polys, 1% bands, 19% lymphocytes, 5% monocytes, and 1% eosinophils. Serum electrolytes, BUN, and creatinine were normal. Additional laboratory tests revealed serum calcium, 9.6 mg/dL; magnesium, 2.1 mEq/L; phosphorus, 3.6 mg/dL; and blood glucose, 86 mg/dL. Although the patient's sensorium was intact, computed tomography (CT) scan of the head was obtained at this time because of the impairment of memory and cognitive function. This revealed a lucency in the region of the left caudate nucleus most consistent with infarction or neoplasm (Figure 1). A chest X-ray study was obtained and was normal. The neurology service was consulted and the patient was admitted for further evaluation. One day after admission the patient underwent a magnetic resonance imaging study that revealed lesions in the head of the left caudate, corona radiata, and globus pallidus, with minimal mass effect noted. It was felt that although ischemic injury could not be entirely ruled out, the findings were most consistent with that of neoplasm. Lumbar puncture was performed, revealing total serum protein, 32 g/dL; blood glucose 115 mg/dL; WBC 6/ μ L, with 98% monocytes and 2% polys. Gram's stain, culture and CSF cytology were negative. Thyroid-stimulating hormone, T_3 , T_4 , and T_4I were normal and Venereal Disease Research Laboratory test result was negative. An EEG was also performed and was normal. Neurosurgery was consulted and agreed that tumor was most likely but that cerebral infarction

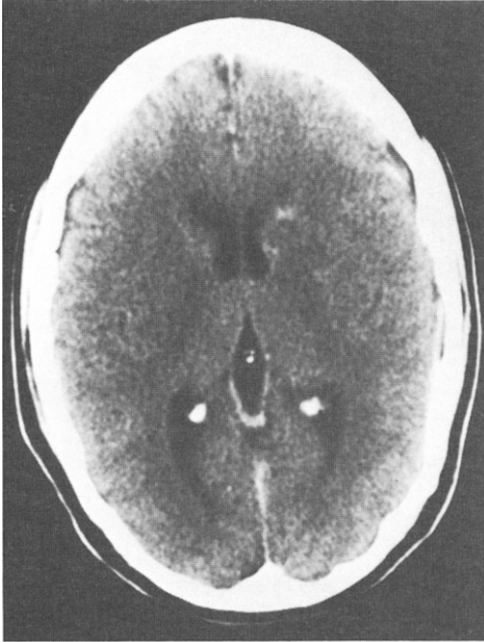


Figure 1. CT scan obtained at the time of the patient's initial presentation. Note contrast-enhanced lucency in the region of the left caudate nucleus with impingement into the left lateral ventricle.

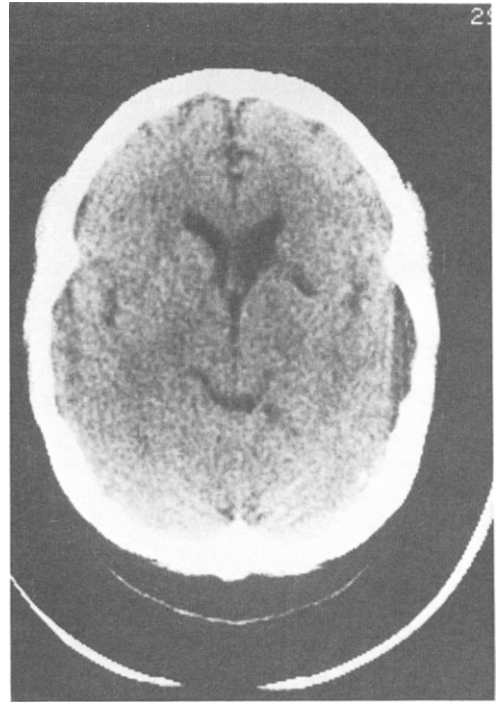


Figure 2. CT scan obtained 1 month after the initial scan. Evidence of an old infarction within the head of the left caudate nucleus is seen. Some increased prominence of the left lateral ventricle as well as a small area of encephalomalacia are also visualized.

was still a significant possibility. It was thus decided to follow the patient closely as an outpatient and repeat the CT scan 1 month later with a possible needle biopsy at that time. The patient remained stable with a slight improvement in memory and cognitive function during this 1-month interval. The CT was repeated as planned but this time was diagnostic of a segmental infarct (Figure 2). She was admitted for a workup to determine the cause. Cardiology consultation was obtained and an echocardiogram revealed mitral valve prolapse with significant degeneration of the valve leaflets. Although no clot was identified, it was felt that an embolus from the abnormal valve was the cause of the cerebral infarct and the patient was therefore started on anticoagulation therapy. Several months later, the patient remains on warfarin (Coumadin) and is doing well. Her deficits of memory and cognitive function have completely resolved.

Discussion

The emergency physician is frequently faced with the formidable task of determining whether a patient's abnormal behavior is caused by organic brain disease or is entirely functional in nature. Often the tendency is to make this determination early on in the evaluation and label the patient as "organic" or "psychiatric" with very little historical or clinical information.⁷⁻⁹ Unfortunately, the tendency to label patients with overtly psychiatric presentations as functional can often lead physicians to ignore important aspects of the history, physical, and mental status examinations. Thus, patients with important pathological processes may undergo significant deterioration before the underlying organic cause becomes obvious. In

some cases, even if this is a relatively brief delay, significant morbidity or even death may result.

Despite the common tendency to separate patients into either organic or psychiatric categories, it is clear that the two coincide in a large percentage of cases.^{2,3} As many as 42% of those who present as outpatients with psychiatric complaints have been found to have significant concomitant medical illness.^{2,4,10,11} In up to 20% of these patients a physical disorder was considered to be the primary cause of the "psychiatric" presentation. Patients who are hospitalized on psychiatric wards have an even higher incidence of medical illness with estimates ranging from 33% to 80%.^{3,12-14} One of the most striking findings found among these patients has been the high incidence of illness that was previously unknown to the patients or their physician.^{3,10}

Many potentially life-threatening illnesses may have a behavioral disturbance as their most obvious and striking symptoms. Table 1 is a summary of medical disorders that may present clinically as a primarily psychiatric problem.^{3-6,15-27}

The emergency physician must become adept at identifying those patients who, in fact, have an underlying medical illness. Although there is no perfect screening test, there are several fundamental pieces of information that can generally be obtained from the history, physical, and mental status examination that will aid in recognizing a large percentage of these patients (Table 2). Although all patients with behavioral disturbances will have "altered mental status" (depression, suicidal ideations, inappropriate behavior, hallucinations, etc), there are certain key aspects of the mental status examination that are the most sensitive indicators of organicity. Alteration or fluctuation of orientation should never be considered "functional" until a careful evaluation for organic causes has been undertaken. Memory, including immediate recall, must always be tested and any significant abnormalities

Table 1. Medical Diseases That Can Present With Primarily Psychiatric Complaints^{3-6,15-27}

Cardiovascular
Congestive heart failure
Arrhythmia
Hypertensive crisis
Metabolic/Endocrine
Hypoxia
Hypoglycemia
Hyperglycemia
Diabetic ketoacidosis
Hyponatremia
Hypercalcemia
Uremia
Hyperthyroidism
Hypothyroidism
Hypoparathyroidism
Hyperparathyroidism
Incipient delirium tremens
Addison's disease
Wilson's disease
Drug/Toxic
Ethanol
Digoxin
Propranolol
Methyldopa
Procainamide
Reserpine
Isoniazid
Sulfonamides
Diphenylhydantoin
Levodopa
Anticholinergics
Antihistamines
Lithium
Cimetidine
Amphetamines
Barbiturates
Benzodiazepines
Phenothiazines
Tricyclic antidepressants
Steroids
Aminophylline
Oral hypoglycemics
Insulin
Salicylates
Bromides
Carbon monoxide
Heavy metals (mercury, manganese, lead)
Infectious
Encephalitis
Tuberculosis
Brain abscess
Sepsis of many causes
Neurosyphilis
Meningitis
Collagen Vascular
Systemic lupus erythematosus
Rheumatoid arthritis
Neoplastic
Meningiomas (particularly frontal)
Brain metastases
Bronchogenic carcinoma

(continued)

Table 1. Continued

Hepatoma
Pancreatic carcinoma
Trauma
Postconcussive syndrome
Subdural hematoma
Pulmonary
Pulmonary embolus
Chronic obstructive pulmonary disease
Gastrointestinal
Hepatic encephalopathy
Pancreatitis
Ulcerative colitis
Neurological
Alzheimer's disease
Multi-infarct dementia
Huntington's disease
Seizures (especially temporal lobe)
Normal pressure hydrocephalus
Multiple sclerosis
Other
Anemia
Folic acid deficiency
Sarcoidosis
Scabies
Pinworm (in young children)
Dehydration

should lead to an intense search for an underlying medical illness. Cognitive function should be tested and any abnormalities evaluated with reference to the patient's educational and cultural background. Patients who exhibit slurred or slowed speech must be taken seriously, particularly if it is a new finding. The presence of visual, olfactory, or tactile hallucinations is also associated with an increased incidence of organic etiology. In a study by Hall and associates,² 20% of patients with behavioral manifestations of medical illness experienced visual hallucinations compared with only 0.5% of those psychiatric patients who had no underlying medical cause.

The case presented in this report shows the importance of a careful mental status examination in patients presenting with psychiatric complaints. The patient was alert and oriented to person, place, and time and her neurologic examination revealed no focal findings. However, the impairment of memory and cognitive function led the emergency physician to search for an organic basis for the patient's "psy-

chiatric" problem. A recent study by Zun and Gold²⁸ found that the mental status exam performed by emergency physicians is quite variable. In their series, only one-third routinely included testing of memory and immediate recall and even fewer tested cognitive function on a routine basis. In the case of this patient, had the finding of "oriented times three" been considered equivalent to "mental status: intact," the intracranial pathology might have been missed altogether. Clearly, the examination of mental status in the emergency department must go beyond simply testing orientation.

When clues in the history, physical, or mental status examinations point to the possibility of an organic cause, this should be pursued. Serum glucose, electrolytes, creatinine, CBC, and urinalysis may lead to a specific diagnosis. In certain circumstances, laboratory evaluations such as toxicologic screens, arterial blood gases, lumbar puncture, calcium, magnesium, serum ammonia, and other tests might be indicated. The use of the CT scan in the psychiatric population in general, as well as in patients presenting with psychiatric complaints to the emergency department, has received significant attention in the literature and remains controversial.^{5,22,29-33} Currently there is no universally accepted criteria for the use of the CT scan in this setting. However, as with other tests, it should be used when the possible benefits outweigh the cost and risks involved in the procedure. Obviously, each case must be evaluated individually, but if the clinical presentation points toward the possibility of the presence of a structural brain lesion, a scan should be obtained. Certainly patients with an altered level of consciousness or focal neurologic findings should be scanned emergently unless other historical or laboratory data argue convincingly against the presence of a brain lesion. Other relative indications include onset of major psychiatric illness after the age of 40, patients with a history of trauma, or new onset of

Table 2. Clinical Clues to the Presence of an Organic Cause of Psychiatric Presentation

History	
	Onset of major psychiatric illness after 40 years of age
	Significant medical illness (endocrine, cardiovascular, neurologic, etc)
	No previous psychiatric history
	History of drug or alcohol abuse
	Medications with potential for side effects resulting in behavioral disturbance
	History of poor response to "psychiatric" treatment
Physical Exam	
	Abnormal vital signs
	Depressed or fluctuating level of consciousness
	Cyanosis
	Evidence of trauma
	Incontinence (new onset)
	Focal neurologic signs
	Ataxia
	Tremor
	Dysarthria
Mental Status Exam	
	Fluctuating or altered orientation
	Impaired memory
	Impaired cognitive function
	Slowed speech or delayed verbal response
	Visual, olfactory, or tactile hallucinations

incontinence (Table 2). Patients with unexplained impairment of orientation, memory, or cognition, and in whom efforts to determine the underlying cause by laboratory examination have been unsuccessful, should receive a CT scan as these may be the earliest signs of a structural brain lesion (as in the case presented here).

Summary

The possibility of an organic disturbance must be included in the differential diag-

nosis of any patient with a behavioral disorder. Psychiatric symptoms are frequently the first manifestations of structural CNS pathology and other medical illnesses. Only after the high-risk signs and symptoms have been carefully pursued and the presence of an underlying medical condition ruled out, should the term "medically cleared for psychiatric evaluation" be used.

Acknowledgement—The authors wish to thank Glenda King for her assistance in the preparation of this manuscript.

REFERENCES

1. Saravay SM, Koran LM: Organic disease mistakenly diagnosed as psychiatric. *Psychosomatics* 1977; 18:6-11.
2. Hall RCW, Popkin MK, DeVaul RA, et al: Physical illness presenting as psychiatric disease. *Arch Gen Psychiatry* 1978; 35:1315-1320.
3. Hall RCW, Gardner ER, Stickney SK, et al: Physical illness manifesting as psychiatric disease. *Arch Gen Psychiatry* 1980; 37:989-995.
4. Hoffman RS, Koran LM: Detecting physical illness in patients with mental disorders. *Psychosomatics* 1984; 25:654-659.
5. Weinberger DR: Brain disease and psychiatric illness: When should a psychiatrist order a CAT scan? *Am J Psychiatry* 1984; 141:1521-1527.
6. Fauman MA, Fauman BJ: The differential diagnosis of organic psychiatric disturbance in the emergency department. *JACEP* 1977; 6:315-323.
7. Dubin WR, Weiss KJ, Zeccardi JA: Organic brain syndrome. *JAMA* 1983; 249:60-62.
8. Leeman CP: Diagnostic errors in emergency room medicine: Physical illness in patients labeled "psychiatric" and vice versa. *Int J Psychiatry Med* 1975; 6:533-540.
9. Weissberg MP: Emergency room medical clearance: An educational problem. *Am J Psychiatry* 1979; 136:787-790.
10. Koranyi EK: Morbidity and rate of undiagnosed physical illness in a psychiatric clinic population.

- Arch Gen Psychiatry* 1979; 36:414-419.
11. Davies WD: Physical illness in psychiatric outpatients. *Br J Psychiatry* 1965; 11:27-37.
 12. Maguire GP, Granville-Grossman KL: Physical illness in psychiatric patients. *Br J Psychiatry* 1968; 115:1365-1369.
 13. Herridge CF: Physical disorders in psychiatric illness. A study of 209 consecutive admissions. *Lancet* 1960; II:949-951.
 14. Hoffman RS: Diagnostic errors in the evaluation of behavioral disorders. *JAMA* 1982; 248:964-967.
 15. Surridge D: An investigation into some psychiatric aspects of multiple sclerosis. *Br J Psychiatry* 1969; 115:749-764.
 16. Whitlock FA, Siskind MM: Depression as a major symptom of multiple sclerosis. *J Neurol Neurosurg Psychiatry* 1980; 43:861-865.
 17. Himmelhoch J, Pincus J, Tucher G, et al: Subacute encephalitis: Behavioral and neurological aspects. *Br J Psychiatry* 1970; 116:531-538.
 18. Misra PC, Hay GG: Encephalitis presenting as acute schizophrenia. *Br Med J* 1971; 1:532-533.
 19. Wilson LG: Viral encephalopathy mimicking functional psychosis. *Am J Psychiatry* 1976; 133:165-170.
 20. Thompson GN: Cerebral lesions simulating schizophrenia: three case reports. *Biol Psychiatry* 1970; 2:59-64.
 21. Hunter R, Blackwood W, Bull J: Three cases of frontal meningiomas presenting psychiatrically. *Br Med J* 1968; 3:9-16.
 22. Owens DG, Johnston EC, Bydder GM, et al: Unsuspected organic disease in chronic schizophrenia demonstrated by computed tomography. *J Neurol Neurosurg Psychiatry* 1980; 43:1065-1069.
 23. Rosenblatt S, Faillace LA: The psychiatric manifestations of hyperparathyroidism. *Tex Med* 1977; 73:59-60.
 24. Perlas AP, Faillace LA: Psychiatric manifestations of carcinoma of the pancreas. *Am J Psychiatry* 1964; 121:182.
 25. Goldstein NP, Ewert JC, Randall RV, et al: Psychiatric aspects of Wilson's disease. *Am J Psychiatry* 1968; 124:1555-1561.
 26. Whybrow PC, Prange AJ, Threadway CR: Mental changes accompanying thyroid gland dysfunction. *Arch Gen Psychiatry* 1969; 20:48-63.
 27. Rice E, Gendelman S: Psychiatric aspects of normal pressure hydrocephalus. *JAMA* 1973; 223:409-412.
 28. Zun L, Gold I: A survey of the form of the mental status examination administered by emergency physicians. *Am Emerg Med* 1986; 15:916-922.
 29. Tsai L, Tsuang MT: Computerized tomography and skull x-rays: Relative efficacy in detecting intracranial disease. *Am J Psychiatry* 1978; 135:1556-1557.
 30. Jacoby RJ, Levy R: Computed tomography in the elderly. 3. Affective disorder. *Br J Psychiatry* 1980; 136:270-275.
 31. Tsai L, Tsuang MT: How can we avoid unnecessary CT scanning for psychiatric patients? *J Clin Psychiatry* 1981; 42:452-454.
 32. Holt RE, Rewat SR, Beresford TP, et al: Computed tomography of the brain and the psychiatric consultation. *Psychosomatics* 1982; 23:1007-1019.
 33. Evans NJR: Cranial computerized tomography in clinical psychiatry: 100 consecutive cases. *Compr Psychiatry* 1982; 23:445-450.