

Alexia with agraphia of kanji (Japanese morphograms)

MITSURU KAWAMURA,* KEIZO HIRAYAMA,* KEIKO HASEGAWA,†
NOBUYOSHI TAKAHASHI,* AKIRA YAMAURA‡

From the Departments of Neurology, Brain Research Institute, Rehabilitation,† and Neurosurgery,‡ School of Medicine, Chiba University, Chiba, Japan*

SUMMARY The case of the right-handed young Japanese woman with alexia with agraphia of kanji (the Japanese morphograms) due to a small circumscribed haematoma in the left posterior inferior temporal gyrus is described. Her chief complaint was the inability to read and write kanji. Detailed examination showed that her alexia with agraphia was much more predominant for kanji than kana (the Japanese syllabograms). These facts suggest that the processing of kanji and kana involves different intrahemispheric mechanisms.

Recent neuropsychological studies have revealed that the left cerebral hemisphere is responsible for the reading and writing of both kanji (which are the structurally complex morphograms in written Japanese with often several phonetic readings) and kana (which are the relatively simple syllabograms with unambiguous phonetic readings) (ref 1 and literature citations therein). Both kanji and kana are used in many sorts of printed matter, such as newspapers, magazines and books. In schooling, all kana (46 characters) and some graphically simple kanji are learned by the end of the first grade of elementary school. Standard use of kanji (approximately 1900 characters) prescribed by the Ministry of Education are to be learned by the end of 9th grade. All kanji can be represented in kana. For example, 風 wind (the first kanji character used in the sentence #4 of fig 1A) is also represented as かぜ /kaze/ in kana. In writing sentences, kanji (○) and kana (△) are combined together as shown in the example. 男の人が歩く . A man walks. (男: male 人: human 歩: walk の: grammatical formative which makes the preceding noun function as an adjective くの: conjugated part of a verb). Major lexical morphemes are usually written in kanji while conjugated endings of verbs, adjectives as

well as function words are always written in kana.

It has been suggested, however, that the processing of kanji and kana involves different intrahemispheric mechanisms, although very few clinical reports have directly addressed this question. In the present study, we describe a young Japanese woman who showed alexia with agraphia for kanji due to a small circumscribed haematoma in the left posterior inferior temporal gyrus. The location of the lesion has been identified by magnetic resonance imaging (MRI). Selective deficits in the reading and writing of kanji, as found in this case, are particularly important for understanding the possibly different mechanisms employed in the processing of kanji (morphograms) and kana (syllabograms).

Case report

A 32 year old right-handed woman, educated through high school, suddenly developed a headache on her left side on 4 October 1985. She became blind in the right half of her visual field for about an hour, at the same time. Thereafter, she found that she could not read the kanji in newspapers and could not write in her diary in kanji. She had no difficulty in the reading or writing of kana.

Neurological findings On admission (14 November 1985), she was fully conscious and oriented. Pursuit and saccadic ocular movements, optokinetic nystagmus and corrected visual acuity were normal. Goldmann perimetry confirmed full visual fields. There was no visual inattention to double simultaneous stimulation. Visually guided reaching with each upper extremity into each hemifield (visuo-motor coordination) was normal. Other cranial nerve functions, limb muscle power, coordination, muscle stretch reflexes, cutaneous sensations and gait were intact.

Address for reprint requests: Mitsuru Kawamura, MD, Department of Neurology, Brain Research Institute, School of Medicine, Chiba University, 1-8-1 Inohana, Chiba 280, Japan.

Received 12 September 1986 and in revised form 7 January 1987.
Accepted 19 January 1987

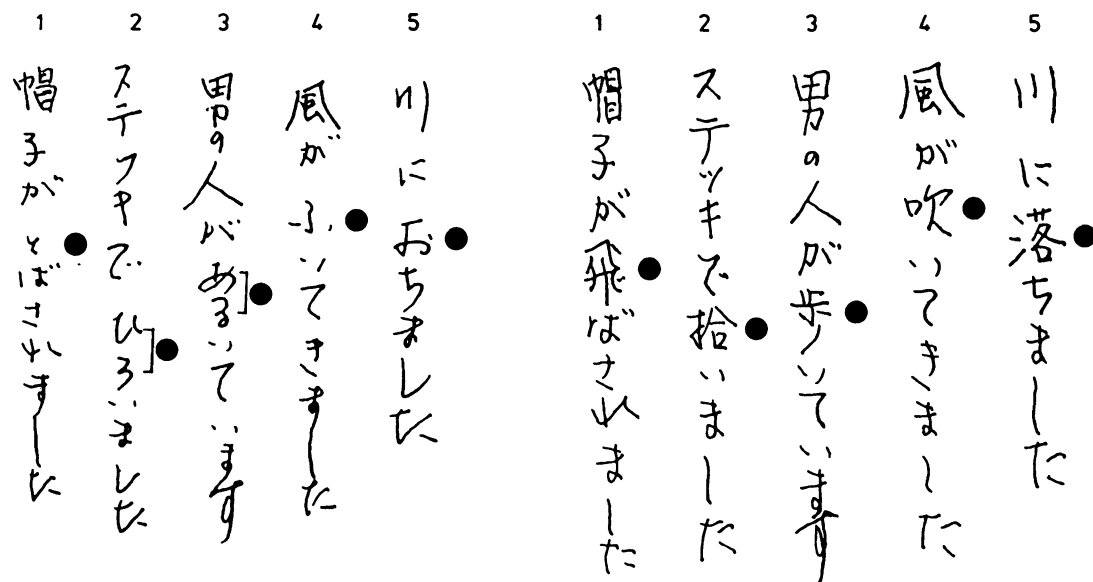


Fig 1 Handwriting samples from dictation. (A) Preoperatively, she wrote the corresponding kana (circles) instead of kanji. There were no paragraphic errors. (B) Postoperatively, she wrote kanji which she could not write preoperatively (circles). All of the kanji errors in the figure were of kanji used in verbs, whereas kanji nouns were written correctly. A significant trend of this kind, however, was not found. (1) He had his hat blown off. (2) He picked it up with a stick. (3) A man is walking. (4) The wind started to blow. (5) He fell into the river.

Neuropsychological findings Neither hemineglect (bisection of a line, copying the picture of a flower and Albert's line-crossing test), nor constructional apraxia (copying the figure of a diamond shape, a Greek cross and a cube) were found. Facial recognition, identification of overlapping figures (Poppelreuter), colour naming, limb and facial praxis to command, left-right discrimination, finger naming and simple verbal calculations were intact. Her Wechsler Adult Intelligence Scale was at an average level (Verbal IQ = 94, Performance IQ = 122, Full Scale IQ = 105).

Verbal language Spontaneous speech was well articulated and fluent without paraphasic errors. There were occasional word-finding pauses. The Western Aphasia Battery (WAB)² profile of speech characteristics was rated as normal, and there were no errors on the WAB tests of Spontaneous Speech, Auditory Comprehension, or Repetition. The score on the Token test was almost perfect (164/165).

Standardised naming tasks The scores of the WAB tests of Naming or Naming tests of 100 pictures³ were high (93% and 90%, respectively). In contrast to the prompt responses in Spontaneous Speech, Auditory Comprehension and Repetition, she was slow in performing these naming tests. Naming of certain pictures followed a latency of up to 10 seconds.

Standardised reading and writing tasks Her reading and writing scores on the WAB tests were at the high level (93%, 98.5%, respectively) of aphasic controls, but failed to reflect her specific difficulties in kanji. There were only a few errors in reading and writing kana words, but she was very slow in

reading and writing kanji on the WAB tests. Reading of some kanji followed a latency of up to 10 seconds and more often, she could not read them at all. Her explanation for her inability to read kanji was that she had forgotten the meaning and pronunciation of the kanji. When she wrote sentences which included both kanji and kana on dictation, she wrote the corresponding kana instead of kanji (fig 1, pre-operative). When she was asked to write the kanji which she had previously replaced with kana, she was unable to do so, but there were few paralexical or paragraphic errors. She could not obtain the correct answer even when the index finger was allowed to trace the shape of the kanji (kinesthetic facilitation). Copying of written sentences was intact.

Special tests for reading and writing to compare the disturbances of kanji with those of kana She was asked to read aloud and write in response to dictation 416 kanji and 104 kana letters, all of which she had learned in the first three years of primary school. In reading kanji, she made 14 mistakes out of 416 trials (3.4%); in writing kanji, she made 32 mistakes out of 416 (7.7%). No mistakes in reading or writing kana letters were made. In contrast to the prompt responses made in the kana tasks, her responses to the kanji tasks were often very slow, even when she eventually proved capable of reading and writing them. There were few paralexical and paragraphic errors. When she could not read or write a kanji she reported that she had forgotten the character.

Anatomical localisation Computed tomography (CT) scan

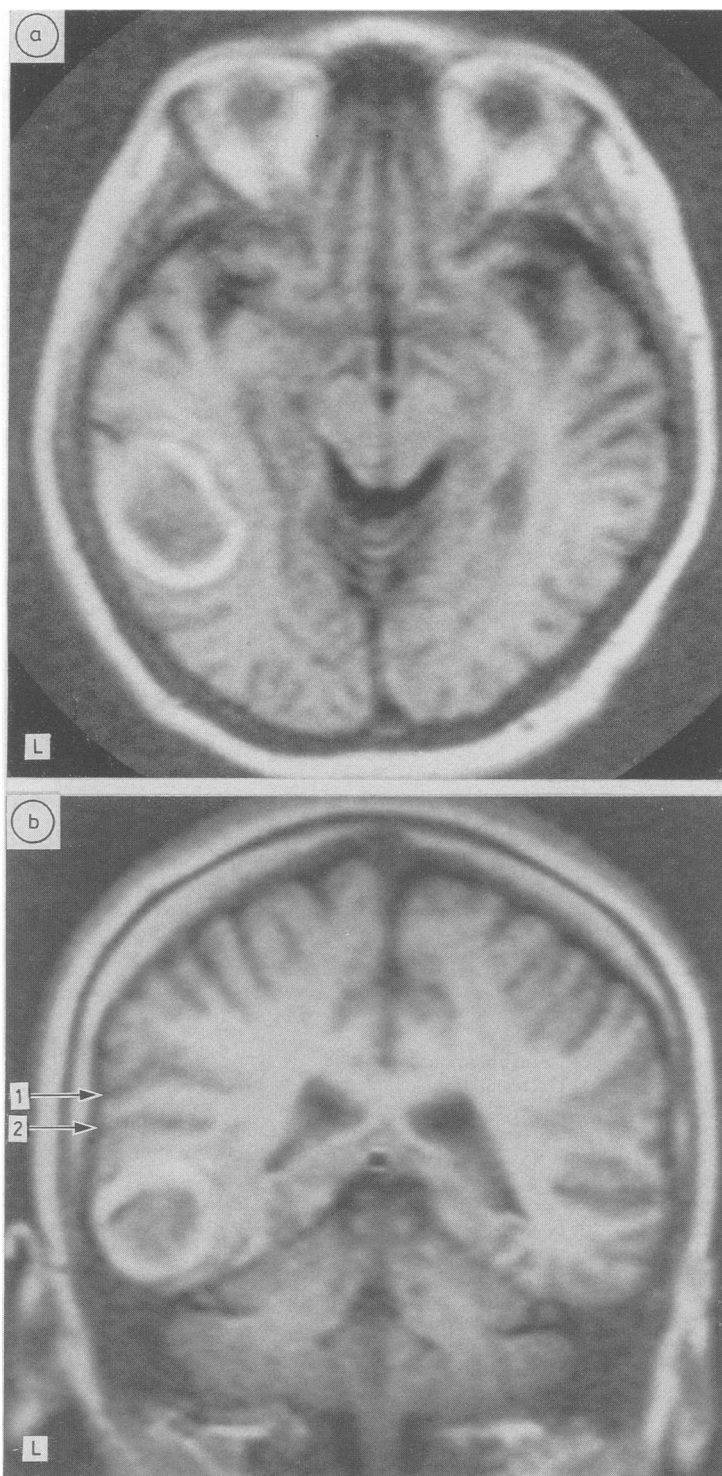


Fig 2 (*Legend on next page*).

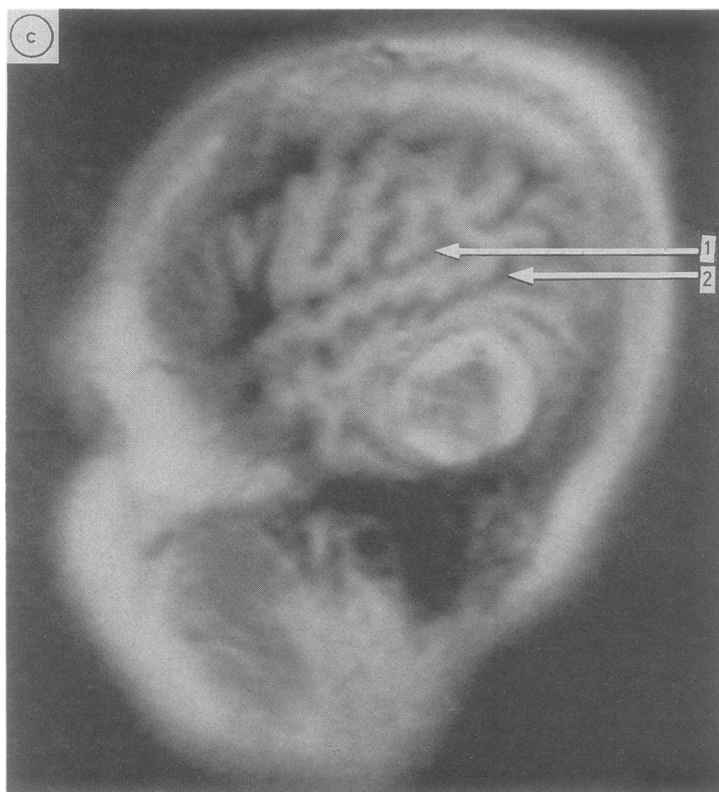


Fig 2 MRI (55 days after symptom onset) (inversion recovery technique). (a) Horizontal view [time of repetition (TR) 2080 ms, time of inversion (TI) 500 ms], (b) Coronal view (TR 1500 ms, TI 500 ms), (c) Left lateral sagittal view (60 mm from midline) TR 2080 ms, TI 500 ms). All MRI showed a ring-like high intensity area involving the cortex and the subcortical white matter of the posterior part in the left inferior temporal gyrus, (1) lateral cerebral fissure, (2) superior temporal sulcus.

(on 26 November 1985) showed a discrete, non-enhanced haematoma without significant mass effect. The haematoma involved the cortex and subcortical white matter of the left inferior temporal gyrus. The angular gyrus was spared. Magnetic resonance imaging (MRI) (Picker International Ltd, VISTR-MR 0.5T) was performed with a 0.26 Tesla superconducting magnet, using the inversion recovery technique (on 29 November 1985). The width of the slice was 10 mm and the patient's head was positioned supine. Horizontal (fig 2a), coronal (fig 2b) and left lateral sagittal images (fig 2c) showed a ring-like high intensity area involving the cortex and the subcortical white matter of the posterior part in the left inferior temporal gyrus. There were no abnormalities in the left angular gyrus. The right hemisphere was normal.

Surgical operation and follow-up On 5 December 1985, the subcortical haematoma was evacuated from the posterior inferior part of the left temporal lobe. The haematoma capsule was separated from the cerebral tissue and the haematoma

was removed in its entirety. Histologically, the capsule was a cavernous haemangioma.

Postoperatively, her ability to read and write considerably improved. Reading and writing scores on the WAB tests on 16 December 1985 were almost perfect. On the tests for writing sentences which included kanji and kana, she correctly wrote kanji on 17 December 1985 (fig 1 postoperative). The naming test of 100 pictures was also perfect with normal speed. Reading aloud and writing 416 kanji letters and 104 kana letters were rapidly completed without any error on 18 December 1985.

Discussion

Alexia with agraphia was first described by Dejerine⁴ in 1891 and has since been thought to occur with lesions of the left angular gyrus.^{5,6}

Our patient showed alexia with agraphia and slight anomia, and had no other neurological or neuropsychological manifestations. The location of the lesion in our patient was not in the left angular gyrus, but in a circumscribed region of the left posterior inferior temporal gyrus. By means of MRI, the lesion was clearly demonstrated. She recovered her ability to read and write completely following evacuation of the haematoma. The above findings show that alexia with agraphia can occur due to damage to the left posterior inferior temporal gyrus and surrounding areas in Japanese patients.

Recently several Japanese cases⁷⁻¹⁰ of alexia with agraphia due to lesions of the left posterior inferior temporal gyrus have been reported in Japan. Three of these cases,⁸⁻¹⁰ on which concrete data on the tasks were reported, showed difficulties predominantly in dealing with kanji. Iwata¹ concluded that Japanese patients with a lesion of the left posterior inferior temporal gyrus had disturbances of semantic processing of kanji-reading and -writing.

The chief complaint of our patient was her inability to read and write kanji. We demonstrated her difficulty by using the WAB tests and other special tests with more than 400 kanji and 104 kana letters for evaluation and her errors were found to be much more predominant in kanji than in kana. These facts show that at least some Japanese patients with lesions of the left posterior inferior temporal gyrus and surrounding areas have alexia with agraphia predominantly in kanji.

Other characteristics of our patient include the fact that there were few paralexia or paragraphic errors, which are often seen in alexia with agraphia due to left angular gyrus lesions,⁶ and that there was some difficulty of recall. Based on the above findings, we

conclude that the left posterior inferior temporal gyrus and surrounding areas have a function in visual word memory which is more specific for kanji (morphograms) than for kana (syllabograms), and that the processing of kanji and kana involves different intrahemispheric mechanisms.

References

- 1 Iwata M. Kanji versus kana: neuropsychological correlates of the Japanese writing system. *Trends Neurosci* 1984;7:290-3.
- 2 Kertesz A. *The Western Aphasia Battery*. New York: Grune & Stratton, 1982. (Translated into Japanese, Sugishita M *et al*, Tokyo: Igaku-Shoin, 1986).
- 3 Kamiyama G. *Manual of Aphasia Therapy*. Tokyo: Gendai-sha, 1971.
- 4 Dejerine J. Sur un cas de cécité verbale avec agraphié, suivi d'autopsie. *CR Soc Biol (Paris)* 1891;3:197-201.
- 5 Greenblatt SH. Localization of lesions in alexia. In: Kertesz A, ed. *Localization in Neuropsychology*, 1st ed. New York: Academic Press, 1983:323-56.
- 6 Kertesz A. Alexia. In: *Aphasia and Associated Disorders: Taxonomy, Localization and Recovery*, 1st ed. New York: Grune & Stratton, 1979:191-210.
- 7 Yamadori A. Alexia with agraphia and angular gyrus. *Higher Brain Function Research (Tokyo)* 1982;2:234-42.
- 8 Oka H, Asano T, Hattori S, Mochio S, Sugishita M. Pure alexia and alexia with agraphia caused by the left inferior temporal and fusiform gyri. *Neurol Med (Tokyo)* 1985;23:73-6.
- 9 Iwata M. Neural mechanisms of reading and writing in the Japanese language. *Funct Neurol (Roma)* 1986;1:43-52.
- 10 Shiota J, Kawamura M, Isono S, Hirayama K. Alexia with agraphia produced by a localized infarction of the inferior posterior temporal lobe. *Brain Nerve (Tokyo)* 1986;38:1051-5.