



The neuroimaging spectrum of SLC13A5 related developmental and epileptic encephalopathy

Robyn Whitney^{*}, Elaine Choi, Kevin C. Jones

Division of Neurology, Department of Paediatrics, McMaster University, 1200 Main Street West, Hamilton, ON, Canada

ARTICLE INFO

Keywords:

SLC13A5 gene
Neuroimaging
Developmental and epileptic encephalopathy
Punctate white matter lesions
Genetics

ABSTRACT

Background: SLC13A5 related developmental and epileptic encephalopathy (DEE) is an autosomal recessive condition characterized by neonatal seizures, fever sensitivity, status epilepticus, developmental delay and tooth anomalies. The neuroimaging spectrum of SLC13A5 related DEE is not fully known. We present a case of SLC13A5 related DEE with distinct neuroimaging findings and review the neuroimaging findings of all published cases of SLC13A5 related DEE.

Methods: A retrospective case review and focused review of the literature was completed.

Results: A 16-month-old male with a clinical phenotype consistent with SLC13A5 related DEE and a previously reported pathogenic variant in SLC13A5, c.655G>A, p.Gly219Arg and a novel likely pathogenic variant in SLC13A5, c.202C>T, p.Pro68Ser was identified. MRI at day 5 of life revealed wide spread punctate white matter lesions (PWMLs) affecting the subcortical white matter, periventricular white matter, splenium of the corpus callosum, posterior limb of the internal capsule, corticospinal tracts, midbrain, pons and medulla, mimicking a metabolic/infectious etiology. MRI at one month showed atrophy and evolution of white matter necrosis. One hundred and five cases of SLC13A5 related DEE were identified. Initial MRI was completed in 62 cases (59%). MRI was normal in 41 cases (66%) and abnormal in 21 (34%). White matter abnormalities were most common (n=15, 71%); PWMLs occurred in 8 cases (38%).

Conclusion: Neuroimaging abnormalities may exist in a third of SLC13A5 related DEE cases. White matter abnormalities such as PWMLs appear most common. It remains unknown why some are susceptible to these lesions and how they affect long-term neurodevelopmental outcomes in SLC13A5 related DEE.

1. Introduction

Monogenic etiologies of epilepsy, including developmental and epileptic encephalopathies (DEEs), have been increasingly recognized over the last decade and up to 50% of epilepsies may now have an identifiable genetic cause [1–3]. Mendelian inheritance constitutes approximately 1% of these cases [1–3]. A number of different disease mechanisms are implicated in genetic epilepsies [4]. Recently, dysfunction in solute carriers (SLCs), which are involved in the transport of solutes across the blood brain barrier, astrocytes, oligodendroglia cells and neurons have been implicated in neurological disorders including DEEs [5].

SLC13A5 encodes for the plasma membrane sodium coupled citrate transporter (SLC13A5) and is expressed in the brain, liver, tooth cells and testes. In the central nervous system, the SLC13A5 transporter is expressed mostly in neurons, and its role is to uptake both circulating

citrate and citrate released by astrocytes for metabolism [6–8]. The mechanism by which dysfunction of the SLC13A5 transporter results in neurological disease is unknown [7,9,10]. However, citrate is the main intermediate of the tricarboxylic acid (TCA) pathway and deficiency of citrate due to impaired transporter function could result in energy failure [9–11]. Citrate is also involved in the synthesis of gamma-aminobutyric acid (GABA) and glutamate, so transporter dysfunction could lead to an imbalance of neurotransmitters (i.e., excitatory versus inhibitory) [10,11]. Alterations in brain citrate metabolism may also lead to a propensity for seizures and cause neuronal network hyperexcitability, as shown in a recent mouse model [7].

In humans, autosomal recessive pathogenic variants in SLC13A5 cause a rare DEE with onset in the neonatal period [12–15]. SLC13A5 related DEE is characterized by seizures within the first week of life, fever sensitivity with recurrent status epilepticus (most commonly generalized tonic-clonic seizures (GTCs)), moderate to severe

^{*} Corresponding author.

E-mail address: whitner@mcmaster.ca (R. Whitney).

<https://doi.org/10.1016/j.seizure.2023.01.014>

Received 22 October 2022; Received in revised form 14 December 2022; Accepted 18 January 2023

Available online 23 January 2023

1059-1311/Crown Copyright © 2023 Published by Elsevier Ltd on behalf of British Epilepsy Association. This article is made available under the Elsevier license (<http://www.elsevier.com/open-access/userlicense/1.0/>).

intellectual disability, movement disorders, and other systemic features such as tooth abnormalities (i.e., hypodontia), growth attenuation and cardiorespiratory anomalies [10–15]. Presently there are no targeted therapies available for SLC13A5 related DEE [10]. The EEG findings in SLC13A5 related DEE have been previously summarized and range from normal recordings to background slowing and/or generalized and multifocal interictal epileptiform discharges (IEDs) [16]. The neuroimaging features have not been fully elucidated, but may be normal or as recently described may show a unique pattern of punctate white matter lesions (PWMLs) [10,11,13,15]. Herein, we report a previously unpublished compound heterozygote case of SLC13A5 related DEE with widely distributed white matter lesions, mimicking an underlying infectious/-metabolic etiology. We highlight the signature neuroimaging phenotype of SLC13A5 related DEE and summarize all previous published neuroimaging findings in SLC13A5 related DEE (Table 1).

2. Materials and methods

A retrospective chart review was completed after consent was obtained from the patient's caregivers as per the local research ethics guidelines. The American College of Medical Genetics (ACMG) criteria were used to classify the SLC13A5 variants [17]. We also conducted a focused comprehensive narrative literature review of previously reported SLC13A5 related DEE cases. PubMed, Web of Science, and Scopus were searched until October 11, 2022 using the following terms: SLC13A5, SLC13A5 seizures, SLC13A5 epilepsy and SLC13A5 DEE. Publication citations were screened to look for additional cases and duplicate cases. All cases of SLC13A5 related DEE were then collected and data regarding the neuroimaging findings were manually extracted and summarized (Table 1).

3. Results

3.1. Case description

A now-16-month-old male was born at 38 weeks *via* an uncomplicated vaginal delivery to a non-consanguineous couple. He presented with multifocal seizures on the first day of life. Seizures were initially characterized by gaze deviation, jitteriness, and stiffening movements. Family history was non-contributory. Video EEG (vEEG) showed multifocal electrographic seizures, discontinuity, and multifocal IEDs. A number of anti-seizure medications (ASMs) were tried including a midazolam infusion, phenytoin, lacosamide, folinic acid and pyridoxal-5-phosphate. MRI at day 5 of life showed multiple areas of restricted diffusion as well as T1 hyperintensity and T2 hypointensity (PWMLs) in the bilateral parasagittal, frontoparietal, temporal, occipital and periventricular white matter, as well as the splenium, posterior limb of internal capsule (PLIC), corticospinal tracts, tegmentum of the midbrain, anterior pons and medulla (Fig. 1). A diagnosis of an underlying metabolic, hypoxic ischemic or infectious etiology was suspected; however, extensive metabolic and infectious work up was negative, and birth history was not consistent with hypoxic-ischemic injury. Comprehensive epilepsy gene panel revealed a previously reported pathogenic variant in SLC13A5, NM_177550.4: c.655G>A, p.Gly219Arg and a novel variant of unknown significance in SLC13A5, NM_177550.4: c.202C>T, p.Pro68Ser, inherited each from one parent. Using the ACMG criteria, we reclassified the VUS as likely pathogenic [17] (Table 2).

Repeat MRI was completed at 1 month due to recurrent seizures. MRI showed parenchymal atrophy involving the bilateral frontoparietal and temporal lobes. The high T1 signal in the deep and subcortical white matter was still present, but less conspicuous. There was no restricted diffusion, and myelination was appropriate (Fig. 1). Overall, the MRI was felt to show evolution of white matter parenchymal necrosis. vEEG at 1 month of age showed a discontinuous background with multifocal IEDs and seizures with subtle clinical signs (i.e., eye opening, chewing) from the temporal head regions. Maintenance phenobarbital and

Table 1
Neuroimaging findings of previously reported cases of SLC13A5 DEE.

| Study Number | Number of Cases | MRI Onset:: | MRI Follow up: | Reference |
|--------------|---------------------------------------------------------------------------------------------------------------------------------------------------------------------------------------------------------------------------------|-----------------------------------------------------------------------------------------------------------------------------------------------------------------------------------------------------------------|-----------------------------------------------------------------------------------------------------------------------------------------------------------------------------------------------------------------------------------------------------------------------------------------------------------------------------------------------------------------------------------------------------------------------------------------------------------------------------------------------------------------------------------------------------------------|------------------------|
| 1 | 14 *3 cases in this study were reported by Hardies et al. [13] (Family B and D – initial MRI normal in all) *1 case in this study was reported by Weeke et al. [11] (Family 5 – initial MRI PWML, resolved on follow up). | Normal (n=13), abnormal (n=1) PWML (n=1) (resolved on follow up) | First epoch (0-3 years), repeat MRI (n=11) MRI normal (n=7), hyperintensity periventricular WM (3) and corpus callosum hypoplasia (n=1) Second epoch (>3-6 years), repeat MRI (n=4) Hyperintensity periventricular WM (n=1), mild corpus callosum hypoplasia (n=3) Third epoch (>6-12 years), repeat MRI (n=4) Hyperintensity periventricular WM (n=1), mild corpus callosum hypoplasia (n=3) Fourth epoch (>12-18 years), repeat MRI (n=2) Cortical atrophy (n=2) Fifth epoch (> 18 years), repeat MRI (n=2) Cortical atrophy (n=2) | Matricardi et al. [15] |
| 2 | 1 | Normal (n=1) | Not reported | Santalucia et al. [8] |
| 3 | 8 | Normal (n=0), abnormal (n=7) PWML (n=6) N=1 had high signal intensity in WM on T2 MRI, suspected PWML, small tentorial SDH, low NAA/Cho ratio and small lactate peak in WM. No follow up MRI as deceased. | Deceased (n=4) with no follow up, follow up MRI completed (n=4) Follow up MRI (n=4): MRI at 6 and 18 mths (n=2): Delayed myelination, gliosis, WM loss (previous PWML) MRI at 13 mths (n=1): Normal (previous PWML) One case no initial MRI, but MRI at 11, 16, 3 years and 6 years (n=1): Delayed myelination, gliosis, WM loss | Weeke et al. [11] |
| 4 | 15 | Not reported | Not reported | Brown et al. [18] |
| 5 | 1 | Hyperintensity left occipital cortex (n=1) | At 4mths: bilateral cortex hyperintensities, reduced myelination (n=1) At 6 mths: atrophy, corpus callosum thinning (n=1) | Pellegrino et al. [20] |
| 6 | 23 | Not reported | Not reported | |

(continued on next page)

Table 1 (continued)

| Study Number | Number of Cases | MRI Onset:: | MRI Follow up: | Reference |
|--------------|--------------------------------------------------------------------------------------------------------|----------------------------------------------------------------------------------------------------------------------------------------------|--------------------------------------------------------------------------------------------------------------------------------------------------------------|-------------------------------------------|
| 7 | 5 *2 cases in this study were described by Klotz et al. [14] (Family A, both (n=2) with normal MRI) | Normal (n=3), abnormal (n=2) PVL (n=1) Chiari 1 malformation (n=1) | Not reported | Yang et al. [16] Bainbridge et al. [9] |
| 8 | 9 | MRI normal (n=6), abnormal (n=3) Frontal lobe thickening (n=1) Hyperintense WM lesion in parietal lobe (n=1) Focal loss of GM (n=1) | Not reported | Klotz et al. [14] |
| 9 | 8 | MRI normal (n=6), abnormal (n=2) PVL like (n=1) Multiple PWML and elevated lactate (n=1), follow up at 6 mths and 14 mths. | MRI at 6 mths (n=1), brain atrophy, loss of WM at 14 mths no progression (initial MRI had shown PWML) | Hardies et al. [13] |
| 10 | 7 | MRI non conclusive/normal for all subjects (n=7) | Not reported | Thevenon et al. [12] |
| 11 | 10 *3 cases in this study were described by Hardies et al. [13] (Family C, all with normal MRI) | MRI normal (n=9), abnormal (n=1) Mild atrophy left hemisphere (n=1) | Not reported | Schossig et al. [21] |
| 12 | 3 | MRI normal (n=2), abnormal (n=1) Posterior periventricular hyperintensity with reduction of volume of WM (n=1) | Not reported | Alhakeem et al. [19] |
| 13 | 2 | Normal (n=0), abnormal (n=2) Delayed myelination (n=1) FCD (n=1) | Delayed myelination resolved (n=1) FCD persisted with residual abnormality in the right frontal parietal region extending to the periventricular WM (n=1) | Anselm et al. [22] |
| 14 | 3 | MRI abnormal (n=1), | Not reported | Duan et al. [23] |

Table 1 (continued)

| Study Number | Number of Cases | MRI Onset:: | MRI Follow up: | Reference |
|--------------|-----------------|----------------------------------------------------------------------|----------------|-------------------------------------|
| | | unavailable (n=2) Non-specific enlargement of subarachnoid spaces | | |
| 15 | 2 | Not reported | Not reported | Arvio et al. [24] |
| 16 | 1 | Normal (n=1) | Not reported | Pantoja Leao et al. [25] |
| 17 | 1 | PVL (n=1) | Not reported | Mir et al. [5] |
| 18 | 1 | Normal (n=1) | Not reported | Snoeijs-Schouwenaars FM et al. [26] |

Legend: FCD: Focal cortical dysplasia, GM: grey matter, MRI: magnetic resonance imaging, Mths: months, N: number, PVL: periventricular leukomalacia, PWML: punctate white matter lesions, Sz: Seizure, SDH: subdural hematoma, WM: white matter

levetiracetam were added to lacosamide. EEG at 6 months showed a normal background and was mildly abnormal due to runs of diffuse polymorphic delta activity.

At follow up at 16 months of age, the child was having weekly seizures (i.e., generalized tonic, generalized tonic-clonic and focal motor onset with impaired awareness seizures) of variable duration, <1 min to 9 min. He also had tonic-clonic convulsive status epilepticus triggered by febrile illness/immunization. Maintenance ASMs included clobazam, topiramate, levetiracetam, phenobarbital, and lacosamide. Developmentally, he had head control and was working on rolling and sitting. He could grab objects, vocalize, understand his name, and visually track parents. Medical history was complicated by hypotonia, decreased enamel, gastrointestinal reflux, G-tube feeding, obstructive sleep apnea (OSA) and movement disorder (i.e., tongue twitching/thrusting and excessive movements of extremities). On neurological exam there was mild axial hypotonia with no focal findings.

3.2. Literature review

A total of 105 cases with SLC13A5 related DEE from 18 articles were included (Table 1) [5,8,9,11–16,18–26]. Duplicate cases were identified in study 1, 7 and 11 (Table 1) [9,15,21]. An initial MRI around the time of presentation was available in 62 cases (59%). Initial MRI was normal in 41 cases (66%) and abnormal in 21 cases (34%). Of the cases with abnormalities (n=21), the findings included: PWMLs or suspected PWMLs (n=8, 38%), hyperintense lesion within the white matter (i.e., parietal lobe, occipital lobe, or periventricular area) (n=3, 14%), periventricular leukomalacia (PVL) (n=3, 14%), delayed myelination (n=1, 5%), and other findings (n=6, 29%) such as frontal lobe thickening (n=1, 5%), focal loss of grey matter (n=1, 5%), mild atrophy of the left hemisphere (n=1, 5%), focal cortical dysplasia (FCD) (n=1, 5%), enlargement of the subarachnoid spaces (n=1, 5%), and Chiari 1 malformation (n=1, 5%) [5,9,11,13–15,19–23]. Repeat brain MRI was seldom completed and findings on follow up are summarized in Table 1 [11,13,15,20,22]. There were 4 cases with PWMLs who had follow up imaging, and in 3 cases imaging subsequently showed white matter loss, gliosis, and delayed myelination, while in 1 case the findings had resolved [11,13]. Other findings seen on follow up MRI were corpus callosum hypoplasia/thinning, hyperintensity within the periventricular white matter, brain atrophy, persistent FCD, and bilateral hyperintensities within the cortex with reduced myelination [11,15, 20,22].

4. Discussion

In summary, we report a new case of SLC13A5 related DEE and

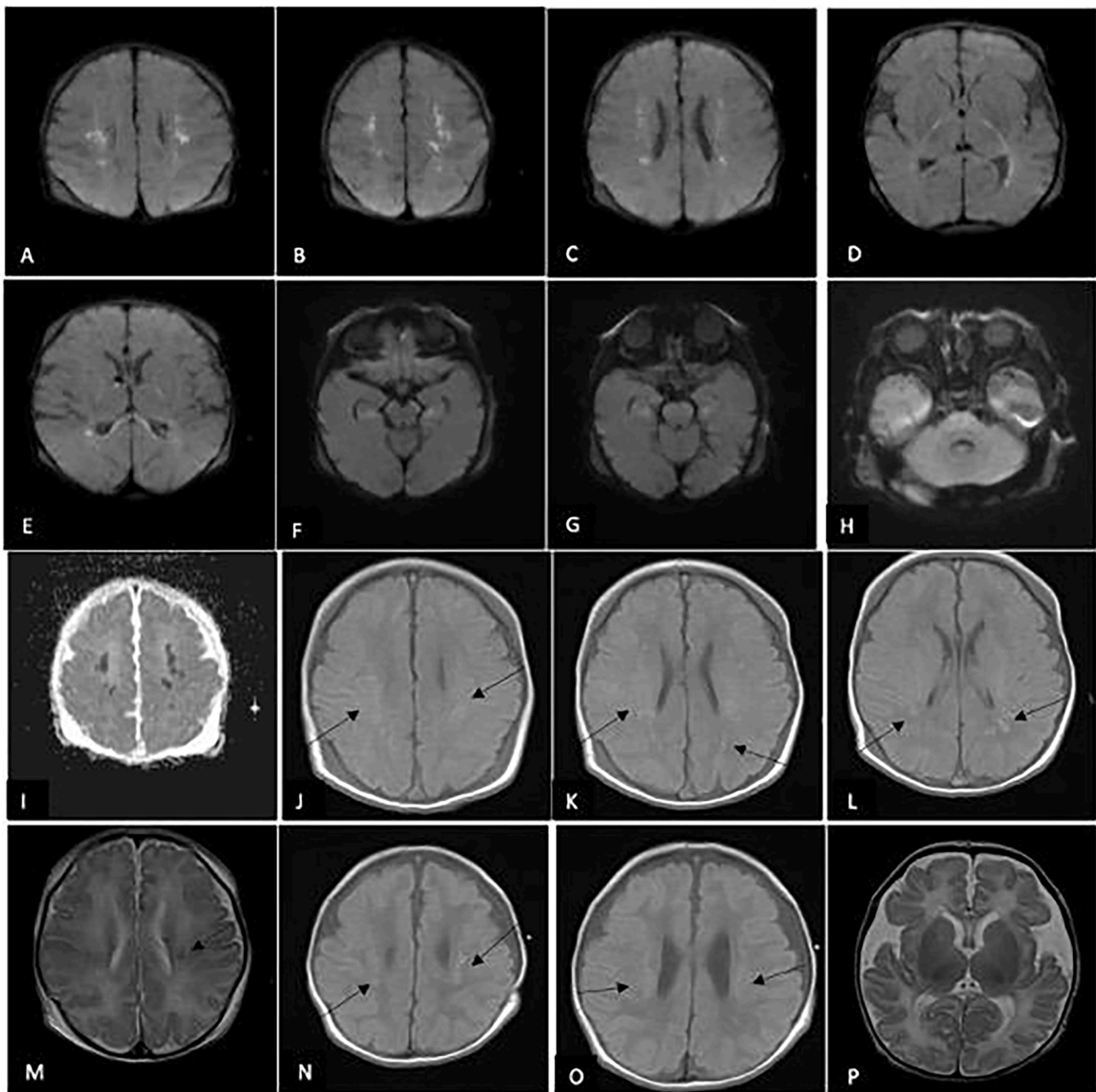


Fig. 1. Representative neuroimaging findings of our case: MRI images A-H at day 5 of life show PWMLs with restricted diffusion on DWI sequence throughout the cortical and subcortical white matter, optic radiations, posterior limb of internal capsule, splenium, corticospinal tract, midbrain, pons, temporal lobes and medulla. Image I shows that there is corresponding dark signal on ADC map. Images J to L show subtle increased T1 signal throughout the subcortical white matter (see arrows). Image M shows T2 MRI with subtle decreased T2 signal (see arrow). MRI images N-P at 27 days of life show subtle increased T1 signal is seen in the white matter (Images N-O, arrow), ventricular enlargement and non-specific T2 patchy signal in the white matter as well as diffuse parenchymal atrophy (Image P).

highlight the neuroimaging phenotype of this condition via illustration of an additional case and literature review. Our case presented with a similar clinical phenotype as described in the literature with neonatal onset seizures, subsequent fever sensitivity with status epilepticus, developmental delay, hypotonia, movement disorder, and decreased enamel. EEG initially showed multiple electrographic seizures, discontinuous background and multifocal IEDs, but by six months had nearly normalized [5,8,9,11–16,18–26]. Normalization of the EEG background and interictal pattern has been described previously with SLC13A5-related DEE [16]. Initial MRI showed wide spread PWMLs scattered throughout the subcortical white matter and periventricular area, but also extending to the corpus callosum, corticospinal tracts, midbrain, pons and medulla. Follow up MRI at one month showed

atrophy and evolution to white matter necrosis. Although PWMLs have been described before with SLC13A5-related DEE predominantly in the subcortical white matter and periventricular regions, we are unaware of previous cases showing such an extensive topographic distribution of PWMLs. In our case, PWMLs were widespread affecting the subcortical and periventricular white matter regions, but also extending to multiple regions in the brainstem, prompting consideration of a possible metabolic and/or infectious etiology [11,13]. We also provide insight into the other neuroimaging findings observed in SLC13A5 related DEE.

The MRI findings of SLC13A5 related DEE reported in the literature are variable [5,9,11,13–15,19–23]. Initial MRI is normal in two thirds of cases, while abnormalities exist in a third. When grouped together, white matter abnormalities are most commonly observed (n=15, 71%)

Table 2

Variants in the SLC13A5 gene in our reported case.

| Variant: | ACMG Criteria [17] | Inheritance/ Novel or Previously Reported | Classification |
|-------------------------------------------------------|-------------------------------------------------------------------------------------------------------------------------------------------------------------------------------------------------------------------------------------------------------------------------------------------------------------------------------------------------------------------------------------------------------------------------------------------------------------------------------------------------------------------------------------------------------------------------------------------------------------------------------------------------------------|----------------------------------------------------|----------------------|
| SLC13A5, NM_177550.4: c.655G>A, p. Gly219Arg | 2 strong: P3 + PS4 PS3 – well-established <i>in vitro</i> or <i>in vivo</i> functional studies supportive of a damaging effect on the gene or gene product (Hardies et al., 2015) PS4 –The presence of the variant in affected individuals is significant increased compared with prevalence in controls (i. e., multiple studies show multiple unrelated individuals with same variant [12–14,22]) | Inherited (Maternal) Previously reported | Pathogenic |
| SLC13A5, NM_177550.4: c.202C>T, p. Pro68Ser | 3 moderate PM2, PM3, PM5 PM2 – absent from controls or at extremely low frequency if recessive (allele frequent gnomAD 0.00007959) PM3 – for recessive disorders, detected in trans with a pathogenic variant (as above) PM5 – Novel missense change at amino acid residue where a different missense change determined to be pathogenic has been seen before (i.e., p.Pro68Gln – [21]) Additional: PP3 – multiple lines of evidence suggest deleterious effect: Mutation taster, SIFT, polyphen-2 all damaging/deleterious Proline is highly conserved and moderate physiochemical difference with serine | Inherited (Paternal) Novel | Likely pathogenic |

and include non-specific hyperintensities, PWMLs, delayed myelination, and PVL. PWMLs are the most common white matter abnormality observed in patients with SLC13A5 related DEE to date. PWMLs are small patches of increased signal intensity on T1 imaging, and decreased intensity on T2 imaging [11,27]. Moreover, they show diffusion restriction with increased signal on diffusion weighted imaging (DWI) and corresponding dark signal on apparent diffusion coefficient (ADC) map [11,27]. PWMLs are thought to be ischemic in origin and relate to injury of the oligodendrocyte progenitor cells and subplate neurons [11,27]. Typically, PWMLs may be observed in very preterm infants (20–50%), but they may also be observed in term infants, for example in the setting of hypoxic ischemic encephalopathy, infection (i.e., parechovirus, cytomegalovirus), congenital heart disease, genetic or metabolic disorders (i.e., hypoglycemia, mitochondrial disorders, methylmalonic acidemia and other inborn errors of metabolism) [11,27]. Therefore, it is important that a broad differential for PWMLs is considered when approaching a child with new onset seizures and/or other neurological findings.

The etiology of PWMLs is important, and genetic causes may be associated with poorer prognosis or higher lesion number [11]. Location

may also be important, for instance PWMLs within the PLIC or corticospinal tract may predict risk of motor impairment [11,27–28]. The first association between SLC13A5 related DEE and PWMLs was described by Weeke et al. [11], although few other cases have been reported [13]. In the limited existing cases with follow up imaging (i.e., at 6 to 18 months), successive MRI of patients with PWMLs has shown permanent injury with white matter loss, gliosis and delayed myelination [13]. Likewise, our case had repeat MRI at one month of age which also showed atrophy and white matter injury, however further follow up neuroimaging studies have not been completed. Currently it is unknown whether patients with PWMLs with SLC13A5 related DEE have different neurodevelopmental outcomes than patients without white matter injury, which may be an area of future study.

It is unknown why some patients with SLC13A5 related DEE are susceptible to PWMLs and other forms of white matter injury while others are not. As previously discussed, citrate is the main intermediate of the TCA cycle, and deficiency of citrate in SLC13A5 related DEE may lead to energy failure within the central nervous system [9–11]. Interestingly, the ketogenic diet has been proposed as a treatment option to bypass this deficiency, although has had mixed results in SLC13A5 related DEE to date [10,13]. Larger studies are needed to determine the effectiveness of the ketogenic diet in this condition. It is possible that frequent prolonged seizures, coupled with low citrate, could predispose to injury (i.e., due to excess metabolic stress) and PWMLs in some patients [11]. However, seizure burden is generally higher in the neonatal period for most cases of SLC13A5 related DEE, yet many still have normal neuroimaging [9,12,14,15,19,21,25,26]. Whether some genotypes are more at risk for white matter injury is also unclear at this time, given the small number of cases of SLC13A5 related DEE reported. It has also been suggested that patients with SLC13A5 related DEE may be more susceptible to ischemic injury and thus predispose them to developing PWMLs [11,13]. Further, it is also possible that cardiac anomalies in some patients with SLC13A5 related DEE could contribute to ischemic injury [10].

In addition to PWMLs, other white matter abnormalities were also observed in the literature such as delayed myelination [22]. Citrate plays an important role in fatty acid synthesis, so its deficiency could impair myelination in patients with SLC13A5 related DEE [10,11]. Delayed myelination in previously reported cases either occurred alone, or following the appearance of PWMLs [11,22]. A number of other non-specific abnormalities were observed in the literature, as shown in Table 1. Of importance, frontal lobe thickening and a FCD were observed in two cases, which may have important treatment implications (i.e., possible resection) if these areas are responsible for refractory seizures [14,22]. The link between SLC13A5 related DEE and focal cortical malformations, however, has not been well described before.

Limitations to our study include that not all cases with SLC13A5 related DEE had neuroimaging data available (i.e., 40% were missing). It is therefore possible that other types of brain imaging abnormalities could be missed or under called as a result. Further, although initial MRI was often done, follow up MRI was seldom completed. Thus, the longitudinal spectrum of neuroimaging findings in SLC13A5 related DEE is not fully known. Future studies are therefore needed to better understand the extent and progression of neuroimaging features in SLC13A5 related DEE and their impact on neurodevelopmental outcomes (if any). Additional studies are also needed to better explore the potential association between PWMLs and SLC13A5 related DEE, given that these lesions may be caused by a wide number of aetiologies. In addition, future research is needed to determine why certain patients with SLC13A5 related DEE are particularly susceptible with white matter lesions such as PWMLs. It will also be of interest to determine whether the genotype and phenotype differs between those that have PWMLs and those that do not in larger cohorts of SLC13A5 related DEE.

5. Conclusion

In conclusion, we present an additional case of SLC13A5 related DEE and provide insight into the neuroimaging phenotype of this condition. While two thirds of MRIs are normal in this condition, up to one third can have abnormalities, predominantly in the white matter [5,9,11,13–15,19–23]. PWMLs appear to be the most common white matter abnormality observed and are typically seen at presentation in infancy and may have an extensive topographic distribution [11,13]. The etiology of PWMLs remains unknown but may be related to central nervous system energy failure, predisposition to ischemia, or other unknown factors [9–11]. Presently, it remains unknown why some patients with SLC13A5 related DEE are susceptible to such lesions and how these lesions impact neurodevelopmental outcomes. Overall, further research is needed to better understand the potential association between PWMLs and SLC13A5 related DEE.

Declaration of Competing Interest

None.

Acknowledgments

We thank the patient and their caregivers for participating in this study.

Funding

None.

References

- [1] Guerrini R, Balestrini S, Wirrell EC, et al. Monogenic epilepsies: disease mechanisms, clinical phenotypes, and targeted therapies. *Neurology* 2021;97(17):817–31.
- [2] Morrison-Levy N, Borlot F, Jain P, et al. Early-onset developmental and epileptic encephalopathies of infancy: an overview of the genetic basis and clinical features. *Pediatr Neurol* 2021;116:85–94.
- [3] Helbig I, Tayoun AAN. Understanding genotypes and phenotypes in epileptic encephalopathies. *Mol Syndromol* 2016;7(4):172–81.
- [4] McTague A, Howell KB, Cross JH, et al. The genetic landscape of the epileptic encephalopathies of infancy and childhood. *Lancet Neurol* 2016;15(3):304–16.
- [5] Mir A, Almudhry M, Alghamdi F, et al. SLC gene mutations and pediatric neurological disorders: diverse clinical phenotypes in Saudi Arabian population. *Hum Genet* 2022;141:81–99.
- [6] Bhutia YD, Kopel JJ, Lawrence JJ, et al. Plasma membrane Na coupled citrate transporter (SLC13A5) and neonatal epileptic encephalopathy. *Molecules* 2017;22:378.
- [7] Henke C, Tollner K, van Dijk RM, et al. Disruption of the sodium-dependent citrate transporter SLC13A5 in mice causes alterations in brain citrate levels and neuron network excitability in the hippocampus. *Neurobiol Dis* 2020;143:105018.
- [8] Santalucia R, Vilain C, Soblet J, et al. Carbamazepine efficacy in a severe electro-clinical presentation of SLC13A5-epilepsy. *Ann Clin Trans Neurol* 2022;9(7):1095–9.
- [9] Bainbridge MN, Cooney E, Miller M, et al. Analyses of SLC13A5-epilepsy patients reveal perturbations of TCA cycle. *Mol Genet Metab* 2017;121(4):314–9.
- [10] Goodspeed K, Liu JS, Nye KL, et al. SLC13A5 deficiency disorder: from genetics to gene therapy. *Genes* 2022;13(9):165.
- [11] Weeke LC, Brilstra E, Braun KP, et al. Punctate white matter lesions in full-term infants with neonatal seizures associated with SLC13A5 mutations. *Eur J Paediatr Neurol* 2017;21(2):396–403.
- [12] Thevenon J, Milh M, Feillet F, et al. Mutations in SLC13A5 cause autosomal-recessive epileptic encephalopathy with seizure onset in the first days of life. *Am J Hum Genet* 2014;95(1):113–20.
- [13] Hardies K, de Kovel CGF, Weckhuysen S, et al. Recessive mutations in SLC13A5 result in a loss of citrate transport and cause neonatal developmental delay and teeth hypoplasia. *Brain* 2015;138(Pt 11):3238–50.
- [14] Klotz K, Porter BE, Colas C, et al. Mutations in the Na/citrate cotransporter NaCT (SLC13A5) in pediatric patients with epilepsy and developmental delay. *Mol Med* 2016;22(2):310–21.
- [15] Matricardi S, De Liso P, Freri E, et al. Neonatal developmental and epileptic encephalopathy due to autosomal recessive variants in the SLC13A5 gene. *Epilepsia* 2020;61:2474–85.
- [16] Yang QZ, Spelbrink EM, Nye KL, et al. Epilepsy and EEG phenotype of SLC13A5 citrate transporter disorder. *Child Neurol Open* 2020;7:1–7.
- [17] Richards S, Aziz N, Bale S, et al. Standards and guidelines for the interpretation of sequence variants: a joint consensus recommendation of the American college of medical genetics and genomics and the association of molecular pathology. *Genet Med* 2015;17(5):405–24.
- [18] Brown TL, Nye K, Porter BE, et al. Growth and overall health of patients with SLC13A5 citrate transporter disorder. *Metabolites* 2021;11(11):746.
- [19] Alhakeem A, Alshibani F, Tabarki B. Extending the use of stiripentol to SLC13A5-related epileptic encephalopathy. *Brain Dev* 2018;40(9):827–9.
- [20] Pellegrino F, Tardivo I. SLC13A5-related epileptic encephalopathy successfully treated with valproate and acetazolamide. *Seizure* 2021;91:244–5.
- [21] Schossig A, Bloch-Zupan A, Lussi A, et al. SLC13A5 is the second gene associated with Kohlschütter–Tonz syndrome. *J Med Genet* 2017;54:54–62.
- [22] Anselm I, MacCuaig M, Prabhu S, et al. Disease heterogeneity in Na/citrate cotransporter deficiency. *JIMD Rep* 2017;31:107–11.
- [23] Duan R, Saadi NW, Grochowski CM, et al. A novel homozygous whole-gene deletion of SLC13A5 mediated by Alu-Alu mediated rearrangement in an Iraqi family with epileptic encephalopathy. *Am J Med Genet A* 2021;185(7):1972–80.
- [24] Arvio M, Lahdetie J. Adult phenotype of the homoygous missense mutation c.655G>A, p.Gly219Arg in SLC13A5: a case report. *Am J Med Genet A* 2020;182a:2671–4.
- [25] Pantoja Leao VH, de Melo Aragao M, Pinho RS, et al. Teaching neuroimages: when the teeth are the clue to the etiology of an epileptic encephalopathy. *Neurology* 2021;96:e157–8.
- [26] Snoeijs-Schouwenaars FM, van Ool JS, Verhoeven JS, et al. Diagnostic exome sequencing in 100 consecutive patients with both epilepsy and intellectual disability. *Epilepsia* 2019;60:155–64.
- [27] Hayman M, van Wezel-Meijler G, van Straaten H, et al. Punctate white-matter lesions in the full term newborn: underlying aetiology and outcome. *Eur J Paediatr Neurol* 2019;23(2):280–7.
- [28] Nguyen ALA, Ding Y, Suffren S, et al. The brain's kryptonite: overview of punctate white matter lesions in neonates. *Int J Dev Neurosci* 2019;77:77–88.