

Delayed Migration of Onyx Embolic Agent after Preoperative Embolization of an Arteriovenous Malformation in a Pediatric Patient: A Case Report and Review of the Literature

Bailey R. Nussbaum^a Patrick Graupman^b Collin M. Torok^c
Tiffany A. Yesavage^d Eric S. Nussbaum^a

^aDepartment of Neurosurgery, National Brain Aneurysm and Tumor Center, United Hospital, Minneapolis, MN, USA; ^bDepartment of Neurosurgery, Gillette Hospital, Saint Paul, MN, USA; ^cMidwest Radiology, Saint Paul, MN, USA; ^dSuperior Medical Experts, Saint Paul, MN, USA

Established Facts

- Brain arteriovenous malformations are frequently treated with Onyx liquid embolic agent (Onyx, Medtronic, Inc.).
- Delayed, unexpected Onyx migration is not well documented and is extremely rare in pediatric patients.
- The clinical presentation associated with delayed, unexpected Onyx migration is not well understood.

Novel Insights

- A pediatric patient developed headaches and perinidal edema following preoperative AVM embolization, which was the result of delayed, unexpected Onyx migration. Concerns of possible venous outflow obstruction and hemorrhage prompted urgent surgical resection of the AVM.
- Migration of Onyx may occur in a delayed fashion following embolization, with the potential to cause dangerous complications.
- Sudden development of headaches and other signs of perilesional edema should prompt repeat angiographic examination due to the possibility of delayed liquid embolic migration.
- Future research is needed to understand the frequency of delayed Onyx migration from brain AVMs and the possible clinical presentations to look for.

Keywords

Arteriovenous malformations · Pediatric patient · Embolization · Onyx migration

Abstract

Introduction: Brain arteriovenous malformations (AVMs) are increasingly being treated with Onyx liquid embolic agent (Onyx, Medtronic, Inc.). The phenomenon of

delayed Onyx migration is not well documented in the literature. Moreover, the clinical presentation associated with Onyx migration is not well understood. **Case Presentation:** A pediatric patient with a history of neonatal seizures was referred to our institution upon experiencing daily headaches with photophobia, phonophobia, and sleep disturbance. Cerebral angiography revealed an AVM of the medial left cerebellar hemisphere. Preoperative embolization with Onyx liquid embolic achieved 25% closure of the AVM nidus. Upon developing worsening headaches the following day, new perinidal parenchymal edema was revealed on MRI, and urgent angiography demonstrated delayed migration of Onyx into the venous drainage. The patient underwent emergency resection of the AVM due to the risk of hemorrhage resulting from venous outflow obstruction. **Conclusion:** Our report and literature review demonstrate that while the delayed, unexpected migration of Onyx embolic material has been alluded to in a handful of papers, this phenomenon is not well documented. Future research is needed to understand the frequency of delayed Onyx migration from brain AVMs and the possible clinical presentations to look for. The sudden development of headaches and other signs of perilesional edema, in particular, should prompt repeat angiographic examination due to the possibility of delayed liquid embolic migration.

© 2023 The Author(s).
Published by S. Karger AG, Basel

Introduction

Arteriovenous malformations (AVMs) are caused by arteriovenous shunting of coiled and tortuous vascular connections that connect feeding arteries to draining veins [1]. Although microsurgical resection remains the gold standard for treatment of all accessible pediatric AVMs, embolization and radiosurgery are often considered as adjunctive therapy [1]. Onyx liquid embolic agent (Onyx, Medtronic, Inc., Irvine, CA) is a non-adhesive embolic material approved for preoperative embolization of brain AVMs. In this report, we describe a pediatric patient who developed headaches and perinidal edema following preoperative AVM embolization. Ultimately, delayed migration of Onyx occurred following the procedure, which resulted in venous outflow obstruction and prompted urgent surgical resection of the AVM. We conducted a thorough literature review to investigate how common delayed Onyx migration associated with brain AVMs is thought to be in both adult and pediatric populations.

Case Presentation

Patient Information

An 8-year-old female patient was referred to our institution upon experiencing daily frontal headaches with photophobia, phonophobia, and sleep disturbance. She had a history of seizures as a neonate. She also had a history of hypoxic ischemic injury, neurogenic bladder, right-sided hemiplegia, and anxiety. At the time of admission, she was taking Topamax (Janssen Pharmaceuticals, Beerse, Belgium) (25 mg) nightly for daily headaches, which had since become milder and less frequent. Informed consent was obtained from the patient's legal guardian for the publication of this case report and accompanying images.

Clinical Findings, Timelines, and Diagnostic Assessments

Cerebral angiography and MRI revealed an unruptured Spetzler-Martin grade III (S1E1V1; less than 3 cm, dentate nucleus involved, deep venous drainage) (Figs. 1, 2) AVM of the medial left cerebellar hemisphere with a high-flow shunt. The nidus was predominantly compact, measuring 19.6 × 19.1 × 23.4 mm (anteroposterior, transverse, craniocaudal). Arterial supply was from a hypertrophied left superior cerebellar artery. Three mildly dilated venous outlets were observed draining into the vein of Galen, the torcula, and the left transverse sinus/sigmoid/sinus junction, with no significant venous stasis or outflow stenosis observed.

Therapeutic Intervention

Treatment was recommended based on the patient's young age, lesion location, and headaches. The AVM was preoperatively embolized using the plug and push technique, with a combination of Onyx 34 and Onyx 18 to reduce the nidus size before surgical resection. In this method, the catheter was first filled with Onyx 34 and then switched to Onyx 18 to allow the more viscous Onyx 34 to come out first and form a plug to support the forward egress of Onyx 18. We did not observe any procedural errors or complications during the procedure. Approximately 25% of the AVM nidus was closed during the embolization, specifically the deep posteroinferior aspect (Fig. 2). Further injection of Onyx was stopped once minimal penetration of Onyx into the main draining vein was noted, along with some reflux of Onyx along the microcatheter tip. The draining vein remained widely patent without flow delay or visible evidence of an Onyx cast obstruction. No attempt was made to close a significantly greater percentage of the AVM nidus in a single session due to the risk of precipitating a nidal rupture from excessive hemodynamic changes.

The following day, the patient developed worsening headaches, and an MRI demonstrated new perinidal edema (Fig. 3). Urgent angiography showed that Onyx had migrated into the draining vein, presumably resulting in venous outflow obstruction and potentially increasing the risk of bleeding from the AVM. Uneventful, urgent resection of the AVM was performed. Postoperative CT imaging (Fig. 4) revealed postoperative pneumocephalus, and a thin linear object with a hyperdensity compatible with Onyx material was seen extending posteriorly from the resection cavity. The object appeared to extend within or along the margin of the left transverse and sigmoid sinuses to the level of the jugular bulb.

Outcomes and Follow-Up

The procedure was deemed successful as the patient recovered from surgery without any new neurological deficit, and there was no residual filling of the AVM on intra-operative

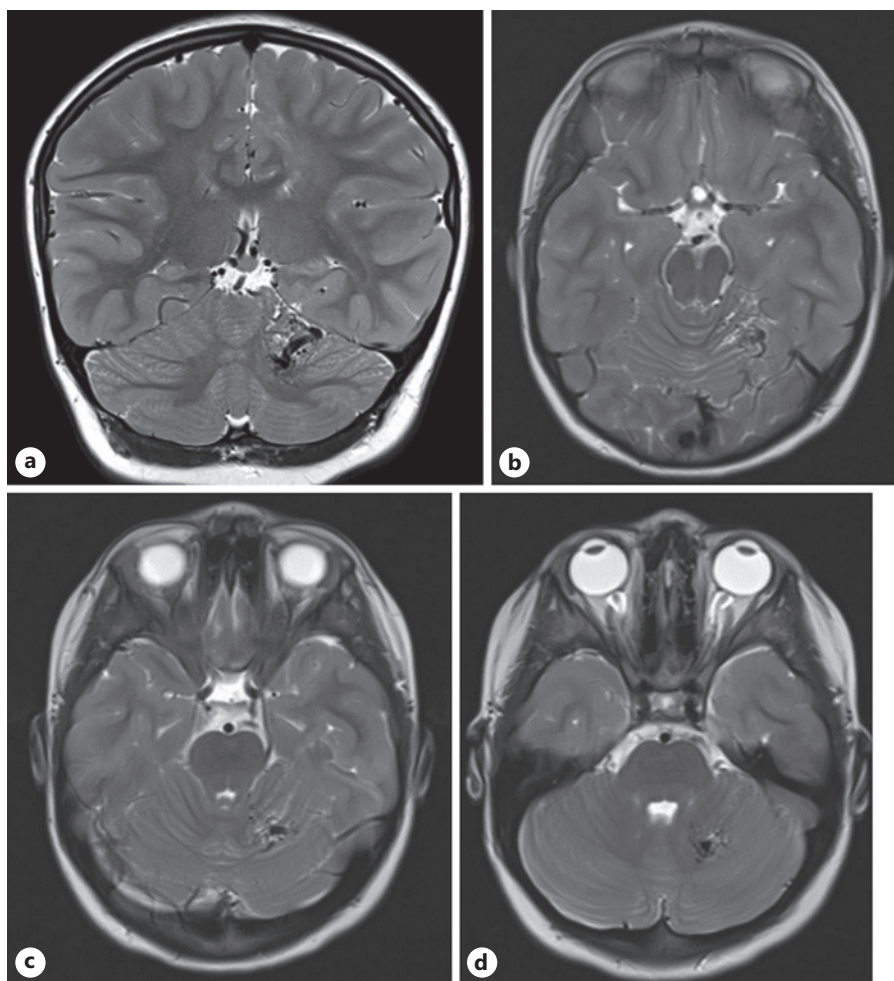


Fig. 1. Preoperative multiplanar T2-weighted MRI images demonstrate the left cerebellar AVM nidus with partial involvement of the left dentate nucleus, as well as adjacent dilated draining veins. **a** Coronal view. **b** Axial view. **c** Axial view. **d** Axial view.

angiography. At 1 month follow-up, she was at her neurological baseline. Magnetic resonance imaging and magnetic resonance angiography have been recommended 1 year after surgery; the timing of follow-up angiograms will be based on the MRI findings.

Discussion

This case report describes a pediatric patient with an unexpected delayed migration of Onyx following preoperative embolization for an intracranial AVM. This case serves to alert neurovascular surgeons to vigilantly monitor for liquid embolic migration in a delayed fashion following an AVM embolization. Delayed migration of Onyx following embolization of an AVM is rarely reported in the literature [2]. Shetty and Mielt [2] suggest that Onyx migration following embolization for brain AVMs is often asymptomatic in clinical presentation, although it could

also present with hypoxemia and superior vena cava syndrome.

Our usual practice is to perform open surgical resection 24–48 h following preoperative embolization. Most AVMs undergo a single embolization session. At the end of the first session, if additional AVM pedicles remain that are deemed readily amenable to embolization, and if the multidisciplinary team feels further embolization would make surgery safer, then further embolization may be used prior to surgery. One of the issues that led to surgery in this case was the concern for occlusion of the draining vein resulting in the potential for impending rupture. Preoperative embolization with Onyx can reduce the amount of intra-operative bleeding during AVM resection by gradually reducing flow and preventing abrupt hemodynamic changes in arterial pressure [3]. However, overall rates of peri-operative hemorrhagic complications are estimated to occur in up to 16.7% of AVMs following embolic embolization with

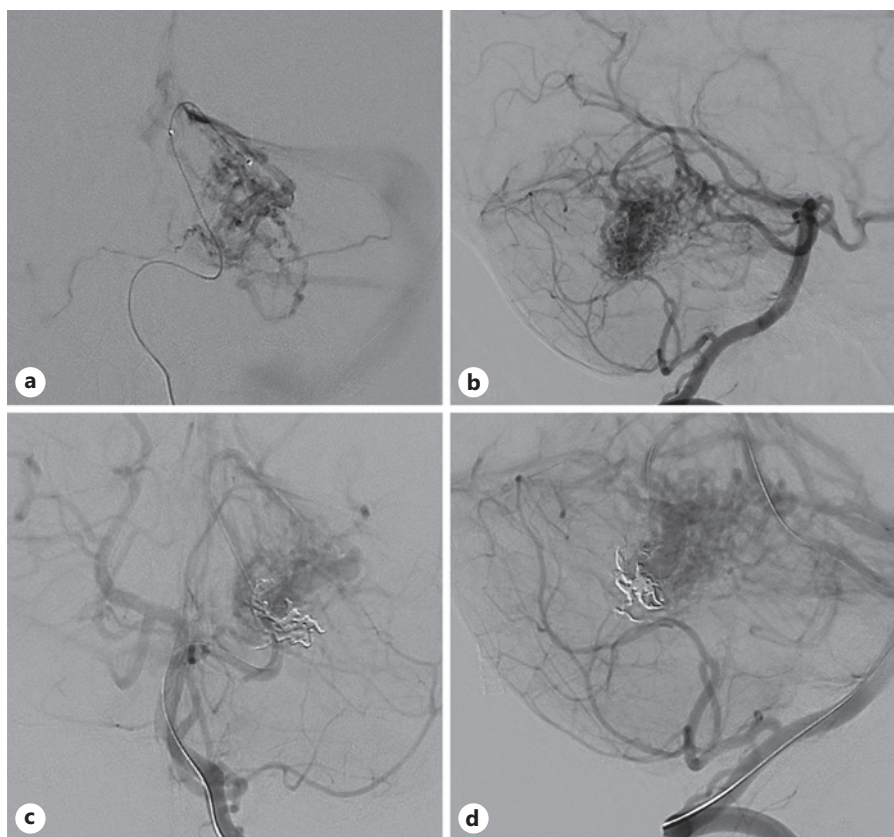


Fig. 2. **a, b** Pre-embolization cerebral angiogram demonstrating an AVM of the medial left cerebellar hemisphere. **c, d** Post-embolization angiogram showing 25% closure of the AVM.

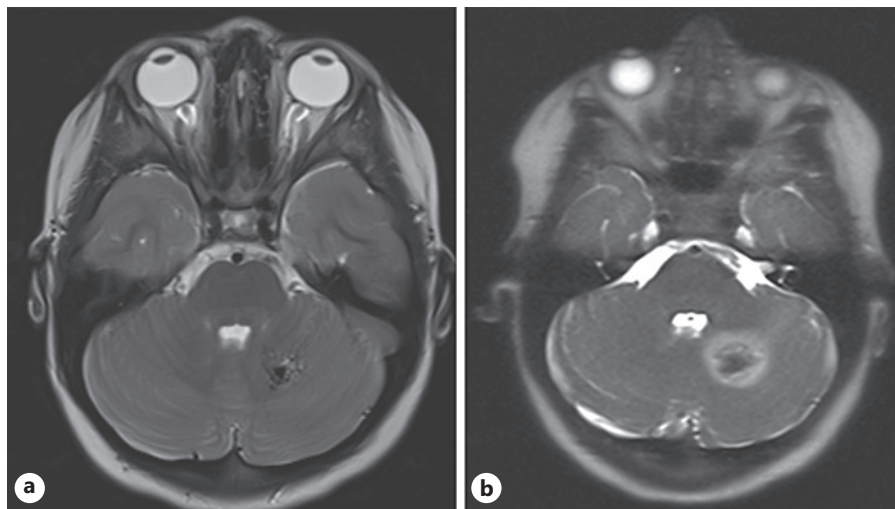


Fig. 3. **a** Pre-procedure axial MRI showing no edema. **b** Post-embolization axial MRI demonstrating new perinidal edema.

Onyx, due to reasons such as vessel perforation, catheter adhesion, draining vein occlusion, pressure changes, and vessel rupture [4].

Onyx is an ethylene vinyl-alcohol copolymer, which has very unique properties compared to n-butyl cyanoacrylate

(nBCA). Cyanoacrylate glues are liquid monomers that form flexible polymers with strong adhesive bonds to soft tissues [5]. When using nBCA, it is important to remove the microcatheter as quickly as possible after injection, to prevent it from becoming glued into the blood vessel and

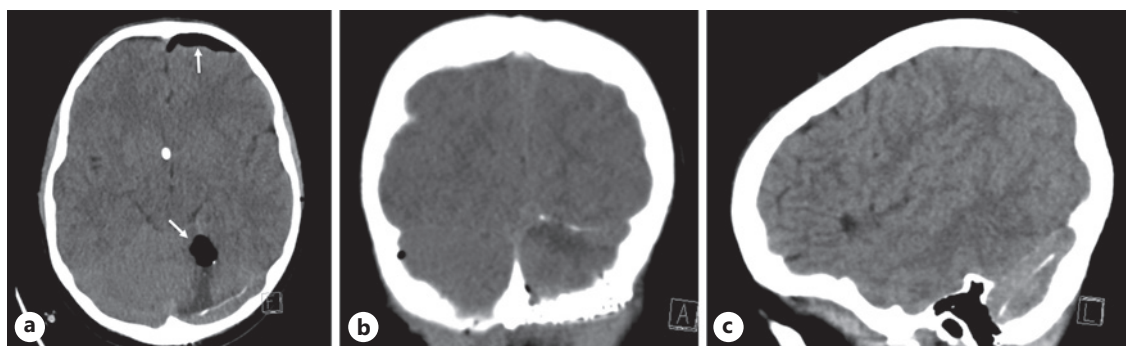


Fig. 4. Post-surgery computed tomography scan demonstrating a thin linear object extending posteriorly from the resection cavity, reflecting the migrated Onyx. **a** Axial view (left). **b** Coronal view (center). **c** Sagittal view (right).

left in place [6]. We are unaware of instances of delayed nBCA migration, which would not be expected given its glue-like properties. Onyx, on the other hand, has a lava-like flow. It takes longer to set and is therefore widely preferred as it affords greater control and time to complete the embolization. While it is still possible for the microcatheter to become stuck when using Onyx, the Onyx cast sticks to itself rather than the blood vessel. Multiple reports of Onyx migration are reported and described below; this is likely related to its fundamentally unique properties.

A review of the literature on delayed postoperative Onyx migration is presented in Table 1. Wang et al. [7] reported unintended Onyx migration into the middle inner ear 6 years following embolization of a right temporal AVM. Crusio et al. [8] documented Onyx migration into a right atrium stent 2 weeks after embolization of the right meningeal artery for a dural AVM. Several cases of delayed Onyx migration have also been reported in patients with dural arteriovenous fistulas (DAVFs). Shi et al. [9] reported Onyx migration in four patients with dural AVFs; one patient with a transverse sigmoid sinus DAVF who underwent a venous balloon-assisted procedure experienced a pulmonary embolism 1 month after surgery due to Onyx migration into the lung. Lv et al. [10] documented Onyx migration to the heart in two patients following embolization of the middle meningeal artery for DAVFs in the transverse sigmoid sinus; one patient sustained a mild tricuspid valve dysfunction 9 months following embolization. Shetty and Miett [2] reported an Onyx migration in a DAVF patient 3 months after embolic repair to the lower lobe branches of the right pulmonary artery. Singla et al. [11] reported a spontaneous Onyx extrusion through the scalp 5 weeks after embolization of the distal left occipital artery for a Borden type 3 DAVF.

Watanabe et al. [12] also documented Onyx extrusion through the scalp 2 months after embolization through the left superficial temporal artery for a superior sagittal sinus DAVF. Finally, Wang et al. [7] documented a patient with a left tentorial DAVF who died during a surgical procedure; it was noted that Onyx migration occluded the distal draining vein and may have led to venous varix rupture.

Liquid embolic migration in pediatric patients has only been alluded to in one study in our review of the literature. Thiex et al. [13] analyzed clinical records of 15 pediatric patients who underwent 36 transarterial embolizations with Onyx for central nervous system arteriovenous lesions. They noted that, in two patients with a vein of Galen malformation, high shunt flow inadvertently carried a tiny stream of Onyx into the venous side of the lesion during the operation. In one of these patients, a thin strand of Onyx extended to within the midline varix of the media vein, remaining attached to the cast on the arterial side without detachment. This patient showed no change in vital signs or clinical signs of distal embolization. In another case, two drops of Onyx were rapidly carried through the venous pouch to the jugular bulb while the patient was undergoing embolization via a branch of the right lenticulostriate artery. The Onyx lodged in the jugular bulb without impeding flow, with no evidence of jugular stenosis. The oxygen saturation and vital signs remained stable and unchanged throughout the procedure.

Conclusions

This report provides evidence that migration of Onyx liquid embolic agent may occur in a delayed

Table 1. Literature review of studies documenting delayed postoperative Onyx migration

Study	Reason for embolization	Embolization details	Migration location	Timing of migration	Complications of migration	Outcome
Crusio et al. (2011) [4]	AVM in the right posterior fossa	Right meningeal artery	Superior vena cava: 2 weeks after embolization, imaging revealed linear structure in superior vena cava, extending to right atrium	Symptoms 2 weeks after embolization	Acute respiratory failure and upper airway obstruction: edema, facial plethora, varices of the chest wall, and stridor	Interventional radiology removed the material, which was determined to be liquid Onyx; symptoms resolved
Lv et al. (2011) [6]	2 DAVFs in transverse sigmoid sinus	Treatment at middle meningeal artery	Heart: Onyx cast found in right cardiac ventricle of two patients	Patient experienced valve dysfunction 9 months after embolization	Patient 1: sustained a mild tricuspid valve dysfunction at 9-month follow-up	Patient 1: bruit; patient 2: cured
Shi et al. (2013) [5]	Patient 3: DAVF in transverse sigmoid sinus	Venous balloon-assisted technique	Lung: pulmonary embolism at 1 month caused by migration	Symptoms at 3 months	Pulmonary embolism at 1 month	Cured
Singla et al. (2015) [7]	Borden type 3 DAVF	Distal left occipital artery	Scalp: 5 weeks after embolization, small pieces of Onyx cast and detached tip of Apollo microcatheter extruded out from scalp through small spontaneous holes	Extrusion after 5 weeks	Spontaneous extrusion of Onyx from the scalp	The surgical incision site was completely healed at the time of the clinic visit
Watanabe et al. (2016) [8]	DAVF (superior sagittal sinus)	Onyx embolization through left superficial temporal artery; transvenous embolization	Scalp: 2 months after embolization, spontaneous Onyx extrusion from the scalp	Symptoms at 2 months	Two months after the last Onyx embolization, the patient complained of scalp pain along the right occipital artery	The scalp incision site completely healed after debridement
Shetty and Miatt (2018) [2]	DAVF	Unknown	Right pulmonary artery: 3 months after embolic repair, chest radiograph revealed a linear radiopaque foreign body	Incidental imaging at 3 months	Shortness of breath, chest tightness, and productive cough for one week; symptoms not necessarily caused by migration	Complete resolution of symptoms
Wang et al. (2019) [3]	AVF (right temporal)	Small perforation of middle meningeal artery during surgery and artery was completely occluded with Onyx-18	Middle ear: symptoms began 6 years after embolization	6 years	Right-sided ear fullness and intermittent ear pressure with hearing loss	After ear surgery, the tympanic membrane had persistent hemotympanum

Table 1 (continued)

Study	Reason for embolization	Embolization details	Migration location	Timing of migration	Complications of migration	Outcome
Current study	AVM (medial left cerebellar hemisphere)	Embolization with Onyx-34 and Onyx-18	Draining vein: Onyx migrated into draining vein, presumably resulting in venous outflow obstruction	1 day	Worsening headaches	Good neurologic outcome at 1-year follow-up

AVM, arteriovenous malformation; DAVF, dural arteriovenous fistula.

fashion following embolization, with the potential to cause dangerous complications. The sudden development of headaches and other signs of perilesional edema should prompt repeat angiographic examination due to the possibility of delayed liquid embolic migration. Furthermore, our report highlights the fact that more work needs to be done to understand the frequency of delayed Onyx migration from brain AVMs and the possible clinical presentations to look for.

Acknowledgment

The authors acknowledge Superior Medical Experts for research and drafting assistance.

Statement of Ethics

Ethical approval is not required for this study in accordance with local or national guidelines. Informed consent for publication was obtained from the patient's legal guardian for the publication of this case report and accompanying images.

References

- 1 El-Ghanem M, Kass-Hout T, Kass-Hout O, Alderazi YJ, Amuluru K, Al-Mufti F, et al. Arteriovenous malformations in the pediatric population: review of the existing literature. *Interv Neurol*. 2016;5(3-4): 218-25.
- 2 Shetty N, Miett T. Incidental finding of Onyx embolization of the pulmonary artery: a rare complication of high flow dural arteriovenous fistula repair. *CHEST Annu Meet*. 2018 Oct 18-21.
- 3 Reynolds MR, Arias EJ, Chatterjee AR, Chicoine MR, Cross DT 3rd. Acute rupture of a feeding artery aneurysm after embolization of a brain arteriovenous malformation. *Interv Neuroradiol*. 2015;21(5):613-9.
- 4 Liu L, Jiang C, He H, Li Y, Wu Z. Periprocedural bleeding complications of brain AVM embolization with Onyx. *Interv Neuroradiol*. 2010;16(1):47-57.
- 5 Hill H, Chick JFB, Hage A, Srinivasa RN. N-butyl cyanoacrylate embolotherapy: techniques, complications, and management. *Diagn Interv Radiol*. 2018;24(2):98-103.
- 6 Triano MJ, Lara-Reyna J, Schupper AJ, Yaeger KA. Embolic agents and microcatheters for endovascular treatment of cerebral arteriovenous malformations. *World Neurosurg*. 2020;141:383-8.
- 7 Wang H, Lv X, Jiang C, Li Y, Wu Z, Xu K. Onyx migration in the endovascular management of intracranial dural arteriovenous fistulas. *Interv Neuroradiol*. 2009;15(3):301-8.
- 8 Crusio R, Ramachandran K, Ramachandran K, Kupfer Y, Tessler S. Superior vena cava syndrome caused by embolisation of liquid Onyx. *BMJ Case Rep*. 2011;2011:bcr1120103502.

Conflict of Interest Statement

Tiffany Yesavage is employed by Superior Medical Experts. The authors report no conflict of interest concerning the materials or methods used in this manuscript.

Funding Sources

This work was supported by a grant from the United Hospital Foundation.

Author Contributions

Bailey Nussbaum, Patrick Graupman, Collin Torok, and Eric Nussbaum were responsible for the conception and design of this study and the interpretation and analysis of data. Tiffany Yesavage performed the literature review and drafted the manuscript. All authors critically revised the manuscript and approved the final version to be published.

Data Availability Statement

All data generated or analyzed during this study are included in this article. Further inquiries can be directed to the corresponding author.

- 9 Shi ZS, Loh Y, Gonzalez N, Tateshima S, Feng L, Jahan R, et al. Flow control techniques for Onyx embolization of intracranial dural arteriovenous fistulae. *J Neurointerv Surg*. 2013; 5(4):311–6.
- 10 Lv X, Jiang C, Li Y, Liu L, Liu J, Wu Z. The limitations and risks of transarterial Onyx injections in the treatment of grade I and II DAVFs. *Eur J Radiol*. 2011;80(3):e385–388.
- 11 Singla A, Fargen KM, Hoh B. Onyx extrusion through the scalp after embolization of dural arteriovenous fistula. *BMJ Case Rep*. 2015;2015:bcr2015011879.
- 12 Watanabe J, Maruya J, Nishimaki K, Ito Y. Onyx removal after embolization of a superior sagittal sinus dural arteriovenous fistula involving scalp artery. *Surg Neurol Int*. 2016; 7(Suppl 14):S410–4.
- 13 Thiex R, Williams A, Smith E, Scott RM, Orbach DB. The use of Onyx for embolization of central nervous system arteriovenous lesions in pediatric patients. *AJNR Am J Neuroradiol*. 2010;31(1):112–20.