

Unilateral Pseudobulbar Syndrome with Limited Capsulothalamic Infarction

M. Rousseaux, F. Lesoin, S. Quint

Service des Convalescents and Service de Neurochirurgie, CHU, Lille, France

Key Words. Cerebral infarction · Internal capsule · Thalamus · Pyramidal tracts

Abstract. A unilateral pseudobulbar syndrome consequent to unilateral capsulothalamic infarction is described. Motor deficit of the face was associated with marked velar and pharyngeal unilateral palsy; paresis of limbs was mild. ACT scan revealed a circumscribed infarction of the genu of the internal capsule. This raised the problem of unilateral supranuclear pharyngeal palsies and of the precise anatomy of the genicular tract in the genu of the internal capsule.

A unilateral glossopharyngeal and laryngeal palsy, ipsilateral to hemiplegia, must evoke the opercular syndrome [1, 2], but it has been recently shown that an isolated lesion of the internal capsule may give rise to the same symptoms.

In the following case, a unilateral pseudobulbar syndrome with velar and pharyngeal palsy was the result of a limited capsular infarction.

Case Report

A 71-year-old man presented at the end of 1984 with left-sided, transient ischemic attacks. Angiography revealed an aneurysm of the cervical internal

carotid artery, which was operated on December 13th, 1984. Immediate postoperative evolution was good, but 4 days later, a left hemiparesis and an important phonation and deglutition deficit arose.

Examination showed a mild left-sided pyramidal deficit. The left facial deficit was important, involving the inferior and upper territories. The masseteric muscle was weak. Swallowing was impossible and this induced a right-sided pneumopathy. Dysphonia was marked. A complete left-sided velar and pharyngeal palsy was noted. Velar and pharyngeal reflexes were initially weak, but recovered in a few weeks, while the pharyngeal palsy remained unchanged. Tongue protrusion was weak, without lateral deviation. Facial, lingual, velar and pharyngeal sensibilities were normal. An oculomotor examination showed a mild deficit of leftward gaze command. On EEG bilateral theta waves were recorded from the temporal and parietal areas. A CT scan (fig. 1) showed a circumscribed

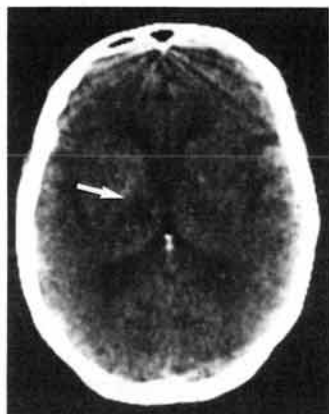


Fig. 1. CT scan. Right-sided capsular (genu) and antero-external thalamic infarction (arrow).

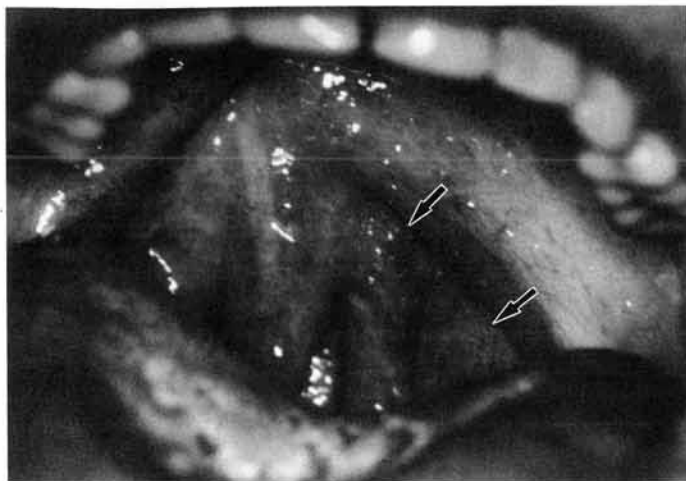


Fig. 2. Left-sided velar palsy (arrows).

hypodensity of the right anterior and external thalamus, which also involved the genu (inner part) and posterior limb (anterior part) of the internal capsule.

In a few weeks, the left-sided paresis resolved. When standing up was possible, a left-sided body deviation was found. The swallowing deficit slowly recovered, oral feeding and later drinking became possible. The voice returned nearly to normal, with mild nasal emission, but the left-sided velar palsy persisted (fig. 2).

The patient was discharged in February, 1985, after a 7 weeks' reeducation time. Reinsertion was good, with complete recovery of functional abilities. Four months later, examination still showed a left-sided paresis of the velum and pharynx.

Discussion

In our patient, a unilateral pseudobulbar syndrome was the result of a limited infarction of the genu and posterior limb of the internal capsule and adjacent anterior thalamus. The clinical symptoms were very similar to the descriptions of unilateral opercular

syndromes of Alajouanine et al. [1], Pertuiset and Perrier [3], Boudin et al. [4], Schott et al. [5], Rebutti et al. [6] and Bruyn and Gathier [2] in cortico-subcortical lesions. In this syndrome, destruction of the upper part of the rolandic operculum gives rise to a pure motor deficit, with predominant involvement of the territories of the cranial nerves V, VII, IX, X, XI and XII. The upper-limb palsy is mild and sometimes absent. Velopharyngeal reflexes are often weak at the beginning but recover rapidly.

Bilateral lacunar infarctions of internal capsule may be associated with similar but bilateral symptoms. Patient No. 7 of Fisher [7] presented with dysphagia and aphemia. In another case (No. 5), complete speechlessness was associated with paralysis of the lips and tongue. Mohr [8] described a patient which 'yielded virtual anarthria, severe dysphonia and dysphagia, but only a mild right arm weakness'. A similar case was presented by Leys et al. [9].

Even if dysphagia and dysarthria caused by unilateral cerebral lesions may be much commoner than most recognize [10], we found only one case with unilateral capsule involvement and documented unilateral buccolingual palsy: Bogousslavsky et al, [11] described a patient with dysarthria and right-sided lingual paresis related, as in our case, to a limited lesion in the genu of the internal capsule. This raised the problem of the precise topography of the frontobulbar motor tracts. In older studies, Brissaud [12] placed the geniculate fasciculus going to the medulla oblongata in the capsular genu. Dejerine [13] situated the tract coming from the rolandic operculum and F3 foot at the same level. In an anatomicoclinical case (patient 'Schweigoffer'), secondary degeneration after opercular lesions was found in the capsular genu and anterior thalamus, in the area of our patient's infarction. According to Brion and Guiot [14], the frontopontine tract is at the level of the genu and the frontobulbar tract behind it in the anterior part of the posterior limb of internal capsule. Furthermore, pedunculo-pontine fibers have a superoinferior and anteroposterior trajectory. Ross [15] confirmed this posterior shifting of the pyramidal tract.

The blood supply of the anterior thalamus comes predominantly from the polar thalamic artery branch of the posterior communicating artery [16], but the adjacent genu of the internal capsule receives branches from the carotid bifurcation [17]. The vascular lesion of our patient was situated in one of these two contiguous territories.

In conclusion, if the unilateral glossopharyngeal supranuclear palsy was classically related to cortico-subcortical structures at the

level of the rolandic operculum, a restricted infarction near the genu of internal capsule may give rise to the same symptoms.

References

- 1 Alajouanine, T.; Boudin, G.; Pertuiset, B.; Pepin, B.: Le syndrome unilatéral de l'opercule rolandique avec atteinte controlatérale du territoire des V, VII, IX, XI et XIIe nerfs crâniens. *Revue neurol.* 101: 168-171 (1959).
- 2 Bruyn, G.W.; Gathier, J.C.: The operculum syndrome; in Vinken, Bruyn, *Handbook of clinical neurology*, vol. 25, pp. 776-783 (North Holland, Amsterdam 1969).
- 3 Pertuiset, B.; Perrier, F.: Le syndrome operculaire unilatéral (rolandique inférieur) d'origine vasculaire. *Revue neurol.* 103: 63-64 (1976).
- 4 Boudin, G.; Pepin, B.; Wiart, J.P.: Le syndrome operculaire unilatéral d'origine vasculaire. *Revue neurol.* 103: 65 (1960).
- 5 Schott, B.; Boulliat, G.; Cotte, L.; Vauterin, C.: Le syndrome operculaire bilatéral et unilatéral. *Lyon méd.* 93: 365-377 (1961).
- 6 Rebucci, G.G.; Gambetti, G.; Bottazzi, G.: Le syndrome unilatéral de l'opercule rolandique. A propos de trois observations cliniques. *Acta neurol. belg.* 64: 1267-1278 (1964).
- 7 Fisher, C.M.: Capsular infarcts: the underlying vascular lesions. *Archs Neurol.* 36: 65-73 (1979).
- 8 Mohr, J.P.: Lacunes. *Stroke* 13: 3-10 (1982).
- 9 Leys, D.; Lejeune, J.P.; Bourgeois, P.; Blond, S.; Petit, N.: Syndrome pseudobulbaire aigu. Infarctus bilatéral de la jonction capsule interne corona radiata. *Revue neurol.* 141: 814-818 (1985).
- 10 Rascol, A.; Clanet, M.; Manelfe, C.; Guiraud, B.; Bonafe, A.: Pure motor hemiplegia: CT study of 30 cases. *Stroke* 13: 11-27 (1982).
- 11 Bogousslavsky, J.; Regli, F.: Hémiparésie avec atteinte linguale. Hématome du genou de la capsule interne. *Revue neurol.* 140: 587-590 (1984).
- 12 Brissaud, E.: Recherches anatomo-pathologiques et physiologiques sur la contracture permanente des hémiparésiques; medical thesis, Paris (1880).
- 13 Dejerine, J.: Anatomie des centres nerveux (Rueff, Paris 1901).

- 14 Brion, S.; Guiot, G.: Topographie des faisceaux de projection du cortex dans la capsule interne et dans le pédoncule cérébral. *Revue neurol*, 110: 123-144 (1964).
- 15 Ross, E.D.: Localization of the pyramidal tract in the internal capsule by whole brain dissection. *Neurology* 20: 59-64 (1980).
- 16 Percheron, G.: Les artères du thalamus humain. I. Artère et territoire thalamiques polaires de l'artère communicante postérieure. *Revue neurol*. 132: 297-307 (1976).
- 17 Dunker, R.O.; Harris, A.B.: Surgical anatomy of the proximal anterior cerebral artery. *J. Neurosurg.* 44: 359-367 (1976).

Received: December 2, 1986

Accepted: March 23, 1987

Dr. M. Rousseaux
Service des Convalescents, CHU
F-59037 Lille Cedex (France)