

Short report

Dynamic spelling alexia

JENNIFER HORNER,* E WAYNE MASSEY†

From the Center for Speech and Hearing Disorders,* Department of Surgery, and Division of Neurology,† Department of Medicine, Duke University Medical Center, Durham, North Carolina, USA

SUMMARY A 59-year-old, right-handed, college-educated male examined after stroke presented spelling alexia with relative sparing of writing. He was not aphasic. A striking feature of the alexia was preserved recognition of letters printed in view by the clinician. He was able to read words through letter-by-letter oral spelling when letters were presented in this dynamic fashion. We describe this as a dynamic form of spelling alexia. Head CT scan showed a large left hemisphere posterior lesion infringing on the corpus callosum, and a right hemisphere opercular lesion. We suggest that sparing of the right parietal-occipital cortex may contribute to the remarkable sparing of dynamic letter reading.

Patients with "pure alexia" present relatively preserved writing and are not aphasic as historically defined.¹ "Visual static agnosia"^{2,3} refers to impaired recognition of static stimuli with relatively preserved recognition of dynamic (that is, moving) stimuli. We describe a case with bilateral infarcts who had a dynamic form of spelling alexia. Recognition of dynamically-presented words was spared, while recognition of statically-presented words was impaired.

Case history

A 59-year-old, right-handed, college-educated white male suddenly developed left body weakness and dysarthria which improved over several days. On evaluation several weeks later (27 March 1982), he had a residual nondominant parietal lobe syndrome with considerable constructional apraxia and a left homonymous hemianopsia. Two weeks later he had an abrupt onset of right body weakness and aphasia. Initially he was somnolent but arousable. He had a left gaze preference and a right homonymous hemianopsia and a right central VII paralysis. Muscle stretch reflexes were symmetrical with a right Babinski sign. Pin prick sensation was decreased on the right. Head CT scan showed decreased density in the left posterior temporal hemisphere without

haemorrhage. He was given anticoagulants because of atrial flutter with 2:1 block. He converted to normal sinus rhythm with digoxin and quinidine. An echocardiogram showed no mural thrombus or mitral valve disease. His hemiparesis improved. A repeat head CT scan (5 April 1982) showed an extensive left posterior cerebral artery distribution infarct. (fig 1). A four vessel cerebral arteriogram demonstrated multiple emboli with normal carotid arteries. He continued to improve but had a persistent right Babinski. Visual fields demonstrated a persistent right superior quadrantanopsia.

Our behaviour evaluation was conducted during a 6 to 9 month period after the stroke (September–November, 1982). The *Western Aphasia Battery** was administered. Spontaneous speech was fluent with intact grammatical form. Speech was free of semantic or phonemic paraphasias. Repetition was intact. Auditory comprehension in response to yes/no questions, body part names, and right-left commands was intact, while response to visual stimuli was moderately impaired. Confrontation naming was 2 of 20 (visual alone), improving to 16 of 20 following combined tactile and semantic/phonemic cues. The Aphasia Quotient was 78.8 (out of 100.0). Writing was characterized by occasional misspellings and simplified grammar but was both legible and sensible. Sentence copying was severely impaired. The writing score was 67.8 (out of 100.0). Reading was his major handicap as reflected in a reading score of 15.0 (out of 100.0). Praxis (oral-nonspeech, ideomotor, and ideational) was intact (60.0 out of 60.0). Drawing was severely impaired (11.0 of 30.0). Mental calculation was spared (24.0 of 24.0). Abstract reasoning as measured by presentation of complex visual problems (Raven's *Coloured Progressive Matrices*⁵) was severely impaired (9.0 of 36.0). A cortical quotient (all *Western Aphasia Battery* subtests combined) was 70.2 out of 100.0 points maximum.

Additional nonstandardised tasks involving scanning,

Presented at the Thirty-Fifth Annual Meeting, The American Academy of Neurology, San Diego, California, May 1983.

Address for reprint requests: Jennifer Horner, PhD, Department of Surgery, Box 3887, Duke University Medical Center, Durham, North Carolina 27710 USA.

Received 2 October 1984 and in final revised form 18 July 1985.

Accepted 23 July 1985

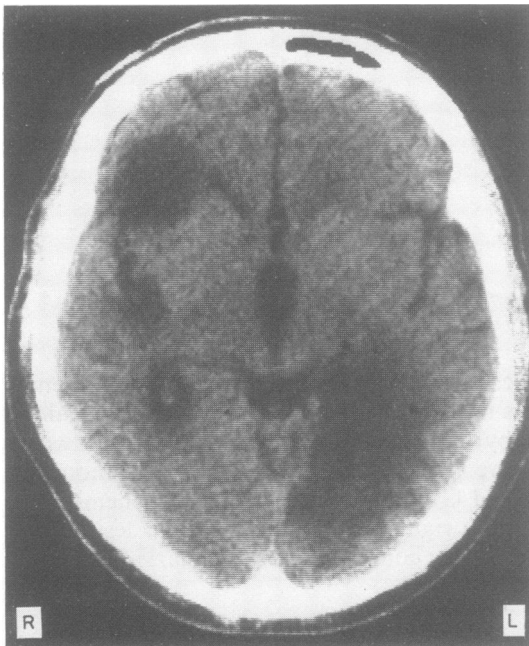


Fig 1 Head CT scan at 9 months after stroke shows lesions in the left posterior temporal region and left occipital region infringing on the posterior corpus callosum. The effect of the various infarctions in the left hemisphere was to create one relatively large lesion. In addition, a right hemisphere opercular lesion is seen.

matching, naming, and copying of both pictorial and linguistic stimuli were presented. Two samples of performance (fig 2) show several problems which we believe adversely affected reading ability: (1) disorganised left-to-right scanning, (2) visual-spatial misperceptions, and (3) inattention to printed stimuli in the right visual field.

His reading impairment was evaluated further using select subtests from the *Battery of Adult Reading Function*.⁶ The table compares his ability to read single words aloud to his ability to write, spell, and name words when spelled. For all types of words, whole-word oral reading was profoundly impaired by comparison to writing to dictation, spelling aloud, and naming words when spelled. Striking exceptions were his ability to name words when spelled and to read words presented *dynamically*. On the latter task, the exam-

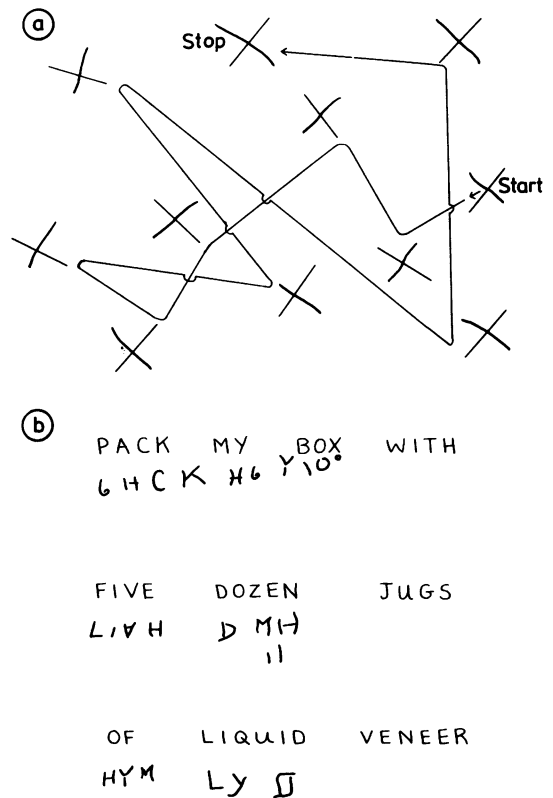


Fig 2 (a) Disorganised visual scanning is shown on a line cross-out task at 6 months after stroke. A line is superimposed to show where the patient stopped and started and the order in which he crossed out the lines. (b) Our patient showed a severe copying deficit characterized by spatial inversions, reversals, simplifications, additions, and frank misperceptions. He was inattentive to the right margin.

iner printed each word at a normal rate (about 1 letter per second) as the patient watched. He responded by orally spelling each word (letter-by-letter) and then saying the whole word. Dynamic presentation of words by the examiner and concurrent letter-by-letter oral spelling by the patient allowed him to read orally words without error.

Correct performance on the Battery of Adult Reading Function⁶

	Read aloud	Write	Spell	Name when spelled
Regular*	0/20 (0%)	19/20 (95%)	19/20 (95%)	20/20 (100%)
Rule-Governed†	0/20 (0%)	14/20 (70%)	16/20 (80%)	20/20 (100%)
Irregular‡	0/20 (0%)	15/20 (75%)	16/20 (80%)	20/20 (100%)
Dynamic presentation, via letter-by-letter Oral Spelling§	60/60 (100%)			

*Regular words, for example, hotel, transfer, momentarily.

†Rule-governed words, for example, sign, doubt, ritual.

‡Irregular words, for example, isle, yacht, mischief.

§Dynamic presentation included all word types.

Discussion

This performance appears to be a dynamic form of spelling alexia. Spelling alexia is defined as the inability to read words and phrases with relative sparing of the ability to read individual letters.^{7,8} Visual static agnosia^{2,3} refers to impaired recognition of statically-presented stimuli with relatively preserved recognition of dynamically-presented stimuli. We have described a case who was unable to read static words, but was able to orally read individual letters in sequence with subsequent recognition of words when presented dynamically. We believe this to be a dynamic form of spelling alexia.

Early studies concerned with the anatomical correlates of acquired reading disorders ascribed pure alexia to a combined lesion in the left occipital lobe and splenium of the corpus callosum.⁹ The present case had a large left hemisphere lesion posteriorly and a right hemisphere opercular lesion. The neuro-anatomical substrate for his pure alexia is very likely the large left posterior hemisphere infarct.

The question remains: What is the neural mechanism underlying his preserved dynamic spelling ability? Two possible explanations are suggested. First, if only the splenial fibres of the corpus callosum were affected and visual information were available to the right hemisphere, some of this information possibly may have crossed to the left hemisphere via corpus callosum anterior to the splenium and thus interpreted in classical left hemisphere language cortex. Second, it is possible that the spared right hemisphere parietal-occipital cortex alone subserved recognition of dynamic stimuli. Our speculations are tempered by the current literature, which is controversial regarding the role of the right hemisphere in processing dynamic or moving stimuli.^{10,11} We suggest that sparing of the right hemisphere posterior cortex may account for, or contribute to, the remarkable sparing of dynamic letter reading by this man.

The reproducibility of this finding in other cases of pure alexia (notably spelling alexia) will provide fur-

ther insight into the cortical substrates of preserved dynamic letter reading in the context of otherwise severe alexia without agraphia. This observation is noteworthy because of potential implications for understanding reading mechanisms and for treating acquired alexia. Brain-damaged patients should be observed routinely for differences in ability between static and dynamic reading.

References

- ¹ Benson DF. *Aphasia, Alexia and Agraphia*. New York, Churchill Livingstone, 1979.
- ² Botez MI, Serbanescu T, Vernea I. Visual static agnosia with special reference to literal agnosic alexia. *Neurology* (Minneapolis) 1964;14:1101-11.
- ³ Botez MI, Serbanescu T. Course and outcome of visual static agnosia. *J Neurol Sci* 1967;4:289-97.
- ⁴ Kertesz A. *Western Aphasia Battery*. New York, Grune & Stratton, 1982.
- ⁵ Raven JC. *Coloured Progressive Matrices*. London, HK Lewis & Co., 1962.
- ⁶ Rothi LJ, Coslett B, Heilman KM. *Battery of Adult Reading Function: Experimental Edition*. Gainesville FL, Department of Neurology, 1983.
- ⁷ Kinsbourne M, Warrington EK. The localizing significance of limited simultaneous visual form perception. *Brain* 1963;86:697-705.
- ⁸ Warrington EK, Shallice T. Word-form dyslexia. *Brain* 1980;103:99-112.
- ⁹ Dejerine J. Contribution a l'etude anatomo-pathologique et clinique des differentes varietes de cecite verbale. *Memoires de la Societe de Biologie* 1982;4:61-90. In: Heilman KM, Valenstein E, eds. *Clinical Neuropsychology*. New York, Oxford University Press, 1979:59-91.
- ¹⁰ Poizner H, Battison R, Lane H. Cerebral asymmetry for American Sign Language: The effects of moving stimuli. *Brain Lang* 1979;7:351-62.
- ¹¹ Helm-Estabrooks N, Fitzpatrick PM, Barresi B. Visual action therapy for global aphasia. *J Speech Hear Disord* 1982;47:385-9.