

Letters

Ideomotor apraxia arising from a purely deep lesion

Sir: Ideomotor apraxia arising from a purely deep lesion has not been reported frequently in the literature. Even in the few cases published,^{1,2} the lesions were not strictly confined to the basal ganglia. Systematic studies,^{3,4} however, have revealed the presence of ideomotor apraxia in about 15% of patients with lesions confined to thalamic or lenticular regions. We report the case of a patient with a haemorrhage confined to the head of the left caudate nucleus and the contiguous arm of the internal capsule, who had severe ideomotor apraxia and aphasia as well. Even though the haemorrhagic nature of the lesion renders the interpretation of the anatomoclinical correlations rather difficult, this case is interesting because of the coexistence of severe ideomotor apraxia and a deep lesion.

A 61-year-old right-handed male with 4 years of education suddenly developed aphasia and a right hemiparesis. Three subsequent CT scans performed on the 1st, 8th and 19th day after onset, showed a small area of increased density consistent with an intraparenchymal haemorrhage limited to the head of the left caudate nucleus, the anterior limb of the internal capsule and the medial part of the lenticular nucleus (fig). Neuropsychological assessments were performed 20 days after onset. His speech was dysarthric. In oral confrontation naming there were frequent word-finding difficulties with rare circumlocutions and semantic

paraphasias. Oral comprehension was impaired: he scored 15/36 on the Token Test. Spontaneous writing and writing to dictation were impossible: he produced isolated signs among which only few letters were recognisable. Repetition was good except for being dysarthric. He scored 5/36 on the Raven's Coloured Progressive Matrices. He had no oral apraxia. Testing for constructional apraxia was impossible: in every instance the patient tried to write instead of copying the model. He scored 35/72 (cut-off score: 53/72)⁵ on De Renzi⁶ ideomotor apraxia test. There was no difference between arm/hand movements (18/36) and finger movements (17/36). There was, however, a striking difference between single movements (25/36) and sequences (10/36).

Our patient also had a mild apraxia of use: for instance, when asked to light a candle he could not manage to light the match. Aphasia following a deep lesion has long been accepted⁷ and it will not be commented on. Ideomotor apraxia arising from a purely deep lesion has been occasionally reported in group studies. Our patient had a small and well localised lesion which caused, among other deficits, a severe ideomotor apraxia. It would seem that the role of deep structures in the genesis of apraxia, not taken into account by the majority of authors with few exceptions,^{8,9} deserves reconsideration.

ANNA BASSO,
SERGIO DELLA SALA,
Neuropsychology Center,
University of Milan,
Via F Sforza, 35,
20122 Milan, Italy

References

- ¹ Von Monakov C. Die Lokalisation im Grosshirn und der Abbau der Funktion durch kortikale Herde. Wiesbaden: Bergmann, 1914:489-574.
- ² Kleist K. Die psychomotorischen Störungen und ihr Verhaeltnis zu den Motilitaetsstoerungen bei Erkrankungen der Stammganglien. *Monatsschrift fuer Psychiatrie und Neurologie* 1922;521:253-302.
- ³ Basso A, Luzzatti C, Spinnler H. Is ideomotor apraxia the outcome of damage to well-defined regions of the left hemisphere? Neuropsychological study of CT correlation. *J Neurol Neurosurg Psychiatry* 1980;43:118-26.
- ⁴ Basso A, Faglioni P, Luzzatti C. Methods in neuro-anatomical research and an experimental study of limb apraxia. In: Roy EA, ed. *Neuropsychological Studies of Apraxia and related disorders*. Amsterdam: North-Holland, 1985.
- ⁵ De Renzi E, Faglioni P, Sorgato P. Modality-specific and supramodal mechanisms of apraxia. *Brain* 1982;105:301-12.
- ⁶ De Renzi E, Motti F, Nichelli P. Imitating gestures: a quantitative approach to ideomotor apraxia. *Arch Neurol* 1980;37:6-10.
- ⁷ Marie P. Revision de la question de l'aphasie: que faut-il penser des aphasies sous-corticales? *Sem Med* 1906;42:493-500.
- ⁸ Hore J, Meyer-Lohmann J, Brooks VB. Basal ganglia coding disables learned arm movements of monkeys in the absence of visual guidance. *Science* 1977;195:584-6.
- ⁹ Kimura D. Neuromotor mechanisms in the evolution of human communication. In: Steklis HD, Raleigh MJ, eds. *Neurobiology of Social Communication in Primates: an Evolutionary Perspective*. New York: Academic Press, 1979:197-219.

Unusual EEG pattern in rubella encephalitis

Sir: Encephalitis is a rare but well recognised complication of rubella infection.¹ The EEG findings in the acute phase²⁻⁵ are reported to show continuous slow activity with no specific features. We report a case of rubella encephalitis with unusual repetitive complexes.

A 15-year-old Japanese boy with no past history or family history of note, presented with a 4 day history of fever and rash. The rash started on the face, spread down to the body, and faded 2 days later. The day prior to admission, he developed headache and dizziness and within 24 hours had become drowsy and lapsed into coma. Examination revealed an unconscious, restless patient only responding semi-purposefully to painful stimuli. There was moderate neck stiffness but no focal neurological deficit. The pupils were 4 mm in diameter, and reacted to light. The fundi were normal. Deep

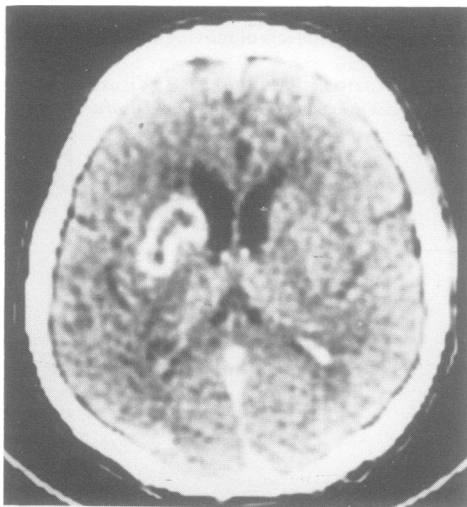


Fig Post-contrast CT scan 8 days from onset. The luxury perfusion well defines the infarcted area.