

# Clinical and electrophysiological study in a patient surviving from locked-in syndrome

W.I.M. Verhagen\*, P.L.M. Huygen\*\*, and B.P.M. Schulte\*

## Introduction

A 'locked-in' condition was first described by Alexandre Dumas in 'The Count of Monte Cristo' (1844). In this novel the character of Noirtier de Villefort became 'a corpse with living eyes', able only to communicate by moving his eyelids. In the medical literature the locked-in syndrome was first mentioned as such by Plum & Posner<sup>1</sup>. Their patient was tetraplegic, mute but fully alert and had interruption of the corticobulbar and cortico-spinal tracts by an infarction of the ventral pons. The communication was restricted to blinking and vertical eye movements. The locked-in syndrome is not only found in vascular lesions such as pons and mid-brain infarction with or without basilar artery occlusion or brain stem haemorrhage<sup>1-7</sup>. Other causes (reviewed by McCusker *et al.*<sup>8</sup>), are pontine tumour, abscess, trauma and myelinolysis, postvaccinal encephalitis, postinfective polyneuropathy, air embolism and heroin abuse. Recently, the syndrome has been also observed in multiple sclerosis<sup>9</sup>, after chiropractic manipulation<sup>10</sup>, due to a vascular malformation, a megadolicho-basilar artery<sup>11</sup> and following Reye's syndrome<sup>12</sup>. Most patients with a ventral pontine infarction die because of the extension of the lesion or secondary respiratory complications<sup>5-7</sup>. We describe a patient with substantial recovery after a ventral pontine infarction in

## Summary

The results of clinical and electrophysiological investigations in a patient with a locked-in syndrome due to a pontine infarction, mainly on the right side, are presented. EEG showed only slight disturbances, while BAER and SSER revealed response alterations as could be expected from physical examination. BAER revealed altered central conduction after stimulation of either side. After median nerve stimulation on the right side SSER was slightly delayed, while no reproducible cortical response was seen after stimulation on the left side. Our patient survived and showed partial recovery.

Key words: SSER, BAER, locked-in syndrome

whom we were able to examine a number of EEG's and evoked responses.

## Methods

Somatosensory evoked responses (SSER) were elicited by median nerve stimulation at the wrist. Potentials were recorded from the cervical spine (C7) and the scalp (Cz, C3' and C4', conform to the 10-20 system). Stimulus rate was 2.5 Hz, duration 100 µsec. Brain stem auditory evoked responses (BAER) were evaluated with condensation- and rarefaction clicks (70 dB hea-

\* Institute of Neurology, \*\* Department of Otorhinolaryngology, St. Radboud Hospital, Catholic University of Nijmegen, Nijmegen, The Netherlands

Address for correspondence and reprint requests: W.I.M. Verhagen, Institute of Neurology, St. Radboudhospital, Postbus 9100, 6500 HB Nijmegen, The Netherlands

Accepted 27.9.85

ring level) with leads from the forehead and the mastoid process on either side.

### Case History

A 53-year-old man had been in good health except for an eye injury due to a grenade explosion in 1948 resulting in a severe loss of vision in the right eye, but leaving light perception intact. In December 1982 he complained about a dull pain on the right side of his neck and paresthesia in the right arm, but these symptoms soon disappeared. Within a few hours, however, his complaints returned in association with a rightsided hemiparesis and slurred speech. After admission to a hospital elsewhere the patient also experienced increasing weakness on the left side and finally became unable to swallow, speak or move. There was a gaze paralysis to the right with a left-beating nystagmus. He was a bit drowsy, but communication was possible by blinking of the eyes. The clinical diagnosis of basilar artery thrombosis was made and he was treated with dexamethasone and warfarin. At admission to our hospital, the blood pressure was 130/85 mm Hg, the pulse 80/min regular and ECG was undisturbed. Physical examination revealed divergent strabismus, a senile arc in the left eye and synechiae in the right anterior eye chamber. He was a bit drowsy but his reactions were adequate. The pupils were equally small and light reflexes were present on both sides. Vision and hearing seemed to be unchanged.

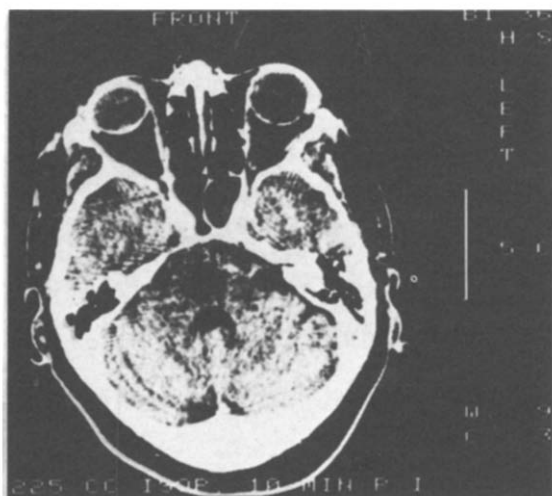


Fig. 1.  
CT-scan at the pontine level. A clear hypodense area (maximum diameter of the lesion is in this plane) is seen at the basis pontis, mainly on the right side.

There was a spontaneous conjugate deviation of the eyes to the left. Vertical eye movement was intact, but horizontal movement was impossible. The corneal reflex was lower on the right side, but facial sensation was intact. There was a bilateral central facial motor paresis, although blinking was possible. Movements of the jaws, palate, tongue and head were absent. The patient had a flaccid tetraplegia with little symmetric reactions on noxious stimuli. Body sensation seemed to be undisturbed. The stretch reflexes showed moderate bilateral activity with bilateral extensor plantar reflexes. The abdominal skin reflexes were absent. Laboratory examinations were unremarkable. Our diagnosis was a locked-in syndrome due to ventral pontine infarction mainly on the right side. CT-scans showed a hypodense area mainly on the right side of the pons, ventral to the IVth ventricle with maximum (rostrocaudal) diameter of 1.5 cm. After i.v. contrast there was no enhancement (Fig. 1).

In Doppler blood flow measurements no disturbances were seen in carotid artery flow. The EEG was only mildly disturbed and showed dominant 8 Hz activity in the parieto-occipital area with amplitude 30-70  $\mu$ V. Some 7 and 8.5 Hz activity with scattered delta waves was present. The fronto-central area showed 15-25 Hz activity (amplitude 15  $\mu$ V) with frontotemporal polyrhythmic theta frequency activity. Photoc driving response was present during photic stimulation. A normal alpha blocking response was seen after opening the eyes. On the 6th day the patient's pulmonary condition worsened; he became febrile and showed irregular cluster breathing. Chest X-ray was indicative of atelectasis or infiltration. He was transferred to the intensive care unit. Nutrition was maintained by a naso-gastric tube. After intubation he received oxygen. Later on a tracheotomy was performed. The artificial ventilation could be terminated on the 17th day. Thence he was able to move his right arm and leg and his head. After discharge from the intensive care unit, the temperature became normal under antibiotic treatment. First he was able to communicate by blinking, later on by using a word and letter board as he learned to use his right hand again. The stretch reflexes were hyperreactive on both sides but lower on the right. During the follo-

wing month his paresis on the right side diminished and some motor activity developed in muscles supplied by the Vth, IXth, Xth, XIth and XIIth cranial nerves on both sides. During the first 2 months the patient showed mild, pseudo-bulbar emotional lability and gnashing of teeth but he was well aware of it. After 2 months abduction was possible for both eyes, but adduction was, bilaterally, impossible. The leftsided hemiparesis recovered somewhat. After closure of the tracheostoma, 2 weeks later, training of swallowing and speaking was initiated. At that time neurological examination revealed partial return of horizontal eye mobility, partial hearing loss on the right side (not present before the stroke) and a leftsided sensory loss for all modalities. There was still a mainly rightsided bulbar paresis of pharyngeal, palatal and lingual muscles. The pharyngeal reflex was weaker on the right side. Rehabilitation was delayed by his poor lung function. Three months after admission he was transferred to a rehabilitation centre, while still having dysarthria, pharyngeal paresis and partial hearing loss on the right side and a leftsided hemihypesthesia. The quadriplegia was most severe on the left side. Twelve months later the clinical condition was almost the same except for the fact that he also had myoclonic jerks of his head and extremities. He was sitting in a wheelchair and had a rather good function of his right arm and leg (muscle strenght gr.3-4). Swallowing and speaking was possible.

## Results

After admission SSER was slightly disturbed on the right and heavily disturbed on the left (Fig. 2); the response was unaltered 14 months later.

In BAER wave IV and V were difficult to distinguish separately on both sides due to vague form distension, the I-III waves being normal (Fig. 3). Pure tone audiograms revealed a clear sensorineural hearing loss on the right; the threshold was 50dB for 0.5-2 kHz, decreasing to 30dB at 8 kHz. The stapedial reflexes were normal on both sides.

## Discussion

Reports on survival from locked-in syndrome

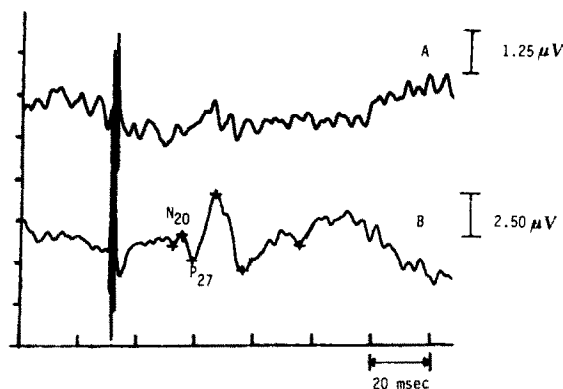


Fig. 2.

SSER after stimulation of the left (A) and right (B) median nerve at the wrist. Stimulus duration 100  $\mu$ sec, rate 2.5 Hz. Amplifier low cut-off filter 5 Hz, high cut-off filter 500 Hz; average of 1000 single responses. Note absence of response in (A). Latency of N20 24.6 msec and of P27 28.4 msec (B).

are rare<sup>8</sup>. Most patients died; recovery is often incomplete as in our patient. Reviewing the literature, Liu *et al.*<sup>13</sup> found that 31 of 34 reported cases died within a few weeks from onset. Three patients survived for over two years<sup>5,14</sup>. Upon neurological examination we concluded that our patient had a pontine infarction on the right side extending to and over the midline, as confirmed by CT-scans. He had lesions at the pontine level in both cortico-spinal and cortico-bulbar tracts, the medial lemniscus on both sides, the right spinothalamic tract, the medial longitudinal fasciculus on both sides (as apparent from impairment of adduction) and the entry zone of the VIIIth nerve (see below). It is surprising that patients with such lesions are not unconscious. It can be stated that consciousness depends on the integrity of the reticular formation in the rostral pons and midbrain areas, which are preserved in the locked-in syndrome<sup>1</sup>. Chase *et al.*<sup>3</sup> found that in the largest lesion with normal state of alertness the lesion involved most of the base and no more than 25% of the pontine tegmentum on one side. Therefore EEG shows only mild disturbances just as in our patient (see also<sup>5,6,14,15</sup>). The reason is sparing of the rostral pontine tegmentum with its central reticular pathway, which is supplied by the superior cerebellar artery<sup>16</sup>. The breathing irregularity may be due to vascular insufficiency in the lower pontine and upper medullar tegmentum. Gnashing of teeth and spasm of the jaw musculature have been also described in a patient by Feld-

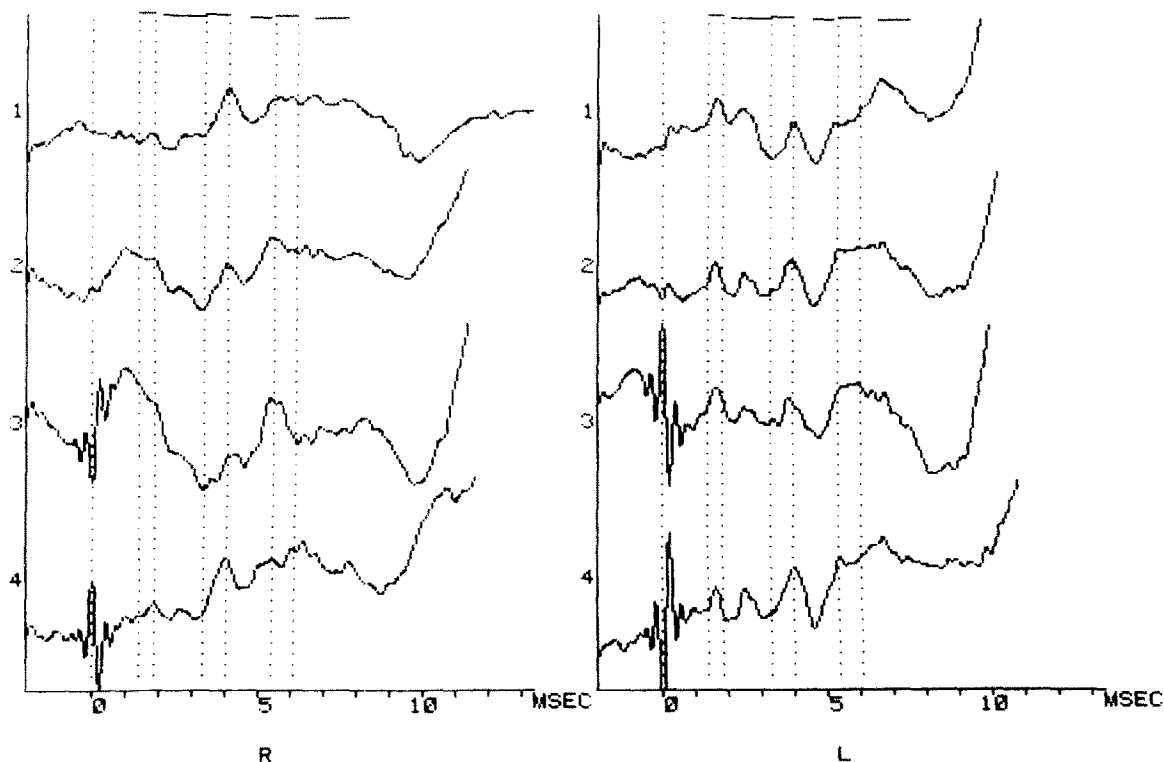


Fig. 3.  
BAER from stimulation of the right (R) and left (L) side. (1) alternating stimulation (N=4800); (2) average of (3) and (4); (3) condensation clicks only (N=1600); (4) rarefaction

clicks only (N=1600). The stimulus was a click of 70 dB HL intensity, repetition rate 9 Hz. The dashed lines indicate the normal limits for male adults for the waves I, III and V.

man<sup>14</sup>. The lesion responsible for jerky rhythmic myoclonus of various muscles can be localized in the pons in what is known as the Guillain-Mollaret triangle. The timing is noteworthy: in our patient myoclonus appeared after several months. This can be explained by the fact that it appears not until sufficient time has lapsed for degeneration of neurons projecting to the inferior olive and glial proliferation resulting in what is known as inferior olive pseudohypertrophy as reported for palatal myoclonus<sup>17</sup>. Unfortunately, our patient was not reexamined for palatal myoclonus.

Preservation of hearing is typical of the locked-in condition. In our patient hearing was clearly disturbed on the right, although to a limited degree, probably due to a lesion in the VIIIth nerve entry zone. BAER showed disturbances on both sides for late wave activity. These waves were present but with morphological deterioration, probably indicating desynchronization. Similar findings have been reported by Seales *et al.*<sup>18</sup>. These authors also concluded prolonged peak latencies for waves

IV-V, but judging the published responses we would be more hesitant. Increased latency had been concluded before in locked-in syndrome by Gilroy *et al.*<sup>19</sup> and Portenoy *et al.*<sup>20</sup>. In principle, the sensorineural hearing loss on the right in our patient could be expected to be associated with prolonged latency for peaks IV-V on the other side of the pons, after the decussation, provided that sufficient synchronized lateral lemniscus activity could be picked up. The lack of such activity, on both sides in this case, is indicative of a diffuse lesion of nerve fibers in the central pons on their way to the lateral lemniscus. SSER was especially disturbed on stimulation of the left median nerve as expected<sup>14</sup>. After photic stimulation the patient showed photic driving, as reported in similar cases<sup>6</sup>, indicating intact visual afferent projection to the occipital lobe and normal reactivity.

#### Acknowledgements

The authors are indebted to G.P.M. Wolters for supplying patient data, J.L. Merx for CT-scans and E.J. Colon and M. Hoekstra for response data.

## References

- <sup>1</sup> PLUM F, POSNER JB. The diagnosis of stupor and coma. Philadelphia, FA Davies Co. 1966.
- <sup>2</sup> BAUER G, GERSTENBRAND F, RUMPL E. Varieties of the locked-in syndrome. *J Neurol* 1979; 221:77-91.
- <sup>3</sup> CHASE TN, MORETTI L, PRENSKY AL. Clinical and electroencephalographic manifestations of vascular lesions in the pons. *Neurology* 1968; 18:357-68.
- <sup>4</sup> DEHAENE I, DOM R. A mesencephalic locked-in syndrome. *J Neurol* 1982; 227:255-9.
- <sup>5</sup> HAWKES CH. "Locked-in" syndrome: report of seven cases. *Br Med J* 1974; 4:379-82.
- <sup>6</sup> MARKAND ON. Electroencephalogram in "locked-in" syndrome. *Electroencephalogr Clin Neurophysiol* 1976; 40:529-34.
- <sup>7</sup> NORDGREN RE, MARKESBERY WR, FUKUDA K, REEVES AG. Seven cases of cerebromedullospinal disconnection: the locked-in syndrome. *Neurology* 1971; 21:1140-8.
- <sup>8</sup> MCCUSKER EA, RUDICK RA, HONCH GW, GRIGGS RC. Recovery from the "locked-in" syndrome. *Arch Neurol* 1982; 39:145-7.
- <sup>9</sup> FORTI A, AMBROSETTO G, AMORE M, DE MARIA R, MICHELUCCHI R, OMICINI E, RIZZUTO N, FENZI F, TASSINARI CA. Locked-in syndrome in multiple sclerosis with sparing of the ventral portion of the pons. *Ann Neurol* 1982; 12:393-4.
- <sup>10</sup> HORN SW. The "locked-in" syndrome following chiropractic manipulation of the cervical spine. *Ann Emerg Med* 1983; 12:648-50.
- <sup>11</sup> SCHOENMAKER RTH. Locked-in syndrome caused by megalolicho vascular malformation of the basilar artery. *Clin Neurol Neurosurg* 1984; 86:159-62.
- <sup>12</sup> KOTAGAL S, ROLFE U, SCHWARZ KB, ESCOBER W. "Locked-in" state following Reye's syndrome. *Ann Neurol* 1984; 15:599-601.
- <sup>13</sup> LIU J, TUHRIM S, WEINBERGER J, SONG SK, ANDERSON PJ. Premonitory symptoms of stroke in evolution to the locked-in state. *J Neurol Neurosurg Psychiatry* 1983; 46:221-6.
- <sup>14</sup> FELDMAN MH. Physiological observations in a chronic case of "locked-in" syndrome. *Neurology* 1971; 21:459-78.
- <sup>15</sup> MURPHY MJ, BRENTON DW, ASCHENBRENER CA, VAN GILDER JC. Locked-in syndrome caused by solitary pontine abscess. *J Neurol Neurosurg Psychiatry* 1979; 42:1062-5.
- <sup>16</sup> BIEMOND A. Thrombosis of the basilar artery and the vascularization of the brainstem. *Brain* 1951; 74:300-17.
- <sup>17</sup> ASH PR, KELTNER JL. Neuro-ophthalmic signs in pontine lesions. *Medicine* 1979; 58:304-20.
- <sup>18</sup> SEALES DM, TORKELSON RD, SHUMAN RM, ROSSITER VS, SPENCER JD. Abnormal brainstem auditory evoked potentials and neuropathology in "locked-in" syndrome. *Neurology (Ny)* 1981; 31:893-6.
- <sup>19</sup> GILROY J, LYNN GE, RISTOW GE, PELLERIN RJ. Auditory evoked brainstem potentials in a case of "locked-in" syndrome. *Arch Neurol* 1977; 34:492-5.
- <sup>20</sup> PORTENOY RK, KURTZBERG D, AREZZO JC, SANDS GH, MILLER A, VAUGHAN HG. Return to alertness after brainstem hemorrhage. A case with evoked potential and roentgenographic evidence of bilateral tegmental damage. *Arch Neurol* 1985; 42:85-8.