

# Chronic subdural haematoma from cerebral arteriovenous malformation

E. Pozzati, F. Tognetti, G. Gaist

Division of Neurosurgery, Ospedale Bellaria, Bologna/Italy

Intracranial bleeding is a complication of 40 to 80% of cerebral AVMs, with haemorrhage occurring most frequently in the subarachnoid space and/or within the cerebral parenchyma (6, 9–11, 20). On rare but well documented occasions blood ruptures the arachnoid membrane and accumulates acutely as well as massively in the subdural space (12, 15, 21).

The presence of discrete, progressive accumulation of blood in the subdural space overlying a cerebral AVM is exceptional (16). This circumstance has been encountered in one of our 122 reviewed cases of the period 1970–1983, in which the AVM's symptoms were overlooked for several years until intracranial hypertension developed after a trivial head injury.

## Case report

This woman aged 35 years was known to suffer from grand mal seizures for ten years; epilepsy was partially controlled by medical treatment. Past medical history was otherwise non-contributory. She came to our observation 25 days after a head injury sustained during a seizure; mild obtundation had persisted over the weeks following injury, along with some troubles of speech and a left-sided weakness.

Examination on admission revealed a drowsy, uncooperative patient. Mild neck stiffness and left hemiparesis were present. The remainder of the neurological examination was normal.

Right carotid angiography showed no abnormalities in the ipsilateral cerebral hemisphere, while the contrast medium crossed the midline in large amounts and outlined the left anterior circulation. An extracerebral avascular space, 3 cm in its major thickness, was demarcated in the left fronto-temporal convexity, ipsilateral to the hemiparesis, with moderate shift of both the anterior cerebral arteries (ACAs) to the right side. A roundish area of pathological circulation lay within the left frontal lobe (Fig. 1).

Left carotid angiography confirmed a frontal AVM,  $5 \times 4 \times 4$  cm in size; the lesion was fed by hypertrophic frontal arteries from the Sylvian group and was drained rostrally into the superior sagittal sinus. Probably due to steal phenomenon, the ipsilateral ACA was not shown (Fig. 2).

The patient underwent a left frontal craniotomy. After the dural flap was elevated, a chronic haematoma with amber-coloured, semi-fluid content was discovered; the collection was evacuated and the inner capsule of the haematoma carefully separated from the cortical surface. The AVM was resected completely.

The patient exhibited non-fluent aphasia as a postoperative complication. Control carotid angiography confirmed both the complete obliteration of the AVM and the re-expansion of the left cerebral hemisphere. Both the aphasia and the left hemiparesis showed steady improvement over the ensuing days until discharge.

At the time of writing, some years after operation, the patient remains seizure-free and aphasic spells are the only complaint.

## Summary

In a review of 122 intracranial arteriovenous malformations (AVMs) observed between 1970 and 1983, we have found the extremely rare occurrence of a chronic subdural haematoma overlying a frontal AVM. In this case the picture of a presumed primary epilepsy was complicated by symptoms of raised intracranial pressure, which warranted admission and neuroradiological examination.

The pathogenesis of the haematoma is briefly discussed.

## Chronisches subdurales Hämatom durch zerebrale arteriovenöse Fehlbildung

Bei einer Überprüfung von 122 intrakraniellen arteriovenösen Fehlbildungen aus den Jahren 1970–1983 entdeckten wir den äußerst seltenen Fall eines chronischen subduralen Hämatoms, das eine frontale arteriovenöse Mißbildung überlagerte. In diesem Fall war das Bild einer angenommenen primären Epilepsie durch Symptome eines erhöhten Schädelinnendrucks kompliziert, wodurch sowohl die Einweisung als auch die neuroradiologische Untersuchung erforderlich wurden. Die Pathogenese des Hämatoms wird kurz besprochen.

**Key-Words:** Cerebral arteriovenous malformation – Chronic subdural haematoma

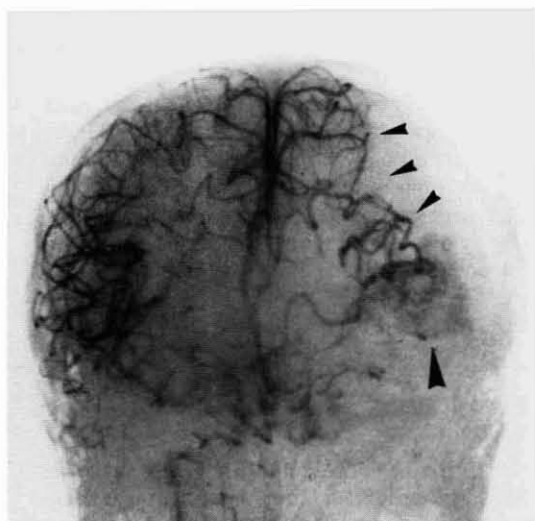
## Discussion

The occurrence of subdural haemorrhage complicating a cerebral vascular malformation is unusual. In these cases the most common source of bleeding is a ruptured berry aneurysm, particularly of the internal carotid or middle cerebral arteries (1, 2, 4, 7, 8, 13, 14, 18).

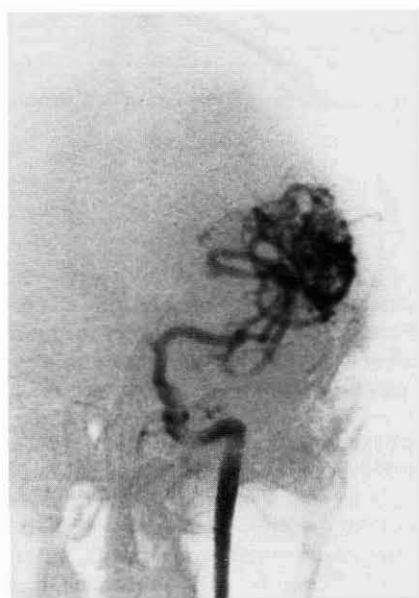Direct subdural haemorrhage from a cerebral AVM is very rare. Rengachary and Szymanski recently reported two instances of acute subdural haematoma (traumatic in one case and probably spontaneous in the other one) related to an AVM (12), and reviewed the older literature finding a few earlier cases (15, 21). To our knowledge, the only case so far of a chronic subdural haematoma complicating an AVM has been described in the German literature by Scherzer (16). In this case, also probably occurring as in our patient at the moment of a grand mal seizure, head injury resulted in some damage and blood oozing from the pathological vessels of the malformation.

Chronic accumulation of blood in the subdural space is usually venous in origin, and is generally seen in traumatic chronic haematomas from cerebral bridging veins. However, an arterial source of chronic haematoma has also been demonstrated by Byun and Patel in one of their two cases of spontaneous subdural bleeding (3), a finding which has been referred to as extremely rare (19).

In our patient the source of haemorrhage could not be identified, since the lesion had already evolved to the chronic phase with lysis of the subdural clots and healing of the ruptured surface vessel. Apart from their ultimate (i. e. arterial or venous) origin, wide consensus exists regarding the pathogenesis of spontaneous subdural haematomas: the presence of localized adhesions



**Fig. 1** Right internal carotid angiography, with cross-filling and outlining of the contralateral circulation. A left extracerebral avascular space (arrowheads) with midline shift to the right side is visible, along with "cloudy" staining of the left frontal region (arrow).



**Fig. 2** Left internal carotid angiography. Due to a steal phenomenon the whole hemispheric circulation appears to be "concentrated" in the frontal AVM. Also the left ACA is not filled.

between the arachnoid membrane and a cortical vessel at the rupture site is critical for bleeding to occur directly into the subdural rather than the subarachnoid space (3, 5, 12, 17, 19). In our case we suggest that, given the existence of a locus minoris resistentiae created by a cortical-arachnoidal fusion somewhere in the area of the AVM, even a mild head injury resulting in minor motion of the brain caused tearing of the arachnoid membrane and triggered a progressive subdural bleeding (3).

## References

- (1) Bassett, R. C., L. J. Lemmen: Subdural haematoma associated with bleeding intracranial aneurysm. *J. Neurosurg.* 9 (1952) 443-450
- (2) Boop, W. C. jr., S. N. Chou, L. A. French: Ruptured intracranial aneurysm complicated by subdural haematoma. *J. Neurosurg.* 18 (1961) 834-836
- (3) Byun, H. S., P. P. Patel: Spontaneous subdural haematoma of arterial origin: Report of two cases. *Neurosurgery* 5 (1979) 611-613
- (4) Clarke, E., J. N. Walton: Subdural haematoma complicating intracranial aneurysm and angioma. *Brain* 76 (1953) 378-404
- (5) Fein, J. M.: Comment to Byun and Patel (Ref. 3)
- (6) Guidetti, B., A. Delitala: Intracranial arteriovenous malformations. Conservative and surgical treatment. *J. Neurosurg.* 53 (1980) 149-152
- (7) Handel, S. F., F. O. L. Perpetuo, C. H. Handel: Subdural haematoma due to ruptured cerebral aneurysms: Angiographic diagnosis and potential pitfall for CT. *A.J.R.* 130 (1978) 507-509
- (8) King, J. E. J.: Haematomas: Extradural, subdural and subcortical. *Am. J. Surg.* 59 (1943) 248-271
- (9) Mingrino, S.: Supratentorial arteriovenous malformations of the brain, in Krayenbühl, H. (ed.): *Advances and technical standards in Neurosurgery*. Wien/New York, Springer (1978), Vol. 5, 93-123
- (10) Olivecrona, H., J. Ladenheim: Congenital arteriovenous aneurysms of the carotid and vertebral arterial systems. Berlin, Springer (1957)
- (11) Perret, G., H. Nishioka: Arteriovenous malformations. An analysis of 545 cases of cranio-cerebral arteriovenous malformations and fistulae reported to the Cooperative Study. *J. Neurosurg.* 25 (1966) 467-490
- (12) Rengachary, S. S., D. C. Szymanski: Subdural haematomas of arterial origin. *Neurosurgery* 8 (1981) 166-172
- (13) Ryan, E. P.: Rupture of intracranial aneurysm causing acute subdural hematoma, intratemporal hematoma, and decerebration, with survival: Case report. *Neurosurgery* 5 (1979) 698-700
- (14) Sachs, E. jr., J. L. Bernat: Recovery from acute subdural hematoma and uncus herniation due to ruptured intracranial aneurysm. *Neurosurgery* 3 (1978) 66-67
- (15) Sano, K., Y. Ueda, I. Saito: Subarachnoid haemorrhage in children. *Child's Brain* 4 (1978) 38-46
- (16) Scherzer, E.: Chronic subdural haematoma in vascular malformations of the intracranium. *W. Z. Nervenheilk.* 25 (1967) 57-67 (transl.)
- (17) Sameda, K., N. Yasui, Y. Moriwaki, Y. Kawamura, H. Matsumura: Extravasation of contrast material into subdural space from internal carotid aneurysm during angiography. Case report. *J. Neurosurg.* 42 (1975) 473-477
- (18) Strang, R. R., D. Tovi, R. Hugosson: Subdural haematomas resulting from the rupture of intracranial arterial aneurysms. *Acta Chir. Scand.* 121 (1961) 345-350
- (19) Tator, C. H.: Comment to Byun and Patel (Ref. 3)
- (20) Trumpy, J. H., P. Eldevik: Intracranial arteriovenous malformations: Conservative or surgical treatment? *Surg. Neurol.* 8 (1977) 171-175
- (21) Voris, H. C.: Subdural haematoma. *JAMA* 132 (1946) 686-692

Dr. Eugenio Pozzati  
Divisione di Neurochirurgia  
Ospedale Bellaria  
40139 Bologna/Italy