

DOES REVERSED LATERALITY REALLY EXIST IN DEXTRALS? A CASE STUDY

CARME JUNQUÉ,* IRENE LITVAN and PERE VENDRELL

Neurology Service, Sta Creu i Sant Pau Hospital, School of Medicine,
Autonomous University of Barcelona, Barcelona, Spain

(Accepted 19 August 1985)

Abstract—We report a case of a right-handed patient who, after a massive left-hemisphere infarction, had neuropsychological disturbances compatible with a right-hemisphere lesion. This has been previously called 'reversed laterality'. Two new aspects of this pattern are described: (1) the right hemisphere is as capable as the left in processing complex syntactic and higher psycholinguistic stimuli; (2) reversed laterality is not complete, ideomotor praxis is the only function that does not follow an inverted representation. The existence of different forms of cerebral organization in dextrals is discussed.

INTRODUCTION

RECENTLY TAYLOR and SOLOMON [55] reported a case of cerebral infarct in the left hemisphere which did not result in aphasia but in visuo-spatial deficits. The patient was right-handed and CT showed the presence of a lesion involving the 'language' area. This unusual anatomo-functional organization was called 'reversed laterality'. Previously a case had been reported [8] where autopsy for lung cancer also revealed destruction of Wernicke's area without any evidence of aphasia in the patient before death. An apparent absence of language representation in the left hemisphere has also been occasionally discovered during sodium amytal injection [10]. On the other hand, language representation in the right hemisphere in right-handed subjects has been observed on several occasions since BRAMWELL [9] introduced the term 'crossed aphasia' in 1899. Unfortunately, most studies of crossed aphasia focus only on the unique aspects of language impairment in these patients without assessing all neuropsychological functions [11, 35]. Crossed aphasia is not the equivalent to reversed laterality since some cases of crossed aphasia also present with visuo-spatial deficits [12, 54]. Thus, there is evidence of two forms of atypical cerebral organization in right-handed adults, one of which is compatible with reversed laterality. This type of representation was theorized in 1966 by KREINDLER *et al.* [38].

In this paper we report the case of a right-handed patient with a left fronto-temporo-parietal lesion whose characteristics are: absence of aphasia and presence of a neglect syndrome, visuo-spatial and visuo-constructive deficits, amusia, inattentiveness and apathy. All of these symptoms better correspond to a right-hemisphere lesion.

In view of the rarity of this clinical picture of reversed laterality, we believe that it would be of interest to describe in detail the normal and impaired neuropsychological functions of this patient. In addition, the notable intellectual level of our patient has permitted us to

*Address correspondence to: Dr Junqué, Secció de Neuropsicologia, Servei de Neurologia, Hospital de la Sta. Creu i Sant Pau, Avgda. St. A. M^a Claret 167, 08025 Barcelona, Spain.

demonstrate the intactness of his psycholinguistic abilities, apparent even on complicated tasks, in contrast to the case reported by TAYLOR and SOLOMON [55].

CASE REPORT

Our patient, J.R., is a 62-yr-old male bilingual. He learned Catalan* as a first language, and was taught Spanish at about 5 yr of age. Since then he has been speaking both languages with similar use and efficiency. J.R. is college educated, a lawyer by profession without family history of sinistrality (investigated by asking the patient about the handedness of his relatives) and who is 100% right-handed according to the Edinburgh Handedness Inventory [44]. He had 4 yr of musical education. J.R. had a myocardial infarction when he was 43 yr old, and he had a history of chronic coronary insufficiency. Three months before being seen by the Neurology Service he presented with an auriculo-ventricular block which led to the implantation of a pacemaker. In January 1984 he was admitted to our hospital with the following reported clinical symptoms: acute right hemiplegia, left oculocephalic deviation and low level of consciousness. A neurological examination carried out the day after he was admitted showed him to be conscious; oriented to time, space and person; dysarthric, with a tendency to oculocephalic deviation to the left; right hemispatial neglect; hemiasomatognosia; right homonymous hemianopia; right facio-brachio-crural hemihypoesthesia; and hemiplegia with right hyperreflexia and Babinski sign. A general medical examination did not reveal any situs inversus. An initial CT scan revealed a massive left fronto-temporo-parietal infarct.

The clinical neuropsychological examination carried out two days post onset showed fluent language with severe dysprosodia and mild dysarthria. J.R.'s comprehension, naming, pointing and repetition abilities—scored according to the bilingual aphasia test of our hospital—were normal. No manifestations of aphasia was seen in either of his two languages. In writing, an apraxic agraphia with macrographia was observed. In reading, the patient demonstrated right spatial alexia. Right spatial neglect was also seen on Albert's test [1] and in another test requiring bisection of lines [32]. The reproduction of rhythm assessed by tapping was impaired and when asked to sing J.R. recited words without any accompanying melody. The general attitude of the patient was one of indifference characterized by apathy and inattentiveness.

In order to identify more accurately the topology of the lesion a second CT scan of higher resolution on a fourth-generation scanner (Somatom DR2, matrix 256 × 256) was done. Nine slides were obtained routinely at an angle of 20° to the centro-meatal line. Results of CT show a large area of decreased density (see Fig. 1) consistent with an acute infarction, involving the left parietal lobe, two thirds of the anterior left temporal lobe, including the basal ganglia and the posterior third of the left frontal lobe. There was no mass lesion effect. As is shown, Broca's and Wernicke's areas of language are affected.

Cerebral hemispheric asymmetries were measured from the CT scan according to the methodology of PIENIAZD and NAESER [45]. In our patient, the CT pattern of asymmetry was typical of right-handed subjects with left-hemisphere language dominance: the left occipital lobe was wider than the right occipital lobe and the right frontal lobe was wider than the left one. In most of the crossed aphasia cases measured by CT scan this asymmetry has also been found [35, 54].

NEUROPSYCHOLOGICAL ASSESSMENT

A more comprehensive neuropsychological assessment was carried out two months post-onset in order to study this atypical case in detail.

Language

The Boston Diagnostic Aphasia Examination (BDAE) [29] was given and the results may be seen in Figs 2 and 3. The rating scale profile of language functions shows normal scores with the exception of melodic line and articulation agility. In the subtest summary profile, maximum scores were observed on all subtests with the exception of average articulation and articular agility skills and those of writing and singing which are clearly deficient. The Boston Naming Test [30] was performed within normal limits (raw score = 55). Verbal comprehension examined by the shortened version of the Token Test [21] was also normal (raw score = 35).

The Sentence Anagram Test [13] was completed flawlessly. The patient also solved

*Catalan is a Romance language (such as Spanish, French, Italian, etc.) spoken principally in the east of Spain.

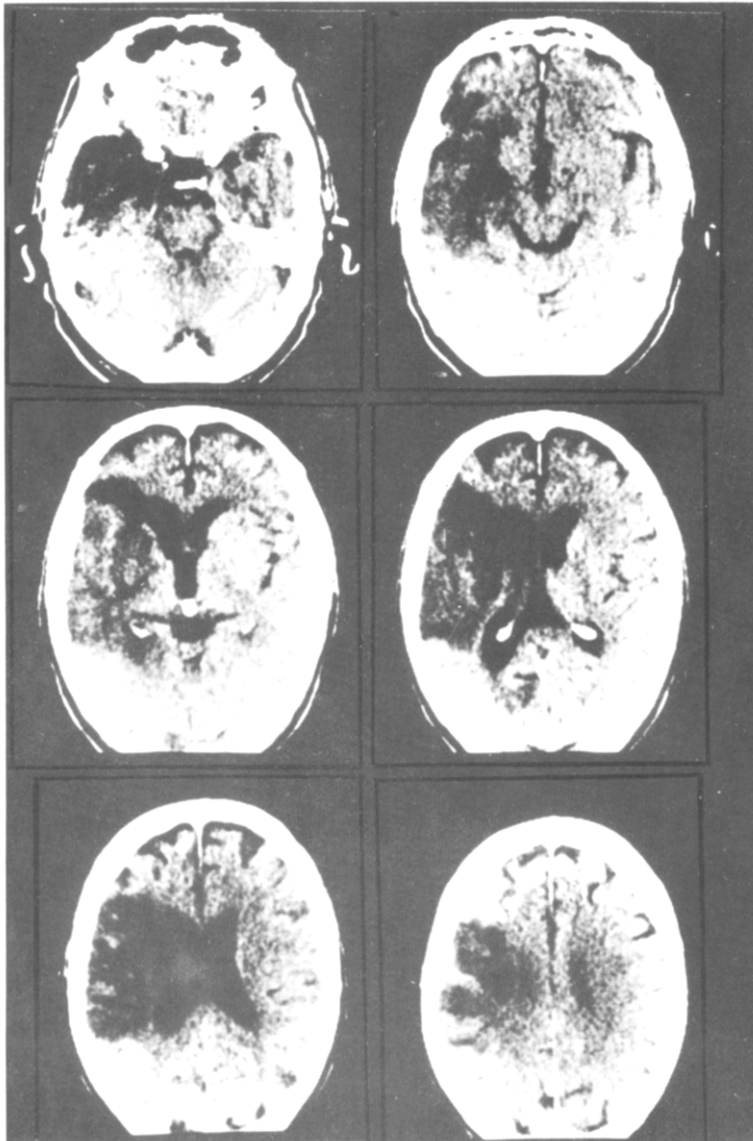


FIG. 1. CT scan shows a massive acute infarction involving the left parietal lobe, two thirds of the anterior temporal lobe, and the posterior third of the left frontal lobe.

RATING SCALE PROFILE OF SPEECH CHARACTERISTICS

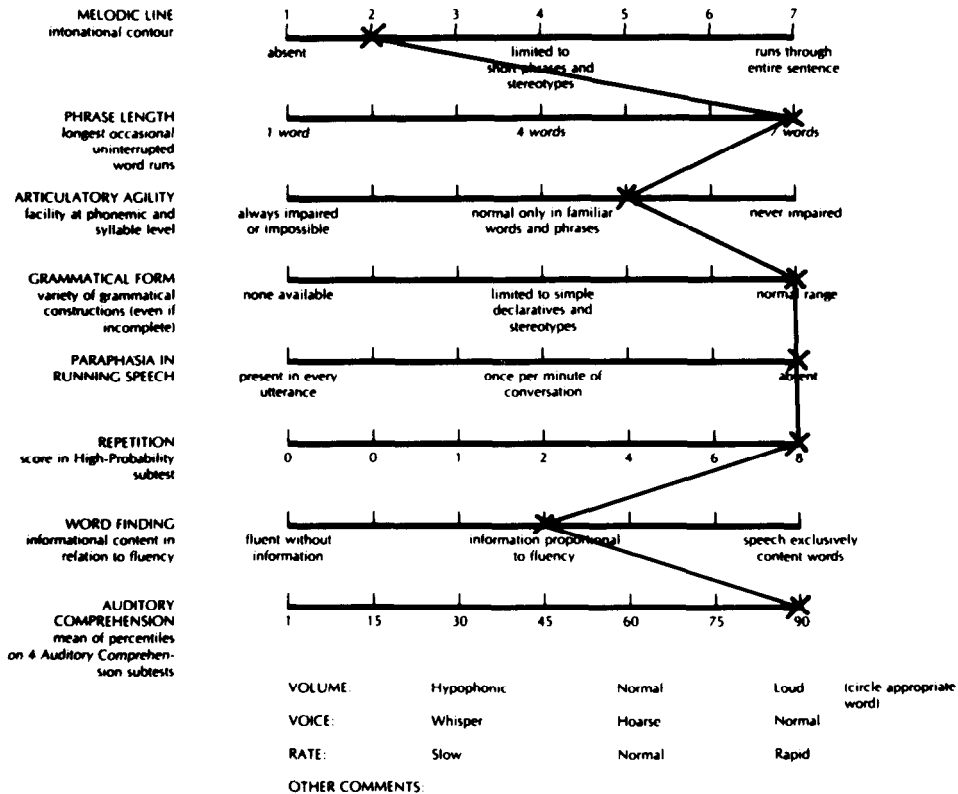


FIG. 2. BDAE rating scale profile of speech characteristics, which is not typical of any aphasic disturbance. The only remarkable findings are the dysarthria and the lack of melody.

without any difficulty all the items of the Active–Passive Test [19]. J.R.’s production on the Thurstone test of verbal fluency [56] by oral modality was 58 words. Reading and oral spelling of isolated letters, syllables, words, and texts are normal. Reading comprehension of a complicated test was above average. Writing both spontaneously (see Fig. 4) and by copying was severely affected. His writing improved slightly when copying. In addition, he was able to use the typewriter effectively for linguistic expression. This apractic agraphia was accompanied in our patient by a marked constructional apraxia apparent in his drawings.

Praxis

Praxis was initially examined using the items contained in the BDAE supplemental subtest [29]. Ideatory praxis was normal but ideomotor praxis was impaired. For example: J.R. could fold a letter and put it inside an envelope without any difficulty, but in contrast he put three fingers on his lips to indicate silence, waved his arms vigorously to say goodbye. To supplement this examination another exhaustive procedure [40] was used which consists in




FIG. 4. Sample of the patient's apractic agraphia. The text was the transcription of the BDAE sentence "the quick brown fox...". The correct Spanish translation of this sentence is: "El rápido zorro marrón salta sobre el perro perezoso".

Table 1. Results of ideomotor praxis test assessed according to the LEHMKUHL *et al.* [4] procedure

	Oral (0-10)	Arms		Legs	
		Symbolic (0-10)	Meaningless (0-10)	Symbolic (0-7)	Meaningless (0-8)
Verbal	6(60%)	3(30%)	10(100%)	3(43%)	8(100%)
Imitatory	6(60%)	3(30%)	10(100%)	6(86%)	8(100%)

the carrying out of verbal instructions and imitation of 100 meaningful and nonsensical movements with the superior and inferior limbs. Since the patient was hemiplegic, bimanual requirements were eliminated. The results are presented in Table 1. Errors in symbolic praxis consisted of inadequate gestures. Surprisingly we found that meaningless gestures were performed accurately (100%) and only symbolic ones were clearly impaired, contrary to what is classically described [17].

Comprehension of praxis was also investigated [23] following the same protocol [40]. In this case, the examiner made the gestures and asked the patient to tell him what he was doing. All gestures were interpreted correctly. In summary the patient only had a clear expressive ideomotor apraxia for symbolic gestures.

Visuoperceptive and visuoconstructive functions

The Purdue Pegboard Test [58] was administered to evaluate dexterity of the left hand. The average score of three trials fell below the normal range for the non-dominant left hand and was similar to the average for a heterogeneous brain-damaged population [41].

Constructional praxis was assessed by the Benton Tridimensional Praxis Test [6]. The total score using the standard notation systems was 15 for the photographic presentation and 22 for the model block. Both scores fell out of the range of the control group and were indicative of a markedly impaired performance. All kinds of errors were found: omissions, additions, substitutions, angular deflection and displacements. The slowness of the patient's

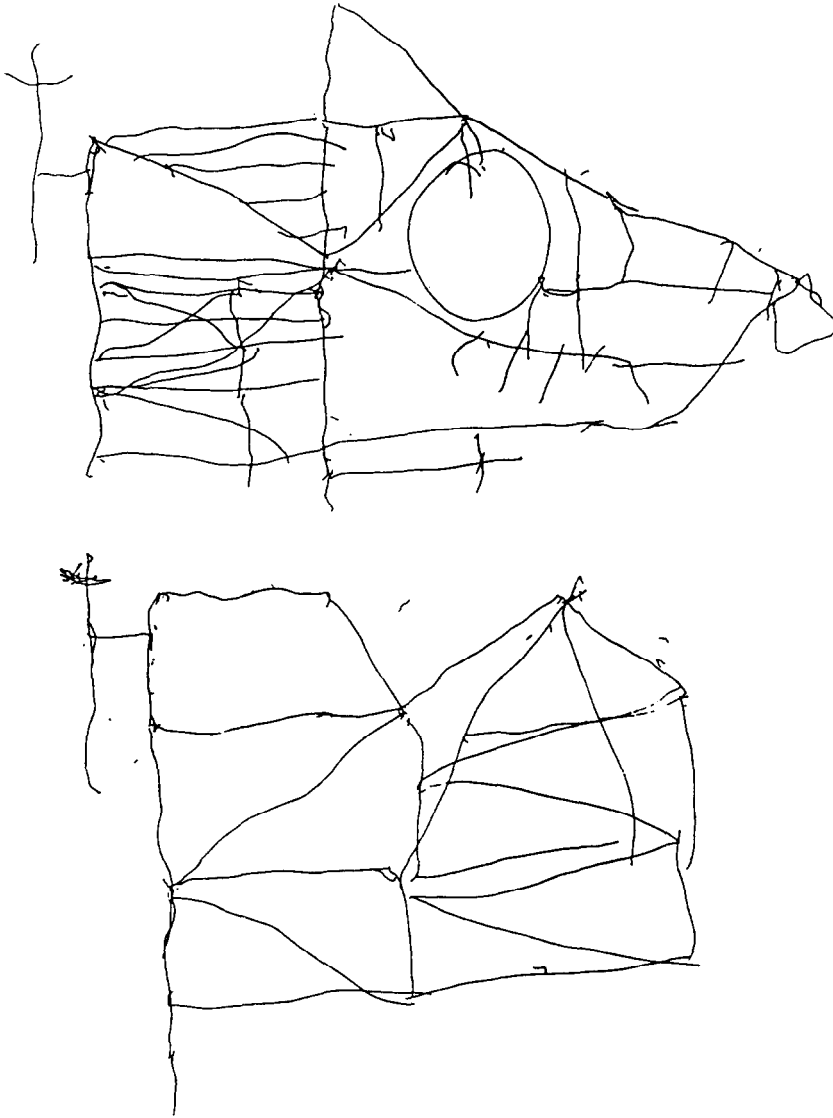


FIG. 5. Patient's copy and visual memory reproduction (below) of a modified Rey-Osterrieth complex figure.

construction was also notable: 885 sec for the photographic model and 406 sec for the three-dimensional one.

In copying Rey's complex figure [49] J.R. achieved a score of 18.5 (score 29 = percentile 10). Fig. 5 is an illustration of J.R.'s copying that indicates the severity of his disorganization. On the Bender test [5] he also achieved a deficient performance.

On the WAIS Block Design subtest [60] J.R. achieved a scale score of 9, which although normal, is clearly below the expected value given his verbal IQ (VIQ see below). The Object Assembly subtest [60] revealed a markedly deficient performance (scale score = 4).

Gnosis

The patient performed normally on a finger gnosis examination and on left-right orientation testing following BDAE methodology [29]. Proprioception deficits precluded visuo-tactile exploration of the right hand. The results of the Poppelreuter test [47] and a test of colour recognition were normal. The examination of auditory gnosis was carried out by identification of 10 common sounds (laughter, crying, bells, engine, running water, drilling, birds singing, alarm, clock ringing, ticking of clock), all of which the patient identified correctly.

Musical ability

The BDAE Rhythm subtest [29] revealed a slight deficit (score = 1). On the Stamback test [52] J.R. only reproduced 14 of 21 rhythms (a performance corresponding to an age of 7 yr). His identification of well-known rhythms was normal, but J.R. was unable to reproduce them.

Musical knowledge and ability was examined by an experimental test of amusia which consisted of 24 pieces of famous melodies with varying degrees of complexity. The patient first had to identify the tune and give its title and then had to hum them in unison. The identification portion of the task was performed above average compared to a non-matched control group, but reproduction in unison was severely impaired. His melodic production was inadequate for all the melodies given. When he attempted to sing famous songs, J.R. could reproduce the words but was incapable of reproducing melodies.

Intelligence

On the Wechsler Adult Intelligence Scale (WAIS) [60], the patient achieved a VIQ of 137 and a performance IQ (PIQ) of 82. Table 2 lists the scale scores for each of the subtest. These

Table 2. Standard Scaled Scores obtained by J.R. on the WAIS

Information	17	Digit Symbol	0
Comprehension	19	Picture Completion	12
Arithmetic	13	Block Design	9
Similarities	19	Picture Arrangement	8
Digit Span	14	Object Assembly	4
Vocabulary	14		
Verbal IQ = 137		Performance IQ = 82	
Full Scale IQ = 116			

results indicate that the patient has superior verbal intelligence. In contrast, the patient's PIQ is below average and significantly inferior to his VIQ. The Digit Symbol and Object Assembly subtests were most affected with the remaining performance scale subtest scores falling in the normal range, but relatively impaired when contrasting to his verbal performance. This dramatic finding cannot be solely explained by his being functionally limited to the use of his left hand.

On the Raven's Progressive Matrices Test [48] J.R. attained a percentile score of 66 which corresponds to an IQ of 104 [60]. The different results obtained by these two intelligence tests may be explained by J.R.'s visuo-spatial deficit [3] or his constructional apraxia [4]. Neglect may not explain the errors [14] since the frequency of right and left choices on the Raven's test are similar.

Memory

The patient's memory quotient on the Wechsler Memory Scale (WMS) [59] was 104 which is lower than expected given his WAIS VIQ score. All subtests were performed within normal limits. Verbal recall on the Rey's Auditory Verbal Learning Test [50] was below the 10th percentile. On the recognition version of the Benton Visual Retention Test [7] J.R. achieved a score of 9 (very impaired) and as is shown in Fig. 4., his performance on Rey's Visual Memory Test [49] is also impaired..

We administered a test of recognition of faces using 10 photos of famous international personalities. J.R. correctly named seven out of 10, but given the written name, he recognized 100% of the faces successfully.

Personality and emotional behaviour

J.R. showed an apathetic and apparently hostile attitude towards his family and the medical staff. He also showed a tendency to fall asleep when he was not externally stimulated. J.R. often looked like he was confused but he had a good performance on tests of attention (WAIS Digit Span [60] and Strub and Black's Auditory Attention Test [7]) and he was well orientated to person, space and time. Thus, J.R.'s behavior was more characteristic of the pseudoconfusion which typically accompanies the neglect syndrome [32, 51].

The patient did not show any spontaneous emotion with gesture or in speech. As a result, the examiners felt hesitant in interpreting his emotional state. In addition, the examiners couldn't tell if the patient liked or disliked the tasks he was required to do. We can not conclude from these observations that the patient ignored his shortcomings or did not know the precision or imprecision of his responses. However, in spite of J.R.'s motor, sensory and cognitive deficits which make him unable to rejoin the labor force, he never had a 'catastrophic reaction' as has been described in left lesioned patients [25]. It is significant that in spite of his postmorbid superior intellectual level, J.R.'s degree of apathy is so serious that his family shows concern for his 'mental balance'.

These disturbances of emotional behaviour were not reflected in the Minnesota Multiphasic Personality Inventory (MMPI) profile [31] as we can see in Fig. 6. The MMPI was administered twice because the patient initially classified too many statements in the "don't know" category indicating indecisiveness. But even when the MMPI was readministered and the patient strongly encouraged to classify all answers as true or false, the obtained profile was remarkably similar to his earlier one.

Complementary instrumental examination

Since the patient was bilingual we have examined dichotic listening performance in both languages. The results revealed total right-ear extinction for both languages (the Marshall index score [42] was -100 for two languages). These results were expected considering J.R.'s left temporal lobe damage [16]. The performance of the left ear was average and similar in both languages.

Reaction times to lateralized visual stimuli was measured by a microcomputer (Apple II+). The results showed a slowed response time to stimuli in both visual fields as is commonly seen in patients with right-hemisphere lesions [27]. The patient neglected to respond to a small number of stimuli presented in his right visual hemifield which was compatible with his right homonymous hemianopia.

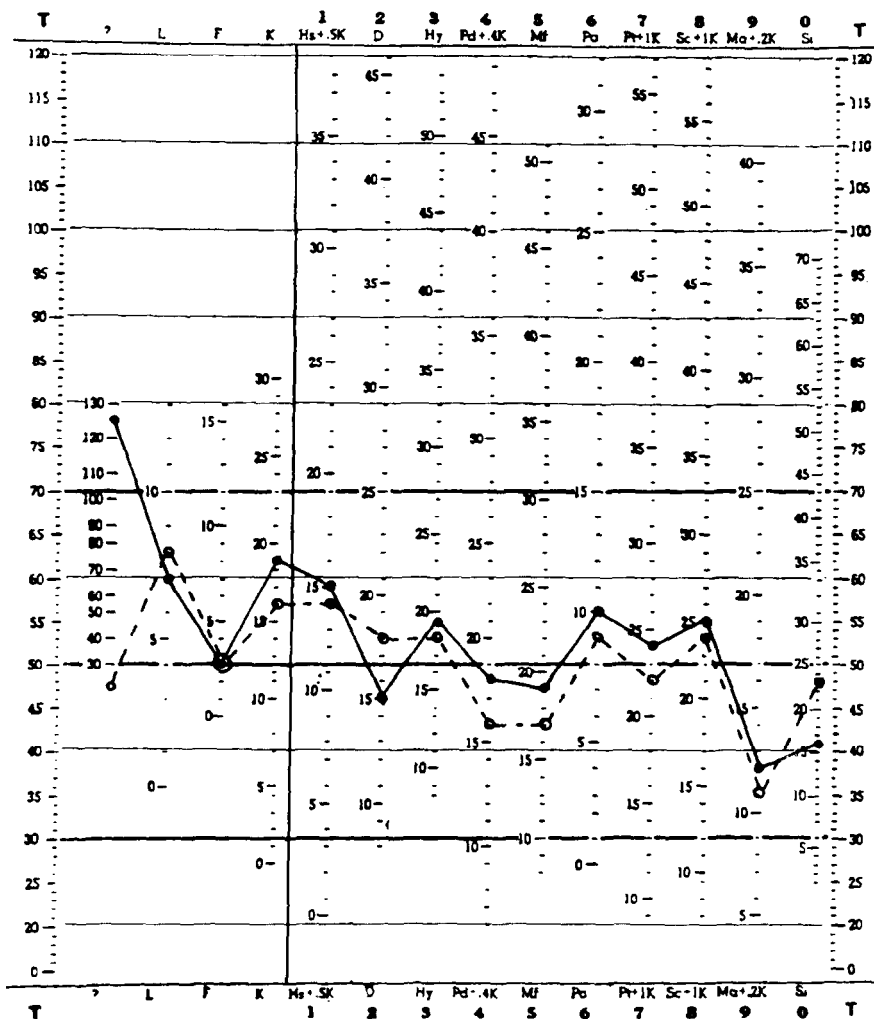


FIG. 6. MMPI profile. The continuous line reflects the results of the first administration while the discontinuous line represents the results of the readministration.

DISCUSSION

We had the opportunity to examine neuropsychologically a right-handed patient with a massive lesion of the left hemisphere. Surprisingly the patient's performance was more compatible with a lesion in the right hemisphere. His symptoms included: neglect, visuo-perceptive and visuo-constructive deficits, motor amusia and disturbances in the voluntary expression of emotion. In contrast, J.R. never showed any aphasic manifestation. This unusual profile of results suggests that our patient has what might be termed 'reversed laterality', previously described by TAYLOR and SOLOMON [55].

We want to stress the absence of any neurolinguistic disorder despite a massive infarct in the left hemisphere. Not only was language skill intact in J.R. but he showed superior psycholinguistic abilities. It is very unusual to obtain a VIQ of 137 after an extensive left-

hemisphere lesion [41]. Moreover, unlike Taylor and Solomon's previously described case (H.B.), J.R. did not have any difficulty on tasks requiring complex syntactic skills. H.B. was reported as having poor comprehension of passive-negative sentences. This difficulty was interpreted by TAYLOR and SOLOMON [55] as a limitation of the right hemisphere solving complex grammatical structures, similar to that seen in cases of compensatory right-hemisphere language mediation (hemispherectomized patients) [20]. We think that this comparison is inadequate because in contrast to left hemispherectomized patients whose right hemisphere *adopts* linguistic functions, in 'reversed laterality', the representation of language in the right hemisphere probably reflects a *primary* functional organization. We think that an alternative for H.B.'s deficiencies in complex language comprehension may be his low VIQ. We have demonstrated that our patient J.R., who has a superior VIQ, perfectly solved complex syntactic tasks. Our results imply that the 'reversed laterality' case may process linguistic stimuli as well as a patient with an intact and typically lateralized left hemisphere, as has also been suggested in crossed aphasia cases [54, 57].

Another critical finding is the persistent impairment of functions which are typically lateralized in the right hemisphere: constructional tasks such as the execution of block construction, design or copy of complex figures [24, 61], non-verbal memory [46], melody [43] and the 'indifference reaction' [25]. These deficits are both severe and persistent.

The severity of these symptoms corresponds to the lesion extent observed in J.R.'s CT scan, but not to its side.

The ideomotor apraxia manifested by J.R. is a conflicting result for a 'reversed laterality' model. In right-handed patients, almost all cases of apraxia are from left-hemisphere lesions [26, 28] and commonly are associated with aphasia. The lesion that produces either or both appears to overlap extensively [36]. In addition to this intrahemispheric dissociation, there is an interhemispheric one. In this sense, many previously reported cases of crossed aphasia in right-handed individuals show no ideomotor apraxia [11, 39, 54]. Further evidence comes from a left-handed patient with a right-hemisphere lesion who did not develop aphasia, but did show ideomotor apraxia (33). In this patient it appeared that dominance for language lateralized in the left hemisphere, whereas ideomotor praxis was lateralized to the right. Thus, language and ideomotor praxis are not necessarily linked in a given individual and may be lateralized to opposite hemispheres. Conceivably, apraxia corresponds more closely with a hemisphere lesion opposite to the dominant hand than a lesion on the side of language dominance. Our case supports this interhemispheric dissociation. Despite the lesion size which involved classical language and praxic areas, the patient suffered ideomotor apraxia without aphasia. It is difficult to explain why the apraxia involves only symbolic gestures; recent exhaustive studies show similar impairment on meaningful and meaningless movements [22]. Unfortunately, the praxic performance of TAYLOR and SOLOMON's [55] patient has not been reported and we can not compare their findings to ours.

'Reversed laterality' implies that all the specialized functions of the left hemisphere are processed by the right hemisphere and vice versa. This requirement has been met for almost all functions in both TAYLOR and SOLOMON's [55] and our case, and also in the cases of crossed aphasia in which right-hemisphere lesions were followed by aphasia without visuo-spatial disturbances.

We suggest that 'reversed laterality' is never complete. In effect, in right-handed subjects not all functions would follow a reversed pattern. Ideomotor praxis should remain lateralized in the left hemisphere, since handedness is a manifestation of contralateral cerebral dominance for that function.

In a strict sense, the term 'reversed laterality' would only be applicable to some left-

handers. Since in those cases, language and praxis are lateralized to right hemisphere and visuospatial functions are left-hemisphere lateralized. One patient with these characteristics has been recently reported [18]. By contrast, a complete inversion of neuropsychological functions (including praxis) has never been reported in dextrals.

In summary, we suggest that there are three different possible forms of cerebral organization in right-handed adults. The typical (expected in almost all subjects) left-hemisphere representation contains those cognitive processes utilized for linguistic communication whereas the right-hemisphere contains those cognitive processes utilized for visuo-spatial functions. More atypical forms would posit inversed representation (as ours and some crossed aphasias) or overlapping representation in the same hemisphere (in other type of crossed aphasias). More exhaustive neuropsychological examinations of unusual cases are needed for definitive conclusions.

Acknowledgements—We thank Drs J. Ruscalleda and A. Rovira for the helpful collaboration in the CT scan study and Dr J. Grafman for his valuable suggestions on the manuscript. In addition the authors acknowledge M. Batalla for the drawings of the Active-Passive Test, and A. Mones for typing the manuscript.

REFERENCES

1. ALBERT, M. C. A simple test of visual neglect. *Neurology*, **23**, 658–664, 1973.
2. ANGELERGUES, R., HÉCAEN, H., DJINDJIAN, R. AND JARRIE-HAZAN, N. Un cas d'aphasie croisée. *Revue neurol.* **107**, 543–545, 1962.
3. BASSO, A., DERENZI, E., FAGLIONI, P., SCOTTI, G. and SPINNLER, H. Neuropsychological evidence for the existence of cerebral areas critical to the performance of intelligence tasks. *Brain* **96**, 715–728, 1973.
4. BASSO, A., CAPITANI, E., LUZZATTI, C. and SPINNLER, H. Intelligence and left hemisphere. The role of aphasia, apraxia, and size of lesion. *Brain* **104**, 721–734, 1981.
5. BENDER, L. *Visual Motor Gestalt Test*. American Orthopsychiatric Corporation, New York, 1955.
6. BENTON, A. L. *Test of Three-Dimensional Constructional Praxis*. University of Iowa Press, Iowa City, 1973.
7. BENTON, A. L. *The Revised Visual Retention Test*. Psychological Corporation, New York, 1974.
8. BOLLER, F. Destruction of Wernicke's area without language disturbance. A fresh look at crossed aphasia. *Neuropsychologia* **11**, 243–246, 1973.
9. BRAMWELL, B. On "crossed aphasia" and the factors which go to determine whether the "leading" or "driving" speech-centres shall be located in the left or in the right hemisphere of the brain, with notes of a case of "crossed" aphasia (aphasia with right side hemiplegia) in a left-handed man. *Lancet* **i**, 1473–1479, 1899.
10. BRANCH, C., MILNER, B. and RASMUSSEN, T. Intracarotid sodium amytal for the lateralization of cerebral speech dominance. *J. Neurosurg.* **21**, 339–405, 1964.
11. BROWN, J. W. and WILSON, F. Crossed aphasia in a dextral. A case report. *Neurology*, **23**, 907–911, 1973.
12. CARR, M. S., JACOBSON, T. and BOLLER, F. Crossed aphasia: analysis of four cases. *Brain Lang.* **14**, 190–202, 1981.
13. CAVALLI, M., DERENZI, E., FAGLIONI, P. and VITALE, A. Impairment of right brain-damaged patients on a linguistic cognitive task. *Cortex* **17**, 545–556, 1981.
14. COSTA, L. D., VAUGHAN, H. G., HORWITZ, M. and RITTER, W. Patterns of behavioural deficit associated with visual spatial neglect. *Cortex* **5**, 243–263, 1969.
15. DAMASIO, A. R. and DAMASIO, H. Musical faculty and cerebral dominance. In *Music and the Brain*, M. CRITCHLEY and R. A. HENSON (Editors), pp. 141–155. Heinemann Medical Books, London, 1977.
16. DAMASIO, H. and DAMASIO, A. R. Dichotic listening patterns on conduction aphasia. *Brain Lang.* **10**, 281–286, 1980.
17. DE AJURIAGUERRA, J., HÉCAEN, H. and ANGELERGUES, R. Les apraxies. Variétés cliniques et latéralisation lésionnelle. *Revue neurol.* **102**, 566–594, 1960.
18. DELIS, D. C. and KNIGHT, R. T. Reversed hemispheric organization in a left hander. *Neuropsychologia*, **21**, 13–24, 1983.
19. DENNIS, M. and WHITAKER, H. A. Language acquisition following hemidecortication: linguistic superiority of the left over the right hemisphere. *Brain Lang.* **3**, 404–433, 1976.
20. DENNIS, M. and KOHN, B. Comprehension of syntax in infantile hemiplegics after cerebral hemidecortication: left hemisphere superiority. *Brain Lang.* **3**, 404–433, 1976.
21. DE RENZI, E. and FAGLIONI, P. Normative data and screening power of a shortened version of the Token Test. *Cortex* **14**, 41–49, 1978.
22. DE RENZI, E., MOTTI, F. and NICHELLI, P. Imitating gestures: a quantitative approach to ideomotor apraxia. *Archs. Neurol.* **3**, 6–10, 1980.

23. FERRO, J. M., SANTOS, M. E., CASTRO-CALDAS, A. and MARIANO, G. Gesture recognition in aphasia. *J. clin. Neuropsychol.* **2**, 277-292, 1980.
24. FRIED, I., MATEER, C., OJEMANN, G., WOHNS, R. and FEDIO, P. Organization of visuospatial functions in human cortex. Evidence from electrical stimulation. *Brain* **105**, 349-371, 1982.
25. GAINOTTI, G. Emotional behavior and hemispheric side of lesion. *Cortex* **8**, 41-55, 1972.
26. GESCHWIND, N. Disconnexion syndromes in animals and man. *Brain* **88**, 237-294; 585-644, 1965.
27. GIANUTSOS, R. and KLITZNER, C. *Handbook of Computer Programs for Cognitive Rehabilitation*. Life Science Association, New York, 1981.
28. GOODGLASS, H. and KAPLAN, E. Disturbance of gesture and pantomime in aphasia. *Brain* **86**, 703-720, 1963.
29. GOODGLASS, H. and KAPLAN, E. *The Assessment of Aphasia and Related Disorders*. Lea & Febiger, Philadelphia, 1983.
30. GOODGLASS, H. and KAPLAN, E. *The Boston Naming Test*. Lea & Febiger, Philadelphia, 1983.
31. HATHAWAY, S. R. and MCKINLEY, J. C. *The Minnesota Multiphasic Personality Inventory*. Psychological Corporation, New York, 1951.
32. HEILMAN, K. M. Neglect and Related Disorders. In *Clinical Neuropsychology*, K. M. HEILMAN and E. VALENSTEIN (Editors), pp 275-276; 294-296. Oxford University Press, New York, 1979.
33. HEILMAN, K. M., COYLE, J. M., GONYEA, E. F. and GESCHWIND, N. Apraxia and agraphia in a left hander. *Brain* **96**, 21-28, 1973.
34. HENDERSON, V. W., NAESER, M. A. and CHUI, H. C. Cerebral asymmetries evaluated by computed tomography in crossed aphasia. *Neurology* **33**, 104, 1983.
35. JOANETTE, Y., PUEL, M., NESPOULOUS, J. L., RASCOL, A. and ROCH LECOURE, A. Aphasie croisée chez les droitiers. Revue de la littérature. *Revue neurol.* **138**, 575-586, 1982.
36. KERTESZ, A., FERRO, J. M. and SHEWAN, C. M. Apraxia and aphasia: the functional anatomical basis for their dissociation. *Neurology* **34**, 40-47, 1984.
37. KERTESZ, A. and FERRO, J. M. Lesion size and localization in ideomotor apraxia. *Brain* **107**, 921-933, 1984.
38. KREINDLER, A., FRADIS, A. and SEVASTOPOL, N. La répartition des dominances hémisphériques, *Neuropsychologia*, **4**, 143-149, 1966.
39. LARRABEE, G. J., KANE, R. L. and ROGERS, J. A. Neuropsychological analysis of a case of crossed aphasia: implications for reversed laterality. *J. clin. Neuropsychol.* **4**, 131-142, 1982.
40. LEHMKUHL, G., POECK, K. and WILLMES, K. Ideomotor apraxia and aphasia. An examination of types and manifestations of apraxic symptoms. *Neuropsychologia* **21**, 199-212, 1983.
41. LEZAK, M. D. *Neuropsychological Assessment*. Oxford University Press, New York, 1983.
42. MARSHALL, J. C., CAPLAN, D. and HOLMES, J. M. The measure of laterality. *Neuropsychologia* **13**, 315-322, 1975.
43. MILNER, B. Visual recognition and recall after right temporal lobe excision in man. *Neuropsychologia* **6**, 191-209, 1968.
44. OLDFIELD, R. C. The assessment and analysis of handedness: the Edinburgh Inventory. *Neuropsychologia* **9**, 97-113, 1971.
45. PIENIADZ, J. M. and NAESER, M. A. Computed tomographic scan cerebral asymmetries and morphologic brain asymmetries. *Archs. Neurol.* **4**, 403-409, 1984.
46. PIERCY, M., HÉCAEN, H. and DE AJURIAGUERRA, J. Constructional apraxia associated with lateral cerebral lesions. Left and right sided cases compared. *Brain* **83**, 225-242, 1960.
47. POPPELREUTER, W. *Die Psychischen Schädelverletzungen Durch Kopfschuss im Kriege 1914-1916*. Verlag Von Leopold Voss, Leipzig, 1917.
48. RAVEN, J. C. *Guide to use the Standard Progressive Matrices*. A. K. Lewis, London, 1960.
49. REY, A. *Test de Copie et de Reproduction de Mémoire de Figures Géométriques Complexes*. Les éditions du Centre de Psychologie Appliquée, Paris, 1959.
50. REY, A. *L'examen Clinique en Psychologie*. Presses Universitaires de France, Paris, 1964.
51. SCHIDLIFY, J. W. and MESSING, R. D. Agitated confusional states in patients with right hemisphere infarctions. *Stroke* **15**, 883-885, 1984.
52. STAMBACK, M. Tres pruebas de ritmo. In *Manual para el Examen Psicológico del Niño*, R. ZAZZO (Editor), pp. 262-279. Fundamentos, Madrid, 1976.
53. STRUB, R. L. and BLACK, F. W. *The Mental Status Examination in Neurology*. F. A. Davis, Philadelphia, 1977.
54. SWEET, E. W. S., PANIS, W. and LEVINE, D. N. Crossed Wernicke's aphasia. *Neurology* **34**, 475-479, 1984.
55. TAYLOR, H. G. and SOLOMON, J. R. Reversed laterality: a case study. *J. clin. Neuropsychol.* **1**, 311-322, 1979.
56. THURSTONE, L. L. and THURSTONE, T. G. *Primary Mental Abilities*. Science Research Associates, Chicago, 1962.
57. TROJANOWSKI, J. Q., GREEN, R. C. and LEVINE, D. N. Crossed aphasia in a dextral. A clinico-pathological study. *Neurology* **30**, 709-713, 1980.
58. VAUGHN, H. G. and COSTA, L. D. Performance of patients with lateralized cerebral lesions II. Sensory and motor tests. *J. nerv. ment. dis.* **134**, 237-243, 1962.
59. WECHSLER, D. A. A standardized memory scale for clinical use. *J. psychol.* **19**, 87-95, 1945.
60. WECHSLER, D. A. *Wechsler Adult Intelligence Scale Manual*. Psychological Corporation, New York, 1955.
61. WHITTY, C. W. and NEWCOMBE, F. Disabilities associated with lesions in the posterior parietal region of the non-dominant hemisphere. *Neuropsychologia* **3**, 175-185, 1965.