

Dural Sarcoidosis Presenting With Transient Neurologic Symptoms

Kapil D. Sethi, MD, MRCP; Taher El Gammal, MD; Bipin R. Patel, MD; Thomas R. Swift, MD

• Despite the propensity of sarcoid granulomas to be clustered around blood vessels, transient ischemic attacks and strokes are rare. A 43-year-old man had recurrent transient dysarthria and right hemiparesis; a biopsy specimen showed neurosarcoidosis. There was complete resolution of both symptomatology and the subdural sarcoid mass lesion with the administration of corticosteroid therapy. (*Arch Neurol* 1986;43:595-597)

Neurologic involvement occurs in 2% to 16%¹ of the cases of sarcoidosis, either from space-occupying or infiltrating granulomas or from granulomas infiltrating the blood vessels.^{2,5} Pathologically, infarctions occur in the territory of involved vessels, but the clinical occurrence of transient ischemic attacks (TIAs) and strokes is rare.⁶ We describe a patient who had recurrent focal neurologic deficits resembling classic TIAs due to neurosarcoidosis.

REPORT OF A CASE

A 43-year-old man had been examined elsewhere three years earlier for urinary incontinence and weakness and stiffness of the legs. A total axis myelogram was normal then. Cerebrospinal fluid contained oligoclonal bands and an elevated protein

level. He was believed to have a demyelinating disease and was treated with a brief course of corticosteroids (dosage and duration unknown) without any response. Two years later, he began having recurrent episodes of weakness and numbness of the right side of the face and body usually lasting 30 to 60 minutes. The maximum duration recorded was 12 hours. These stereotyped attacks consisted of numbness of the arm or leg spreading within seconds to involve the entire right side of the body along with muscle weakness and slurred speech. This was often followed by throbbing bifrontal headache without nausea or vomiting. There were no visual disturbances preceding or accompanying these episodes.

Examination during one of the transient episodes revealed the patient to be alert. He had fluent paraphasic speech and difficulty with naming, repetition, and comprehension. There was weakness of the lower portion of the right side of the face and right arm with brisk reflexes. Legs were spastic with bilateral Babinski's signs. Findings from a sensory examination were normal.

A general physical examination showed no abnormalities. At the time of his initial admission to our hospital, a computed tomographic (CT) head scan (with and without contrast enhancement), cerebral angiogram, electroencephalogram (EEG), echocardiogram, and Holter electrocardiographic monitoring were normal. Formal ophthalmologic examination revealed no abnormality. Aspirin therapy produced no improvement in the patient's condition. He was readmitted to the hospital briefly eight months later and a CT scan and echocardiogram were again normal.

A CT head scan one year after onset of symptoms showed an enhancing lesion in the extracerebral space over the left parietal region (Fig 1). Retrospective analysis

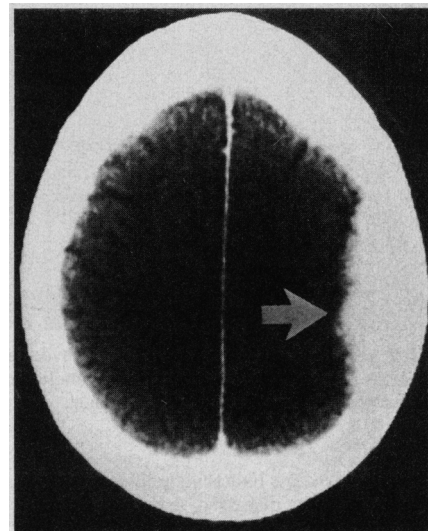


Fig 1.—Computed tomographic scan with contrast enhancement showing enhancing lesion (arrow) over left parietal region.

of the scan done four months earlier revealed that the same lesion was present, though much less distinctly. Cerebral angiography showed displacement of the distal branches of the left middle cerebral artery away from the inner table of the skull and an elliptic avascular space consistent with an extracerebral collection (Fig 2). Selective external carotid showed no abnormality. An EEG showed mild slowing in the left anterior and midtemporal region that was made worse by drowsiness. The cerebrospinal fluid protein level was elevated to 72 mg/dL, glucose level was 52 mg/dL, and there were four lymphocytes per cubic millimeter in the cerebrospinal fluid. Electrophoresis revealed a polyclonal increase in the globulins without a discrete oligoclonal band. The VDRL test was nega-

Accepted for publication Nov 6, 1985.

From the Departments of Neurology (Drs Sethi, Patel, and Swift) and Radiology (Dr El Gammal), Medical College of Georgia, Augusta.

Reprint requests to the Department of Neurology, Medical College of Georgia, Augusta, GA 30912 (Dr Sethi).

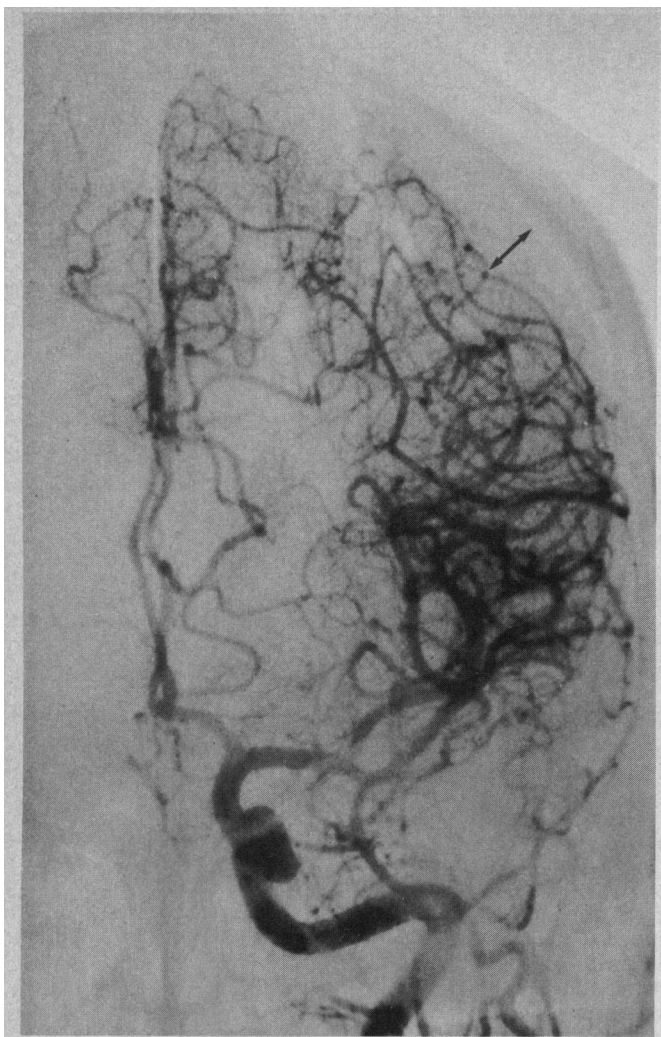

Fig 2.—Left carotid angiogram shows avascular extracerebral lesion (double arrow) with displacement of branches of middle cerebral artery branches away from inner table of skull.

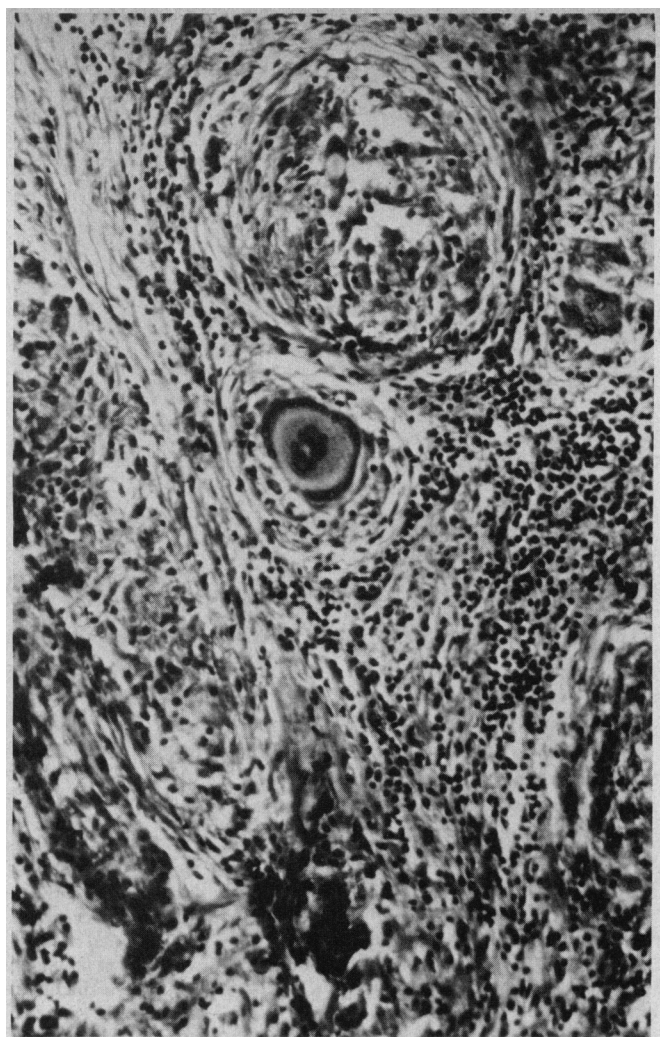

Fig 3.—Histologic specimen shows multiple granulomas with epithelioid cells and giant cells.

tive. Cultures for bacteria, acid-fast bacilli, and fungi were negative. A repeated myelogram showed only mild spondylosis at C5-6 bilaterally. A chest roentgenogram was normal. Angiotensin-converting enzyme was 133 units (normal, 40 to 125 units). A left parietal burr hole biopsy was performed; the specimen revealed non-caseating granulomas with an abundance of histiocytes and Langhans' and foreign-body giant cells (Fig 3). Special stains for bacteria, acid-fast bacilli, and fungi were negative.

With prednisone treatment, 60 mg/day, the episodes stopped. A follow-up CT scan done five months later showed complete resolution of the enhancing mass seen on earlier scans. Prednisone therapy was gradually tapered to 10 mg every other day. One year later he had two additional TIAs. A CT scan showed recurrence of the left extracerebral mass. Prednisone dosage was increased to 60 mg/day, again resulting in complete cessation of the episodes. A follow-up CT scan showed diminution in the size of the extracerebral mass. There has been no change in the spasticity of the

legs and the patient is still bound to a wheelchair.

COMMENT

Sarcoid involvement of the nervous system usually manifests itself as cranial (primarily facial) and peripheral neuropathies, granulomatous meningitis, and hypothalamic-posterior pituitary axis involvement.⁶ Rarer manifestations include myelopathy,⁷ encephalopathy, and intracranial mass lesions.^{8,9} When the neurologic manifestations appear in the setting of established systemic disease, diagnosis usually is easy. Sarcoidosis may be limited to the cranial nervous system,^{5,10,11} however, and when nervous system involvement is the initial and/or only manifestation, misdiagnoses are common.

Subdural location of sarcoid tissues is rare; to our knowledge, there are only two previous reports of subdural

sarcoid granulomas.^{12,13} How the subdural collection of sarcoid granulomas was related to transient focal deficit in our patient is unclear. Complicated migraine cannot be ruled out, but the typical march of paresthesia⁴ or weakness was absent, and the patient had no visual disturbances. A seizure is unlikely because there was no involuntary jerking of the extremities preceding the paresis and the EEG during one episode showed no seizure discharge. It is unlikely to be due to the mass effect because the episodes had started long before the subdural mass was large enough to be seen on CT scan. These attacks resembled TIAs clinically, though the angiogram failed to reveal involvement of larger vessels.

Transient focal neurologic deficits and strokes have only rarely been attributed to sarcoidosis.^{15,16} Transient ischemic attacks have been reported

to be the sole manifestation of neurosarcoidosis, but no convincing samples are given.¹⁷

Sarcoid cardiomyopathy may cause cerebral embolism.¹⁸ Histopathologically, however, involvement of blood vessels and perivascular tissues occurs in brain and meninges and may produce subclinical infarctions.^{2,4} The process mainly affects small vessels, but no vessel is exempt.⁵ One of us (T.E.G.) previously reported angiographically evident arteritis in a

patient with neurosarcoidosis, who, however, did not have TIAs or stroke.¹⁹

Corticosteroids are the treatment of choice for intracranial sarcoid mass lesions. Surgery should be reserved for biopsy or for relief of rapidly increasing intracranial pressure. The excellent outcome in this patient treated with corticosteroids contrasts sharply with the other published case in which the subdural collection was removed surgically.¹²

It is likely that the myelopathy in this patient also was due to neurosarcoidosis. Myelography may be normal in sarcoid myelopathy.²⁰ In neurosarcoidosis, increased cerebrospinal fluid γ -globulin levels occur frequently^{20,21} and oligoclonal bands have been described.²² We propose that neurosarcoidosis should be considered in the differential diagnosis of TIAs, particularly in young patients, as this is a potentially treatable disorder.

References

1. Silverstein A, Feuer MM, Siltzback LE: Neurologic sarcoid: Study of 18 cases. *Arch Neurol* 1965;12:1-11.
2. Urich H: Neurological manifestations of sarcoidosis. *Practitioner* 1969;202:632-636.
3. Aszkanazy CL: Sarcoidosis of the central nervous system. *J Neuropathol Exp Neurol* 1952;11:392-400.
4. Meyer J, Foley J, Campagna Pinto-D: Granulomatous angiitis of the meninges in sarcoidosis. *Arch Neurol* 1953;69:587-600.
5. Reske E, Nielsen AA, Harmsen GE: Periangiitis and panangiitis as a manifestation of sarcoidosis of the brain: Report of a case. *J Nerv Ment Dis* 1962;135:399-412.
6. Delaney P: Neurologic manifestations of sarcoidosis. *Ann Intern Med* 1977;87:336-345.
7. Day AL, Sybert GW: Spinal cord sarcoidosis. *Ann Neurol* 1977;1:79-85.
8. Powers WJ, Miller EM: Sarcoid mimicking glioma: Case report and review of intracranial sarcoid mass lesions. *Neurology* 1981;31:907-910.
9. Brooks BS, Gammal TE, Hungerford GD, et al: Radiologic evaluation of neurosarcoidosis: Role of computed tomography. *AJNR* 1982;3:513-521.
10. Zeman W: Morbus Besnier-Boeck Schauermann, in *Handbuch der Speziellen Pathologischen Anatomie und Histologie*, 1958;XIII/2: 1100-1112.
11. Douglas AC, Maloney FJ: Sarcoidosis of the central nervous system. *J Neurol Neurosurg Psychiatry* 1973;36:1024-1033.
12. De Tribolet N, Lander E: Intracranial sarcoidosis presenting angiographically as a subdural hematoma. *Surg Neurol* 1978;9:169-171.
13. Heaton EB, Zito G, Chauhan P, et al: Intracranial subdural sarcoid granuloma. *J Neurosurg* 1982;56:728-731.
14. Fisher CM: Late-life migraine accompaniments as a cause of unexplained transient ischemic attacks. *Can J Neurol Sci* 1980;7:9-17.
15. Caplan L, Corbett J, Goodwin J, et al: Neuro-ophthalmologic signs in the angiitic form of neurosarcoidosis. *Neurology* 1983;33:1130-1135.
16. Ricker W, Clark M: Sarcoidosis. *Am J Clin Pathol* 1949;19:725-749.
17. James DG, Sharma OP: Neurosarcoidosis. *Proc R Soc Med* 1967;60:1169-1174.
18. Case 46-1975, Case records of the Massachusetts General Hospital: Weekly clinicopathological exercises. *N Engl J Med* 1975;293:1138-1145.
19. Lawrence WP, Gammal TE, Pool WH: Radiological manifestations of neurosarcoidosis: Report of three cases and review of the literature. *Clin Radiol* 1974;25:343-348.
20. Caroscio JT, Yahr MD: Progressive myelopathy due to sarcoid. *Clin Neurol Neurosurg* 1980;82:217-222.
21. Colover S: Sarcoidosis with involvement of nervous system. *Brain* 1948;71:451-475.
22. Kinnman T, Link H: Intrathecal production of oligoclonal IGM and IGG in CNS sarcoidosis. *Acta Neurol Scand* 1984;69:97-106.