

## Neuropsychological Findings in Epileptic Amnesic Attacks

*Roberto Gallassi, Paolo Pazzaglia, Sebastiano Lorusso, Angela Morreale*

Istituto di Clinica Neurologica dell'Università di Bologna, Italia

**Key Words.** Epilepsy · Memory · Transient global amnesia

**Abstract.** A clinical observation and a neuropsychological study in a patient with amnesic attacks due to epileptic seizures were performed.

### Introduction

Complex partial seizures may produce ictal memory disturbances, especially amnesia concerning the seizure itself, but amnesia as the sole epileptic manifestation is rare [1]. We report a case of a man affected by epileptic seizures causing ictal memory disturbances resembling transient global amnesia (TGA) attacks.

### Case Report

B.A. is a 67-year-old right-handed man with 13 years of formal education; he was a bank clerk before retiring 10 years ago. His medical history was uneventful up to the age of 64 when his wife one day noted a sudden loss of contact, repetitive movements of swallowing and pallor; a few seconds later con-

sciousness returned to normal but memory disturbances started. He became unable to retain new information and he repeated the same questions; amnesia for recent events and slight time disorientation were also present. This memory impairment continued for about 15 min, during which time the patient was quiet and rather indifferent but was able to perform complex operations such as reading or speaking. He fully recovered but a complete amnesia concerning the episode persisted. The patient remained in good health until 6 months later when an identical episode occurred; after 4 months he presented the third attack and from that time these events increased to 1–2 a month. They frequently begin during sleep; the patient presents automatisms of noisy swallowing and once awake the memory disability appears; the attacks also occur during the day and last from 10 to 60 min. The patient came under our observation at the age of 66 when he had had 25 attacks (20 in the last year). Apart from the episodes of amnesia, he also complained of memory difficulties which had begun at about the same time as the onset of seizures. Careful investiga-




Fig. 1. EEG showing an excess of theta activity in the right temporal region.

tion of the patient's history revealed another rare type of seizures characterized by epigastric 'aura' and a general feeling of well-being for a few seconds; sometimes the amnesic attack followed after a brief time interval.

General and neurological examinations were normal. EEG showed (fig. 1) an excess of theta activity in the right temporal region; CT scan showed a moderate and diffuse cortical atrophy. Considering an epileptic origin of the attacks the most likely hypothesis, we prescribed phenytoin (250 mg/day) and the attacks decreased to 8 (2 diurnal and 6 nocturnal) during 1 year of follow-up.

### Neuropsychological Testing

A neuropsychological examination was performed to evaluate the intercritical memory deficits and to establish whether such disturbances are primary or secondary to a mental deterioration. The tests administered are listed in table I. We report their main characteristics.

Our 'brief mental deterioration battery' (BMDB), described in a previous study [sub-

Table I. Test results

<i>Brief mental deterioration battery</i>	
Rey's 15 words – long-term	4/15
Immediate visual memory	20/22
Simple analogies test	19/20
Barrage – time, s	46
Discriminant score	1.87
<i>Other memory tests</i>	
Rey's 15 words – short-term	29/75
Verbal digits span	4
Spatial span	5
Spatial learning	8/20
Logical memory	
Immediate recall	12/26
Delayed recall	8/26
Total score	20/52
Associate learning of words	7.5/22.5

mitted], is derived by means of a discriminant analysis from the 'mental deterioration battery' [2] and includes the long-term memory item of *Rey's* [3] '15 words test' (15W-LT), 'immediate visual memory' (IVM), 'simple analogies test (SAT) and the time of performance at the Barrage test. In addition to these four neuropsychological items, age and educational level are also included in the calculation of the discriminant score (DSC) that summarizes all variables of BMDB. The threshold value of DSC is 0 and lower scores are considered pathological. *Rey's* [3] 15 words test is a free recall task of 15 common words read by the examiner; this task is repeated 5 times and the sum of all words recalled is the score of short-term memory (15W-ST). After 15 min employed in non-verbal tasks the patient must recall the words and this is the score of 15W-LT. In the IVM test 22 abstract stimuli are presented one at

a time for a few seconds; then the stimulus is removed and the patient is asked to point it out among four different options. SAT is a logic item in which the patient must correctly complete 20 analogies of the type: sheep:lamb = cow:(calf). Barrage is a test of visual attention similar to the Toulouse-Pieron test of which the time of performance enters as a variable in BMDB. Verbal digits span and spatial span assessed by Corsi's blocks are employed as tests of immediate memory. Spatial learning was investigated by means of blocks 'supra-span +2' in 20 presentations. Logical memory was explored with a 'brief story' similar to those of the Wechsler memory scale (WMS), proposed by *De Renzi* [4], which includes immediate recall and delayed recall after 10 min; total score is the sum of the above-mentioned scores. Associate learning of paired words (AL) is a test similar to that of WMS used by *De Renzi* [4]. Finally, in the 'serial position curve' (SPC) test, the subject is asked to give an immediate free recall of ten lists of 12 bisyllabic words. The first items of the list represent the long-term storage component while words at the end are present in the short-term store [5].

## Results

Table I lists the testing score. It can be seen that the DSC of BMDB is normal but the patient presents a deficit of verbal memory which is more evident in the long-term component (15W-LT, AL). In the logical memory, total score corrected for age and educational level is not pathological but delayed recall is poor. There is also a deficit of the long-term component in SPC and the curve does not have a normal U-shaped aspect (fig. 2) [12].

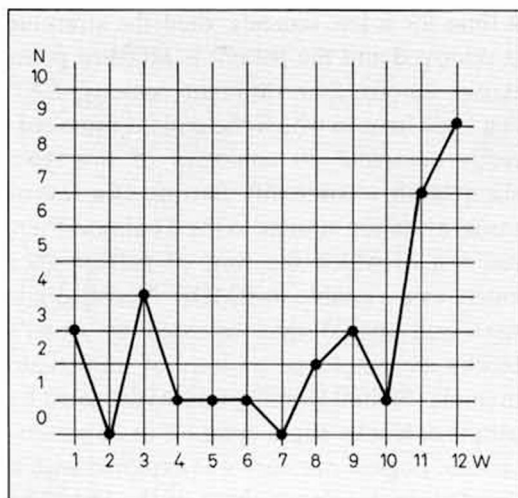


Fig. 2. Performance at the 'serial position curve'. W = Words position; N = number of words recalled.

## Discussion

Our patient presents multiple attacks of anterograde amnesia associated with short retrograde amnesia and a persistent deficit of long-term verbal memory without mental deterioration. It is likely that the attacks are due to epileptic seizures because they always follow a brief alteration of consciousness associated with oral automatisms, although it is difficult to ascertain whether they are ictal or postictal phenomena. The 2 patients previously reported by Pritchard et al. [1] showed transient anterograde amnesia as the sole manifestation of epileptic seizures.

In our case the acute memory failure appears similar to that of TGA attacks. Also the persistence of memory impairment cannot be considered a differential element against TGA. In fact some authors [6, 7] have demonstrated a permanent deficit of long-term verbal memory after TGA.

The EEG aspects too in our case are not typical of epilepsy and similar abnormalities are found in TGA patients [8–11]. However, we believe that the episodes of the case must be considered as 'epileptic amnesic attacks' because they are of short duration, recurrent and frequent and respond favorably to anti-epileptic therapy. The residual memory disturbances noticed by the patient himself are similar to the complaints of other epileptic patients, especially those with temporal lobe seizures [12, 13]. These very rare amnesic attacks due to epileptic mechanism are therefore well characterized. In fact, albeit the acute and chronic memory impairment is similar to TGA phenomena, several clinical features are distinct.

This observation can be in agreement with those authors [9, 14] who deny the epileptic origin of TGA previously emphasized by others [8, 15–17].

## References

- 1 Pritchard, P.B., III; Holmstrom, V.L.; Roitzsch, J.C.: Epileptic amnesic attacks: differentiation from transient global amnesia and benefit from antiepileptic drugs. *Neurology* 34: suppl. 1, p. 161 (1984).
- 2 Caltagirone, C.; Gainotti, G.; Masullo, C.; Miceli, G.: Validity of some neuropsychological tests in the assessment of mental deterioration. *Acta psychiat. scand.* 60: 50–56 (1979).
- 3 Rey, A.: Mémorisation d'une série de 15 mots en 5 répétitions. *L'examen clinique en psychologie* (PUF, Paris 1958).
- 4 De Renzi, E.: Le amnesia. *Neuropsicologia clinica*, pp. 137–148 (Angeli, Milano 1977).
- 5 Miller, E.: On the nature of the memory disorder in presenile dementia. *Neuropsychologia* 9: 75–81 (1971).
- 6 Mazzucchi, A.; Moretti, G.; Callarra, P.; Parma, M.: Neuropsychological functions in follow-up of transient global amnesia. *Brain* 103: 161–178 (1980).

- 7 Caffarra, P.; Moretti, G.; Mazzucchi, A.; Parma, M.: Neuropsychological testing during a transient global amnesia and its follow-up. *Acta neur. scand.* 63: 44–50 (1981).
- 8 Tharp, B.: The electroencephalogram in transient global amnesia. *Electroenceph. clin. Neurophysiol.* 26: 96–99 (1969).
- 9 Mathew, N.; Meyer, J.: Pathogenesis and natural history of transient global amnesia. *Stroke* 5: 303–311 (1974).
- 10 Jaffe, R.; Bender, M.: EEG studies in the syndrome of isolated episodes of confusion with amnesia 'transient global amnesia'. *J. Neurol. Neurosurg. Psychiat.* 29: 472–474 (1966).
- 11 Nausieda, P.: Transient global amnesia. *J. Am. med. Ass.* 241: 2703 (1979).
- 12 Mayeux, R.; Brandt, J.; Rosen, J.; Benson, F.: Intercritical memory and language impairment in temporal lobe epilepsy. *Neurology* 30: 120–125 (1980).
- 13 Loiseau, P.; Strube, E.; Broustet, D.; Battellocchi, S.; Gomeni, C.; Morselli, P.L.: Learning impairment in epileptic patients. *Epilepsia* 24: 183–192 (1983).
- 14 Kaplan, L.B.: Transient global amnesia. *Handbook of clinical neurology*, vol. 1, pp. 205–218 (Elsevier, Amsterdam 1985).
- 15 Fisher, C.M.; Adams, R.D.: Transient global amnesia. *Acta neur. scand.* 40: suppl. 9, pp. 1–83 (1964).
- 16 Cantor, F.: Transient global amnesia and temporal lobe epilepsy. *Neurology* 21: 430–431 (1971).
- 17 Green, H.; Bennet, D.: Transient global amnesia with a previously unreported EEG abnormality. *Electroenceph. clin. Neurophysiol.* 36: 409–413 (1974).

Received: May 2, 1985

Accepted: October 2, 1985

Dr. Roberto Gallassi, MD,  
Istituto Clinica Neurologica,  
Via Ugo Foscolo 7,  
I-41023 Bologna (Italy)