

Balint syndrome: a case of simultanagnosia

Berti A., Papagno C., Vallar G.

Istituto di Clinica Neurologica, Università di Milano

We describe a patient with a bilateral posterior lesion, who showed optic ataxia, gaze apraxia and the symptom which most authors call the inability to see more than one thing at a time. We discuss the last feature and the term simultanagnosia sometimes used to indicate it. Furthermore we stress the unusual localization of the lesion in this patient.

Key-Words: Balint syndrome — simultanagnosia — parietal lobe

A 65 year-old retired right-handed worker, with five years schooling, had suffered sudden, blurred vision ten years earlier for two days. He was hospitalized on 17 December 1983 due to a recurrence of sudden blindness which he described as if somebody had suddenly turned off the light in the room.

Neurological examination showed neither motor nor somatosensory deficits. On confrontation, the visual field seemed narrower than normal, though the patient could detect some moving stimuli at the periphery.

Ocular movements to verbal command in the four cardinal directions were normal. Tracking at different speed in various directions was impossible at first; however it was possible to obtain irregular saccadic eye movements with under- and overshooting by moving the target some cms. at a time, stopping and then instructing the patient to look for the target again. The performance was better when the patient's own finger, moved by the examiner, was the target. When the patient was asked to look at each of the examiner's hands alternately, held in front of him, one in each of his visual hemi-fields, some irregularly saccadic ocular movements with both under and overshooting were elicited. Acoustically elicited movements were normal. Spontaneous eye movements were present, though when the patient had focused on an object, he tended to keep his gaze fixed. Even if the patient was allowed to move his head, he did not look at lateral stimuli if there was no verbal information about their location.

Manual reaching out to motionless objects was impossible. In fact, due to the deficit on the visual field periphery, the patient seemed to have tubular vision. On the other hand, manual reaching out

to a swinging target was possible in both visual hemi-fields with either hand, with eyes either open or closed in primary position. Performance improved when the patient was allowed to look at the target, but there was almost always overshooting; the patient could not reach the target correctly although he claimed to see it perfectly, and this caused him much surprise. The deficit was more evident if the task was performed with the right hand.

He had no difficulty in pointing with both hands and with closed or open eyes to parts of his own body named by the examiner.

He showed neither apraxia nor disorders of topographic memory.

His visual discrimination of lengths and sizes of pairs of geometrical figures was good. There were pronounced difficulties in matching, naming and indicating colours. Anomic defects were present: the patient was not able to name common objects presented in different modalities, but he could describe how to use them perfectly.

The patient was required to mark some circles drawn on a sheet of paper with a pencil.

In this task he did not show unilateral neglect for space: in fact he marked all the circles – including the smallest – because his visual acuity was practically normal. On the other hand it was evident (see Fig. 1) that he had no strategy in the search and the sign used to mark the circles was placed close to but outside the circle. The patient said he could not perform correctly because as soon as he got near the sheet with the pencil, the circle disappeared. The same phenomenon was present when the patient was asked to mark the center of a circle (see Fig. 2).

In addition, the patient had great difficulty in per-

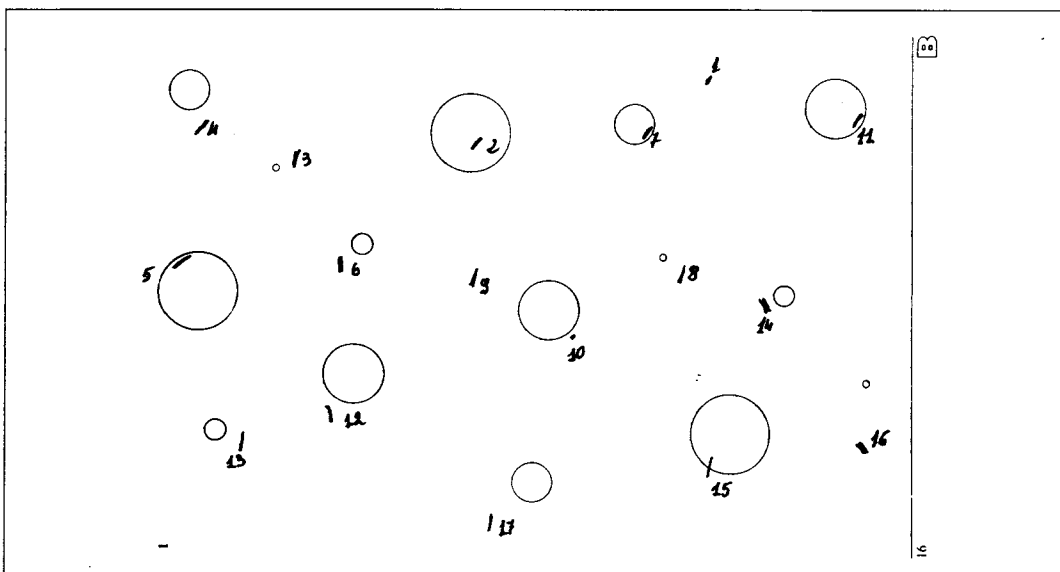
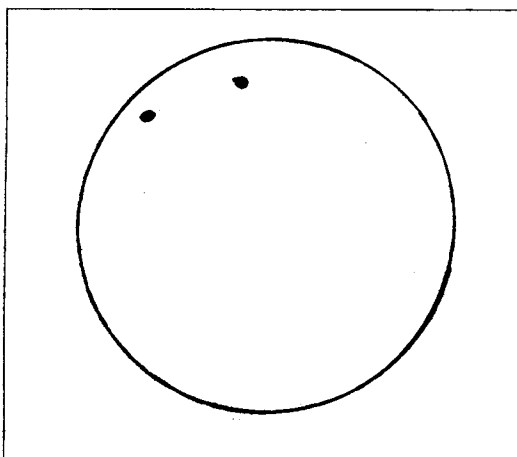


Fig. 1. Patient's performance in making all the circles drawn on a sheet of paper.

ceiving the examiner's hand when placed between his face and that of the examiner. He claimed that he could see either the eyes and perhaps the nose but not the face as a whole. The mouth was seen only when the lips were moving. Furthermore, he asserted that he could not perceive two parts of the face simultaneously, but only one at a time.

Reading was very impaired: only occasionally the patient was able to read single letters, but not a

Fig. 2. Attempts to place a point in the center of a circle.



whole word. He could read the acronym USSR, written in block letters 10 mm. high, but he did not recognize the acronym USA, written in the same characters very close to the first word, though he could see the letter U and with great difficulty the letter A but not the S.

When shown Poppelreuter's figures he could almost always recognize one of the overlapping items only (see Fig. 3).

A CT scan showed an ischemic lesion in the left hemisphere involving the lateral part of the occipital lobe and sparing the gyrus fusiformis and the calcarine fissure. In the right hemisphere there was a hemorrhagic lesion involving the parieto-occipital junction and the posterior part of the medial temporal gyrus. In the parietal area only the inferior part appeared involved (see Fig. 4).

Discussion

Our patient presented the three main features of the Balint syndrome: optic ataxia, gaze apraxia and the phenomenon described by most authors as an inability to see more than one thing at a time.

This paper will not discuss optic ataxia and gaze apraxia but will deal with the symptom described as an inability to see more than one thing at a time. Balint [2] believed that this deficit was due to a narrowing of visual attention. In our patient, this hypothesis contrasts with the ability to scan, which was preserved in spite of the severe gaze apraxia. In addition, even though he appeared to have tubular vision, it was possible to obtain some reaction when moving stimuli were used.




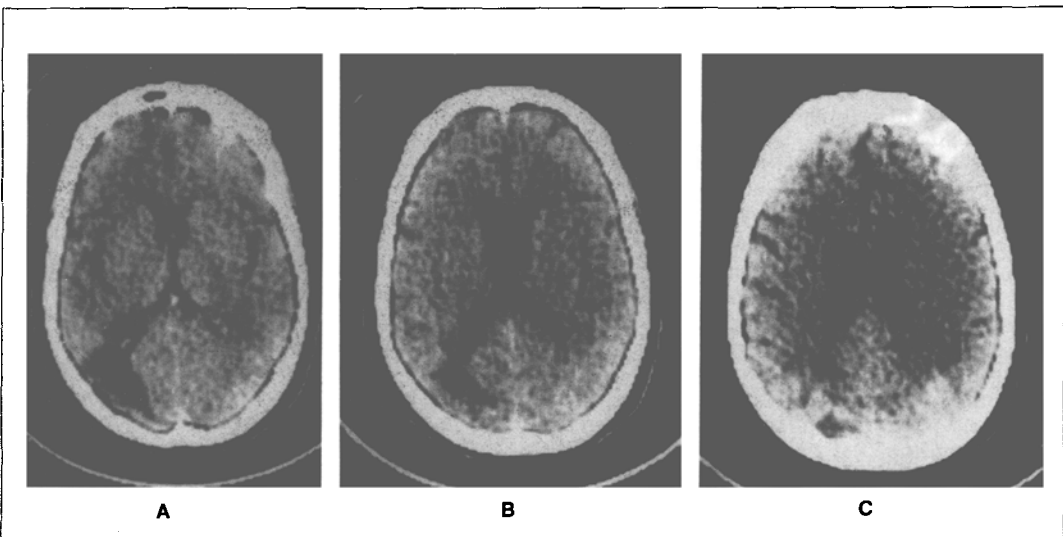
Fig. 3. Poppelreuter's figures.

Luria [10, 11] described two patients showing this symptom and used the term "simultanagnosia". The term "simultanagnosia" is found in the literature to indicate different perceptive disorders. Wolpert [15] was the first to employ this term to describe a patient unable to give an adequate account of a picture as a whole, though able to point out most of its individual features. Wolpert considered this syndrome to be due to a disorder at the "highest level of perception". Kinsbourne and

Warrington [9] described patients – with clinical evidence of left hemisphere lesion – who appeared to present a symptom corresponding to Wolpert's description, but they demonstrated that (at least in their patients) the difficulty in perceiving the meaning of the picture was not due to a disorder of the "final step in perception", or to an "apprehension of the whole" (Gesamtauffassung). By means of the brief exposure of visual forms singly and in pairs Kinsbourne and Warrington were able to show that there was a deficit in simultaneous visual form recognition, namely: their patients could see two forms, but they recognized only one. According to Kinsbourne and Warrington such a deficit could account for the clinical features of simultanagnosia. Conversely our patient, when he was indicating one by one the individual features of the examiner's face, was always quite aware of the fact that he was looking at a face though he could "see" only one single feature of it at a time. It must be noted that most cases of Balint syndrome, with bilateral brain lesions, [4, 10, 11, 14, 1, 13, 5] show the phenomenon present in our patient, i.e. the inability to see (but not to recognize, as observed by Kinsbourne and Warrington) more than one object at a time.

To avoid confusion, it is necessary to be aware of the ambiguity of the term "simultanagnosia": in some cases [15] it seems to refer to a kind of agnosia for the whole meaning of a picture even though the perception of single fragments is possible. On the other hand, in most cases of Balint syndrome, e.g. Luria [10], it refers to the "extinction" of visual stimuli when the patient focuses on an adjacent one.

Fig. 4. CT scan showed an ischemic lesion in the left occipital lobe and a hemorrhagic lesion in the right parieto-occipital junction involving the posterior part of the medial temporal gyrus.



This distinction is important not only for its conceptual value, but also for its clinical significance. In fact, while the first type of disorder seems to follow injuries to the inferior part of the left occipital lobe [9] the second kind is part of the Balint syndrome resulting from a bilateral posterior lesion.

Post mortem data are available in six cases, [2, 6, 4, 12, 7]. In the case of Hijdra [5] the lesion site was assessed by CT scan. The element common to all of cases is the bilateral involvement of the parietal area. The parietal lobe is damaged either exten-

sively or in its upper part. Only in the Hoff and Potzl case [6] the lesion involved the occipital lobe of the left hemisphere and the parieto-occipital convexity of the right hemisphere. In the patient of Kase et al [7] a bilateral lesion confined to the upper parietal lobe was shown. On the basis of these data De Renzi [3] suggested that a lesion of the upper part of the parietal lobe is needed to determine the syndrome. The CT scan of our patient showed a different picture: the left parietal lobe seemed to be spared, whereas on the right the lesion involved the inferior part of the parietal lobe.

Sommario

Viene descritto il caso di un paziente, portatore di lesioni vascolari bilaterali posteriori, che presentava: atassia ottica, aprassia dello sguardo e il sintomo che molti autori definiscono incapacità a vedere più di uno stimolo per volta. Quest'ultimo disordine e il termine "simultanagnosia" vengono brevemente discussi. Infine viene sottolineata l'inusuale localizzazione delle lesioni cerebrali di questo paziente.

Address reprint requests to: Dr. Giuseppe Vallar
Centro di Neuropsicologia Università di Milano,
Via Francesco Sforza, 35 - 20136 Milano

References

- [1] ALLISON R.S., HURWITZ L.J., GRAHAM WHITE J., WILMOT T.J.: *A follow-up of a patient with Balint's syndrome*. Neuropsychologia, 7, 319-333, 1969.
- [2] BALINT R.: *Seelenlähmung des Schauens, optische Ataxie, räumliche Störung der Aufmerksamkeit*. Monatschr Psych Neur, 25, 51-71, 1909.
- [3] DE RENZI E.: *Disorders of Space Exploration and Cognition*. Chichester Wiley (1982).
- [4] HECAEN H., AJURIAGUERRA J.: *Balint's syndrome (Psychic paralysis of visual fixation) and its minor forms*. Brain, 77, 373-400, 1954.
- [5] HIJDRA A., MEERWALDT J.D.: *Balint's syndrome in a man with border-zone infarcts caused by atrial fibrillation*. Clin. Neurol. Neurosurg, 86-1, 51-54, 1984.
- [6] HOFF H., POTZL D.: *Über ein neues parieto-occipitales syndrom*. Hb. Psychiat. 52: 173-218, 1935.
- [7] KASE C.S., TRONCOSO J.F., COURT J.E., TAPIA J.F., MOHR J.P.: *Global spatial disorientation*. J. Neurol. Sci. 34: 267-278, 1977.
- [8] KINSBOURNE M., WARRINGTON E.K.: *A disorder of simultaneous form perception*. Brain 85: 461-486, 1962.
- [9] KINSBOURNE M., WARRINGTON E.K.: *The localizing significance of limited simultaneous visual form perception*. Brain 86: 697-702, 1963.
- [10] LURIA A.R., PRAVDINA-VINARSKAYA E.N., YARBUSS A.L.: *Disorder of ocular movement in a case of simultanagnosia*. Brain 86: 219-228, 1963.
- [11] LURIA A.R.: *Disorder of "simultaneous perception" in a case of bilateral occipito-parietal brain injury*. Brain 82: 437-449, 1959.
- [12] MICHEL F., JEANNEROD M., DEVIC M.: *Trouble de l'orientation visuelle dans les trois dimensions de l'espace (A propos d'un cas anatomique)*. Cortex 1: 441-466, 1965.
- [13] SORGATO P.: *Analisi neuropsicologica delle complicanze cerebrali a lungo termine dell'eclampsia*. Riv. Pat. Nerv. Ment. 97: 371-384, 1976.
- [14] TYLER H.R.: *Abnormalities of perception with defective eye movements (Balint's syndrome)*. Cortex 4: 154-171, 1968.
- [15] WOLPERT I.: *Die Simultanagnosie Störung der Gesamtaufassung*. Z. ges. Neurol. Psychiat. 93: 397-415, 1924.