

# Valproate-induced hyperammonemic encephalopathy treated by L-ornithine-L-aspartate: a case report

**Authors:** Yan Yu-E,<sup>A</sup> Liu Zhi-Qin,<sup>A</sup> Lei Hui,<sup>A</sup> Di Zheng-Li,<sup>B</sup> Zhang Fang<sup>B</sup> and Yong Fang<sup>C</sup>

## ABSTRACT

A 63-year-old man developed reduced consciousness and dysphagia progressively. Examination and parameters were normal, except for a Glasgow Coma Scale score of seven, and his grading on the swallow water test increased from grade 1 to grade 5. Brain imaging and blood tests were unexplainable except by high plasma ammonia. His past medical history included cerebral infarction, hypertension and epilepsy induced by cerebral hyperperfusion syndrome. He was receiving antiepileptic treatment of continuously intravenously pumped sodium valproate of 64 mg/h for 4 days, which overlapped for 12 hours with taking 500 mg sustained release tablets. Sodium valproate was stopped; testing demonstrated normal plasma concentrations of sodium valproate and elevated concentrations of ammonia. Ornithine aspartate was administered. The patient's level of responsiveness and ammonia levels gradually improved. The patient was also being treated with ceftriaxone sodium for a hypostatic pneumonia and with desmopressin for diabetes insipidus. There is an association between sodium valproate and hyperammonaemia and encephalopathy. Immediate recognition of the serious but uncommon adverse effects is essential. To our knowledge this is the first report of ornithine aspartate being used in this disorder.

**KEYWORDS:** Sodium valproate, hyperammonaemia, encephalopathy, ornithine aspartate, cerebral hyperperfusion syndrome

**DOI:** 10.7861/clinmed.2023-0137

## Case presentation

A 63-year-old man was referred to the emergency department after he developed a generalised tonic clonic seizure following a severe headache of sudden onset.

The patient was undergoing rehabilitation following right carotid artery stenting (CAS). His significant medical history

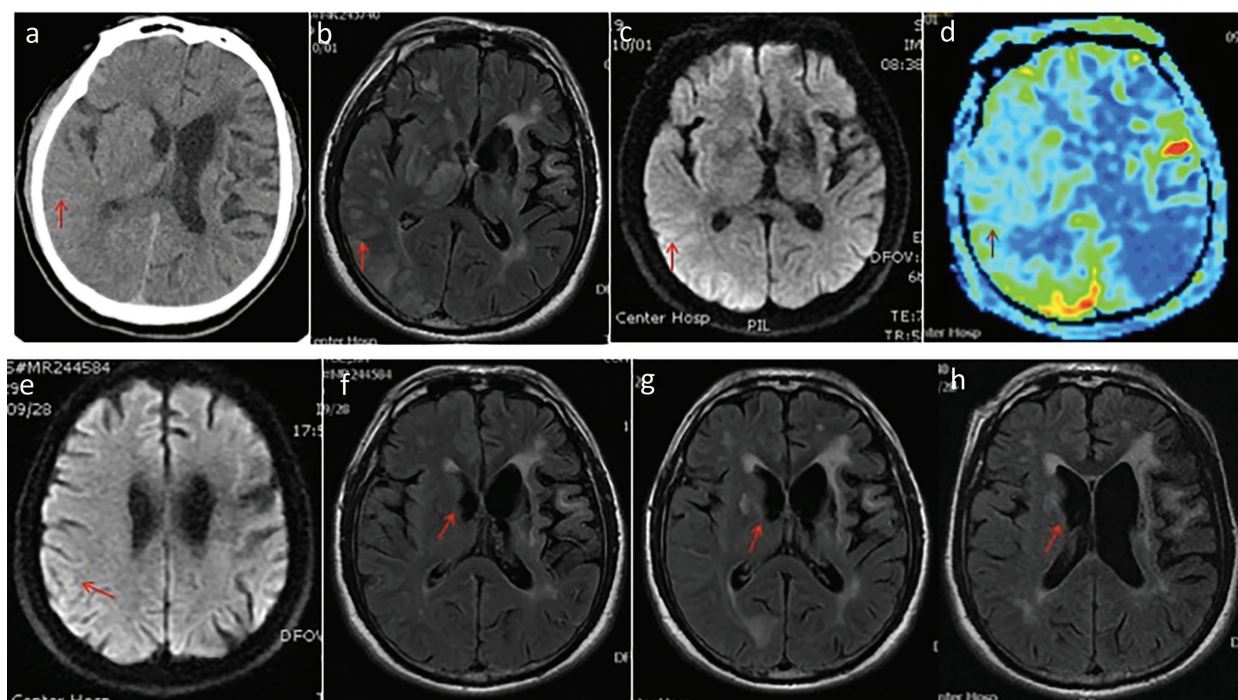
included cerebral infarction, central diabetes insipidus (CDI) and hypertension. His drug history included aspirin 100 mg daily, ticagrelor 90 mg twice daily, atorvastatin calcium 20 mg daily, probucol 0.375 g twice daily, and desmopressin 0.05 mg twice daily. Treatment with levamlodipine 2.5 mg daily had been discontinued because of generally normal blood pressure secondary to CAS. He had retired from his work in a local die-casting company and lived with his family. He was independent in personal activities of daily living, drank alcohol occasionally and was a non-smoker.

On examination, he was responsive to pain but non-communicative. His blood pressure was 154/75 mmHg and other parameters were stable. His chest was clear, heart sounds were normal and his abdomen was soft and non-tender. His lower limbs had no signs of deep venous thrombosis. Neurologically, a left-sided mouth deviation was noted, power of left limbs was IV degree, power of right limbs and sensations were normal, and muscle tone was flaccid throughout. His reflexes were normal, and his pupils were equal and reactive. Blood tests, including electrolytes and arterial blood gases, were normal. Computed tomography (CT) of the head suggested slightly high signal in blood supplement area of the right carotid artery (Fig 1a). Arterial spin labelling (ASL) (Fig 1d) and fluid attenuated inversion recovery (FLAIR) (Fig 1b) revealed hyperperfusion of right frontal lobe, while diffusion-weighted imaging (DWI) (Fig 1c) did not show evidence of stroke. Cerebral hyperperfusion syndrome was considered and the patient was admitted to the intensive care unit.

Mannitol 20 g twice daily and glycerol fructose 250 ml twice daily to reduce intracranial pressure and antiepileptic treatment with sodium valproate intravenously (64 mg/h) were immediately prescribed. He was relieved from seizures after 24 hours. Blood tests showed hyperuricemia and sodium bicarbonate tablets were prescribed after consultation with a nephrological doctor. He was transferred to the ordinary ward on the third day of hospitalisation and sustained released tablets of sodium valproate (500 mg, twice daily) were added.

His wife reported reduced level of consciousness and dysphagia the fourth day. Examination showed he was responsive to calling and communicative. His body temperature was 37.7°C. His chest was unclear at the bottoms of bilateral lungs. There was no change in neurological examination. Blood routine test showed elevated white cells, predominantly neutrophils. Arterial blood gases demonstrated slightly elevated base excesses (3.5 mmol/L) and hydrogen carbonate ( $\text{HCO}_3^-$ , 27.8 mmol/L),

**Authors:** <sup>A</sup>professor of neurology, Xi'an Central Hospital, Medical College of Xi'an Jiao Tong University, Xi'an Shaanxi, China; <sup>B</sup>attending neurologist, Xi'an Central Hospital, Medical College of Xi'an Jiao Tong University, Xi'an Shaanxi, China; <sup>C</sup>resident physician, Xi'an Central Hospital, Medical College of Xi'an Jiao Tong University, Xi'an Shaanxi, China.



**Fig 1. Cerebral hyperperfusion syndrome after carotid stenting.** (a) CT scan shows regional swelling as sulcal effacement on the right temporo-parieto-occipital lobe. (b) Fluid attenuated inversion recovery (FLAIR) shows regional swelling. (c) DWI shows no evidence of acute ischemic stroke. (d) ASL revealed relative hyperperfusion in the same region. Under strict blood pressure control, the patient improved a few days later: (e) DWI shows no evidence of acute ischemic stroke. Follow-up T2 FLAIR image (f) 3 days, (g) 2 weeks and (h) 1 month later showed remission of the regional swelling.

the pH value was 7.45; other parameters were stable. DWI (Fig 1e) and FLAIR (Fig 1f) of the head revealed relieved hyperperfusion state. CT of the chest (Fig 2a, b) demonstrated bilateral hypostatic pneumonia and Ceftriaxone sodium was administered. However, his condition deteriorated to drowsiness and then lethargy.

He was reviewed by second-line doctor and sodium valproate-induced encephalopathy was considered. Sodium valproate was discontinued and ammonia levels (54  $\mu\text{mol/L}$ , normal range 9–47  $\mu\text{mol/L}$ ) and plasma concentration of sodium valproate (96  $\mu\text{g/L}$ , normal range 50–100  $\mu\text{g/ml}$ ) were tested immediately.

Literature review suggested that L-carnitine, naloxone, arginine, lactulose and even haemodialysis could be given with good effect and arginine was administered. The patient responded by jerking several times and was still drowsy. Next, L-ornithine L-aspartate (LOLA) 10 g was infused. His consciousness improved progressively and he regained the ability to talk and swallow. He remained well off sodium valproate, and was not restarted on any antiepileptic drug. His ammonia levels, consciousness and ability to swallow normalised gradually. Follow up by FLAIR of the head (Fig 1f, g, h) and CT of the chest (Fig 2c, d) revealed relieved hyperperfusion state and hypostatic pneumonia respectively.

## Discussion

### Mechanism and metabolism of sodium valproate

The main antiepileptic mechanisms of sodium valproate are inhibition of gamma-aminobutyric acid (GABA) transaminase enzyme, thereby increasing GABA levels in the brain, and blocking

of voltage-gated sodium channels and T-type calcium channels, thereby reducing the frequency of neuronal action potentials.<sup>2</sup> Moreover, it is a mood stabiliser for treating several psychiatric disorders, including psychosis in bipolar disorder, major depressive disorder and post-traumatic stress disorder.<sup>3</sup>

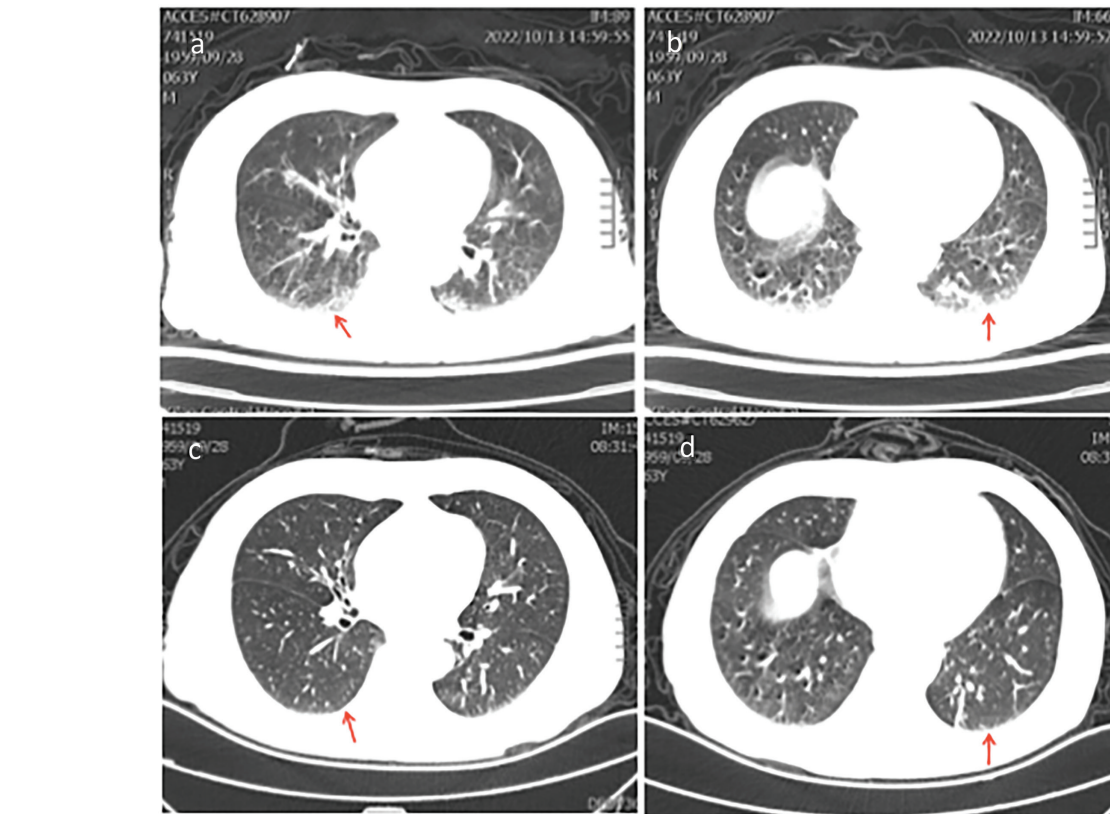
Valproate is metabolised in the liver via three main steps: first, glucuronic acid conjugation within the liver; second,  $\omega$ -oxidation within the cytoplasm, resulting in the toxic metabolite 4-EN-VPA; and third,  $\beta$ -oxidation within the mitochondria, resulting in the non-toxic metabolite 2-EN-VPA.<sup>4</sup>

### Mechanisms for valproate-induced encephalopathy

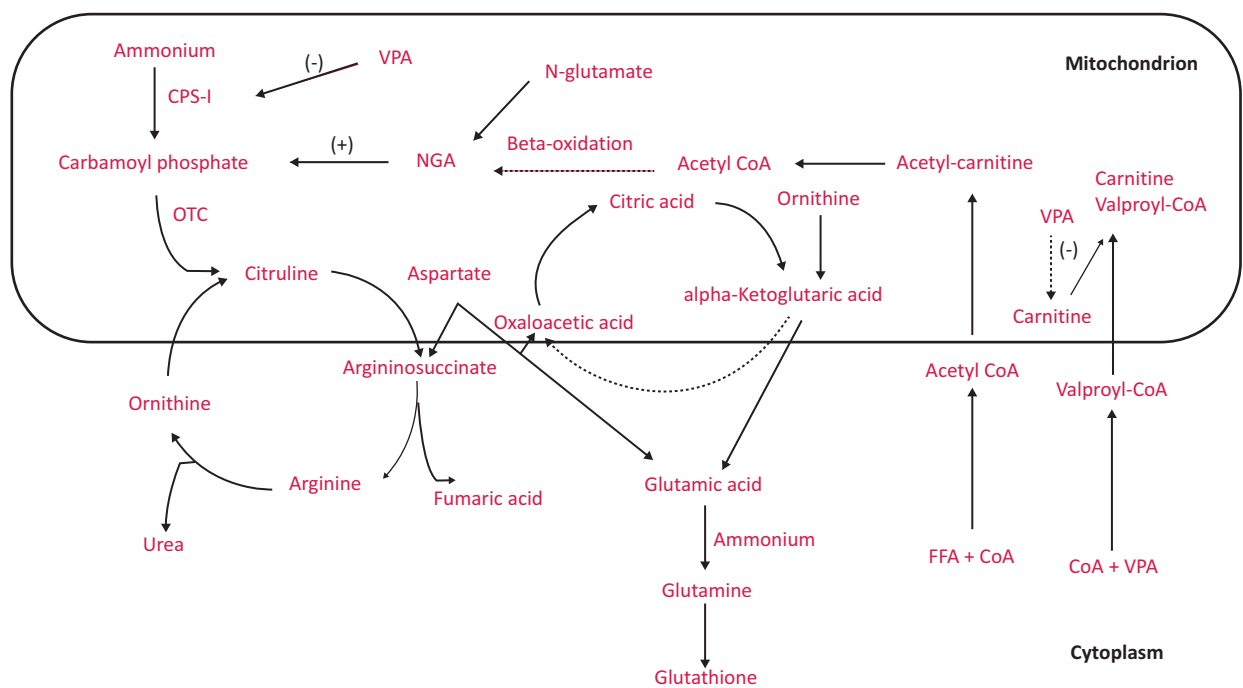
The exact mechanisms of valproate-induced encephalopathy have not been fully understood. Up to date, three possible mechanisms have been proposed: hyperammonemia,<sup>6</sup> L-carnitine deficiency<sup>7</sup> and urea cycle enzyme dysfunction.<sup>8</sup> Significantly, the three above mechanisms are correlated: valproate causes impaired tubular reabsorption of carnitine and carnitine deficiency can lead to a shift from  $\beta$ -oxidation towards  $\omega$ -oxidation, resulting in increased 4-en-valproate, which interferes the urea cycle and increase plasma ammonia levels.<sup>7</sup>

### LOLA in valproic acid-induced encephalopathy

There have previously been no documented cases using LOLA in valproate-induced encephalopathy. Its exact mode of action in this setting is unclear but probably due to its effects of accelerating urea cycle, tricarboxylic acid cycle and glutathione synthetisation (Fig 3), which further facilitated ammonia excretion



**Fig 2. Hypostatic pneumonia after cerebral hyperperfusion syndrome.** (a, b) CT scan shows hypostatic effect in bilateral lungs. (c, d) CT scan shows remission of the hypostatic effect in bilateral lungs after anti-inflammation treatment.



**Fig 3. The effect of valproate in the urea cycle and free fatty acid oxidation and the mechanism of ornithine aspartate in decreasing the ammonia levels.** CoA = coenzyme A; CPS-I = carbamyl phosphate synthetase I; FFA = free fatty acid; NAG = N-acetylglutamate; OCT = ornithine carbamoyl transferase.

in nontoxic metabolites and thus decrease the plasma ammonia level.<sup>9</sup>

In this case, ammonia levels normalised after LOLA administration and drug withdrawal. Although the patient was taking a single antiepileptic drug, he had had a recent treatment with antibiotics and took demeclocycline for 7 years; therefore, renal tubular absorption might have been affected. He also had a hyperuricemia and had taken sodium bicarbonate tablets, which might result in plasma alkalinisation and not be beneficial for ammonia excretion.

## Conclusion

Sodium valproate is widely used for the treatment of seizure disorders and psychiatric disorders.<sup>10</sup> Hyperammonaemia is an uncommon but important and possibly fatal adverse effect of sodium valproate. LOLA application in such cases has not previously been reported. In this case, we demonstrate that LOLA and the withdrawal of sodium valproate were sufficient to normalise the patient's ammonia levels. ■

## References

- 1 Petrusevski G, Naumov P, Jovanovski G, Nagl SW. Unprecedented sodium-oxygen clusters in the solid-state structure of trisodium hydrogentetraalproate monohydrate: A model for the physiological activity of the anticonvulsant drug Epilim®. *Inorg Chem Commun* 2008;11:81–4.
- 2 Ghodke-Puranik Y, Thorn CF, Lamba JK *et al*. Valproic acid pathway: pharmacokinetics and pharmacodynamics. *Pharmacogenet Genomics* 2013;23:236–41.
- 3 Baumgartner J, Hoefflich A, Hinterbuchinger B *et al*. Fulminant onset of valproate-associated hyperammonemic encephalopathy. *Am J Psychiatry* 2019;176:900–3.
- 4 Vazquez M, Fagiolino P, Maldonado C *et al*. Hyperammonaemia associated with valproic acid concentrations. *Biomed Res Int* 2014;2014:217269.
- 5 Nicolai J, Aldenkamp AP, Huizenga JR, Teune LK, Brouwer OF. Cognitive side effects of valproic acid-induced hyperammonemia in children with epilepsy. *J Clin Psychopharmacol* 2007;27:221–4.
- 6 Carr RB, Shrewsbury K. Hyperammonaemia due to valproic acid in the psychiatric setting. *Am J Psychiatry* 2007;164:1020–7.
- 7 Lheureux PE, Penalzoa A, Zahir S, Gris M. Science review: Carnitine in the treatment of valproic acid induced toxicity - what is the evidence? *Crit Care* 2005;9:431–40.
- 8 Wu J, Li J, Jing W, Tian X, Wang X. Valproic acid-induced encephalopathy: A review of clinical features, risk factors, diagnosis, and treatment. *Epilepsy Behav* 2021;120:107967.
- 9 Rose C, Michalak A, Rao KV *et al*. L-Ornithine-L-aspartate lowers plasma and cerebrospinal fluid ammonia and prevents brain edema in rats with acute liver failure. *Hepatology* 1999;30:636–40.
- 10 Duman B, Can KC, Ağtaş-Ertan E *et al*. Risk factors for valproic acid induced hyperammonemia and its association with cognitive functions. *Gen Hosp Psychiatry* 2019;59:67–72.

**Address for correspondence: Yong Fang, NO.161, West 5rd, Xincheng District, Xi'an Shaanxi, 710003, PR China.  
Email: yfong1010@163.com**