

Locked-in syndrome associated with ocular bobbing

C. C. Tijssen, J. P. Ter Bruggen

Department of Neurology, St. Elisabeth and Maria Hospitals, Tilburg, The Netherlands

ABSTRACT — Locked-in syndrome together with an ocular bobbing phenomenon was observed in a 41-year-old man, an association which has not been reported earlier. Computerized tomography demonstrated an infarction of the medio-ventral portion of the pons. The patient survived and is still alive ten months after the onset of the disease with severe neurological deficit.

Accepted for publication October 9, 1985.

The locked-in syndrome (LIS) is a rare clinical condition consisting of paralysis of all four extremities and the lower cranial nerves without interference with consciousness. The only remaining voluntary movements are blinks of the eyelid, which allow the patient to communicate, and vertical eye movements (1,2). Most cases are caused by a large ventral infarction of the pontine base.

Ocular bobbing is a distinctive abnormality of eye movements characterized by abrupt, spontaneous, usually conjugate, downward jerks of both eyes followed by a slow return to the midposition. There is paralysis of spontaneous and reflex eye movements in the horizontal plane. The patient may be comatose, obtunded or fully conscious (1,3). The syndrome has been most often associated with extensive destructive lesions of the pons. It can also occasionally occur in pontine dysfunction resulting from brainstem compression and metabolic encephalopathy (4,5).

We describe a patient with (LIS) caused by an infarction of the brainstem, who also showed the phenomenon of typical ocular bobbing, an association which has not been reported earlier.

Case report

A 41-year-old man was admitted to hospital with symptoms of acute headaches, facial numbness, disturbances of speech and difficulty in walking. He had noticed a right facial paresis and a right hemiparesis. Three weeks earlier he had experienced the same complaints which had disappeared spontaneously within a few hours. There was a history of mild hypertension.

On examination he was conscious and had a blood pressure of 200/120. His speech was dysarthric and he had a conjugate deviation of gaze to the right. There was a right hemiparesis and hemihypaesthesia. Deep tendon reflexes were elevated on the right with a positive Babinski sign. In the first days following admission his condition deteriorated seriously with temporary Cheyne-Stokes breathing. He developed bilateral hemiplegia. His pupils were miotic but reactive to light. The corneal reflexes were absent. The patient remained conscious and was able to blink his eyelids. No other voluntary movements were possible. His eyes showed a typical ocular bobbing with spontaneous downward jerking and slow return to the mid-position. This was measured by oculographic recording (Fig. 1). Horizontal eye movements were not possible, with absent oculovestibular responses. Nor did they occur on caloric stimulation.

The EEG repeatedly showed no abnormalities. The cerebrospinal fluid showed 35/3 cells/mm³ and an elevated total protein of 0.82 g/l (normal until 0.50). CT scan on the day of admission was normal. A repeat CT scan, three weeks later, showed an infarction in the medio-ventral part of the pons with extension somewhat more to the left than to the right (Fig. 2). Registration of the blink reflex with electrical stimulation of the supra-orbital nerve showed first responses with normal latencies. The second responses were absent on both sides. The brainstem auditory evoked potentials (BAEP) revealed wave I and II with normal latencies on right and left stimulation. Wave III to V could not be elicited. The short latency somatosensory evoked potentials (SSEP) showed a normale wave pattern (P9,

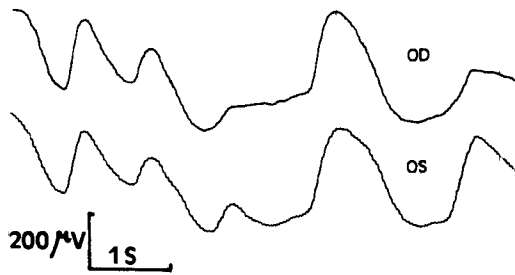


Fig. 1. Oculographic recording of the ocular bobbing phenomenon of the patient showing the abrupt, arrhythmic, conjugate downward jerks of both eyes followed by a slow return to the midposition (AC amplifier, time constant 10 S)

↓: downward movement of the eyes from mid-position.
↑: upward movement of the eyes to mid-position.

N11, N13/P13, P14, N19, P22) on stimulation of the left median nerve. On stimulation of the right median nerve the P14, N19 and P22, could not be elicited.

The patient was treated with anticoagulant therapy, regulation of blood pressure, tracheostoma, gastrostoma and suprapubic urinary drainage. Eight weeks after admission the condition had stabilized and the following months a slight improvement of the neurological findings occurred. The patient was able to communicate by blinking his eyelids. The ocular bobbing phenomenon persisted for two months and then gradually disappeared. Intermittent oral automatisms consisting of sucking and chewing movements were present and could be evoked by noxious stimuli. There was a slight voluntary movement of the head, but otherwise quadriplegia persisted. In this state the patient was referred to a nursing home, six months after admission. Four months later he was still alive and there was no significant change in his neurological condition.

Discussion

The LIS syndrome results from disruption of the corticospinal tract and the corticobulbar fibres to the lower cranial nerve nuclei (1,2). The blink reflex of our patient elicited by stimulation of the supra-orbital nerve showed a first response with normal latencies on both sides, indicating that the facial nuclei were intact. The presence of oral automatisms which could be evoked by noxious stimulation suggests that the bulbar system of mastication was also intact (6).

The vertical eye movements are generally described as normal in patients with LIS, due to sparing of the tegmental corticobulbar tracts that innervate the third nerve nuclei (1). A dissociated loss of vertical eye movements with slowed saccades and normal pursuit movements has also however been found in a patient with LIS (7). Our patient demonstrated a typical ocular bobbing phenomenon in combination with LIS. This was caused by a large infarction of the medio-ventral part of the pons as demonstrated by computerized tomography. Ocular bobbing is most frequently seen in severe destructive caudal pontine lesions, the result of either infarction or hemorrhage (1,3). The pathophysiologic mechanism underlying this eye movement remains obscure (3). It has been postulated that the phenomenon is caused by selective involvement of the pathways for horizontal gaze while more rostral input for vertical gaze is retained (9). Others, however, have attributed it to neural activity originating in the intact medulla and suggest that bobbing is the result of normal pathways for downgaze (10). The clinical symptoms and the absence of the second responses of the blink reflex in our patient are in favour of the first hypothesis.

Studies of evoked potentials have been rarely reported in patients with LIS and ocular bobbing. Different findings of BAEP's have been described in patients with LIS; these can be normal or show abnormalities of wave IV and V (8). Our patient had normal peak latencies of wave I and II but the other wave forms could not be elicited, indicating that the brainstem damage extended beyond the pontine base and included the

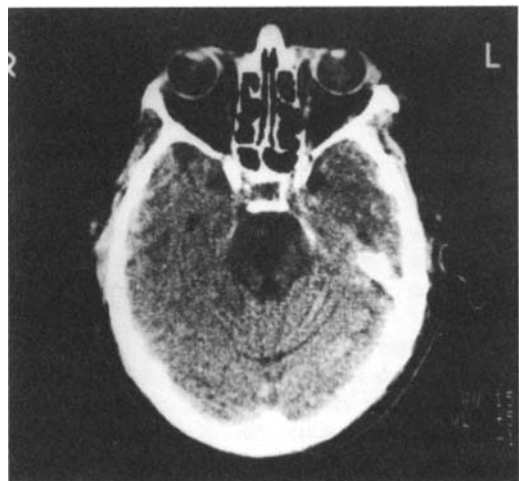

Fig. 2. CT scan of the patient showing a large infarction of the medio-ventral part of the pons.

pontine tegmen (11). The SSEPs demonstrated a disturbance at the level of the left medial lemniscus on stimulation of the right median nerve corresponding to the initial right hemi-hypaesthesia (12); the SSEPs on stimulation of the left median nerve were completely normal.

The prognosis of both LIS and ocular bobbing of vascular origin is poor, most patients dying within a few weeks of onset (1,2,3). Our patient however survived and is still alive ten months later with severe neurological deficit.

References

1. Plum F, Posner J B. The diagnosis of stupor and coma. Philadelphia: F A Davis Co, 1982.
2. Virgile R S. Locked-in syndrome. *Clin Neurol Neurosurg* 1984;86:275-279.
3. Susac J O, Hoyt W F, Daroff R B, Lawrence W. Clinical spectrum of ocular bobbing. *J Neurol Neurosurg Psychiat* 1970;33:771-775.
4. Bosch E P, Kennedy S S, Aschenbrener C A. Ocular bobbing: The myth of its localizing value. *Neurology* 1975;25:949-953.
5. Drake M E, Erwin C W, Massey E W. Ocular bobbing in metabolic encephalopathy: clinical, pathologic, and electrophysiologic study. *Neurology* 1982;32:1029-1031.
6. Bauer G, Prugger M, Rimpl E. Stimulus evoked oral automatisms in the locked-in syndrome. *Arch Neurology* 1982;39:435-436.
7. Larmande P, Hénin D, Jan M, Elie A, Gouazé A. Abnormal vertical eye movements in the locked-in syndrome. *Ann Neurol* 1982;11:100-102.
8. Seales D M, Torkelson R D, Shuman R M, Rossiter V S, Spencer J D. Abnormal brainstem auditory evoked potentials and neuropathology in "locked-in" syndrome. *Neurology* 1981;31:893-896.
9. Nelson J R, Johnston C H. Ocular bobbing. *Arch Neurol* 1970;22:348-356.
10. Newman N, Gay A J, Heilbrun M P. Disjugate ocular bobbing: its relationship to midbrain, pontine, and medullary function in a surviving patient. *Neurology* 1971;21:633-637.
11. Chiappa K H, Ropper A H. Evoked potentials in clinical medicine (Part I) *N Engl J Med* 1982;306:1140-1150.
12. Chiappa K H, Ropper A H. Evoked potentials in clinical medicine (Part II) *N Engl J Med* 1982;306:1205-1211.

Address

C. C. Tijssen, M.D.
Department of Neurology
St. Elisabeth and Maria Hospital
P.O. Box 90151
5000 LC Tilburg
The Netherlands