

CASE REPORT

cerebellar hemorrhage, cysticercosis, central nervous system
cysticercosis, central nervous system, cerebellar hemorrhage

Central Nervous System Cysticercosis Simulating an Acute Cerebellar Hemorrhage

*We report the case of a Mexican man who suddenly developed severe occipital headache, vomiting, vertigo, and ataxia. Neurologic examination showed nystagmus and cerebellar findings. Computed tomography of the brain demonstrated a large left cerebellar cystic lesion consistent with the diagnosis of cysticercosis. The patient was treated with dexamethasone and praziquantel and required surgical removal of the lesion to prevent herniation. He recovered without neurologic sequelae. The abrupt onset of cerebellar findings is an unusual presentation of this disease. Central nervous system cysticercosis is being recognized with increasing frequency in the United States, where it is found primarily in Hispanic and Asian immigrants. The literature of central nervous system cysticercosis is reviewed and the pathogenesis, clinical presentation, and therapy are discussed. [Catapano MS, Marx JA: Central nervous system cysticercosis simulating an acute cerebellar hemorrhage. *Ann Emerg Med* July 1986;15:847-849.]*

INTRODUCTION

Infestation of the central nervous system with *Cysticercus cellulosae*, the larval form of the pork tapeworm, *Taenia solium*, is a prevalent worldwide disease.¹⁻⁵ CNS cysticercosis presents with seizures, symptoms of increased intracranial pressure, focal neurologic deficits, neuropsychiatric disorders, or visual difficulties. The disease generally follows a chronic course but may present with the sudden onset of symptoms.⁵⁻¹⁰

In this report we present a patient who abruptly developed the signs and symptoms of a cerebellar mass.

CASE REPORT

A 58-year-old Hispanic man presented with a three-hour history of severe occipital headache, nausea, vomiting, vertigo, and difficulty walking because of loss of balance. He had a ten-year history of mild occipital headaches, but these never were associated with other symptoms and did not require medical attention. He had a four-year history of hypertension and was treated with a diuretic. There was no history of intestinal tapeworm infestation. He was born in Mexico and immigrated to Colorado 13 years prior to admission.

Physical examination showed a well-developed Hispanic man. The vital signs were as follows: blood pressure, 130/88 mm Hg; pulse, 84; respiratory rate, 20; and oral temperature, 36.7 C. There were no palpable subcutaneous nodules. The mental status was normal. Cranial nerves were normal. Strength was normal; deep tendon reflexes were 2+ and symmetric; and the plantar responses were flexor. Sensory examination was normal. There was left horizontal nystagmus with leftward gaze. Truncal ataxia was present and there was mild abnormality on left finger to nose testing. The patient had an ataxic gait with tendency to fall to the left. The remainder of the examination was normal.

The hemoglobin was 16 mg/dL, hematocrit was 48%, and the white blood cell count was 13,000/mm³ with 96% polymorphonuclear cells, 4% lymphocytes, and no eosinophils. The urinalysis was normal. The electrolytes, BUN, and glucose were normal. Examination of the stools showed no ova or parasites. Radiographic examination of the thighs showed no soft tissue calcification. Computed tomography of the brain demonstrated a large, left cerebellar cystic lesion with calcification internally and ring enhancement. In addition,

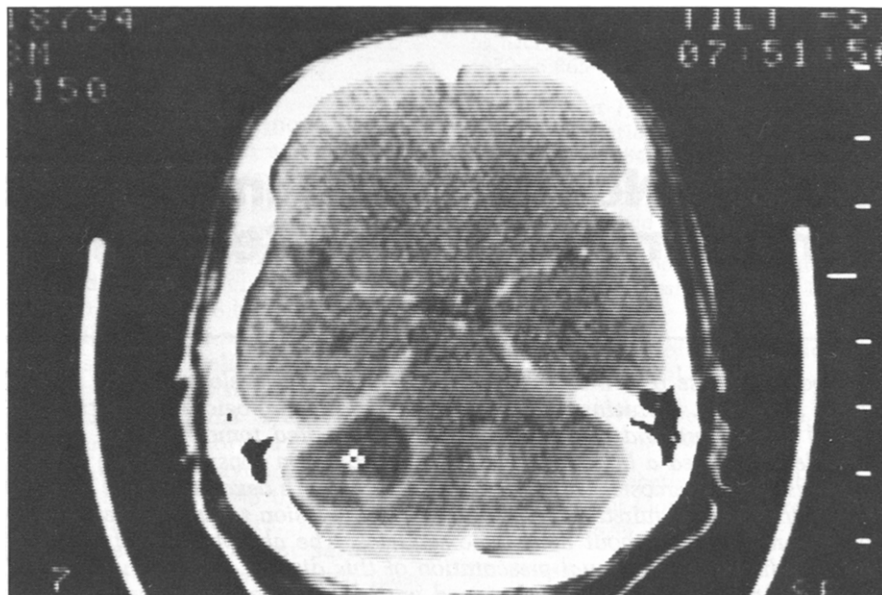
Michael S Catapano, MD*
John A Marx, MD†
Denver, Colorado

From the Denver General Hospital Residency* and the Department of Emergency Medicine,† Denver General Hospital, Denver, Colorado.

Received for publication September 3, 1985. Revision received December 12, 1985. Accepted for publication January 7, 1986.

Address for reprints: John A Marx, MD, Department of Emergency Medicine, Denver General Hospital, 777 Bannock Street, Denver, Colorado 80204.

FIGURE. Note large ring-enhancing cystic mass in left cerebellum (with central marker) and two smaller non-enhancing cystic lesions in the left temporal cortex.



there were two small cystic lesions in the left temporal cortex (Figure). There was mass effect and obliteration of the fourth ventricle. Plain films of the skull and thighs revealed no calcification.

The patient was treated with high-dose dexamethasone 40 mg/day and praziquantel 1,200 mg orally every eight hours. He exhibited minimal improvement and surgery was deemed necessary to avoid herniation. On the fourth hospital day, a posterior fossa craniotomy was performed and the left cerebellar lesion was removed. Pathologic examination demonstrated the larval form of the pork tapeworm, *Taenia solium*. The hospital course was complicated by a pulmonary embolism, which resolved without sequelae. The patient improved steadily and was discharged on the 18th hospital day with no neurologic deficits and on no medications. The patient was doing well at followup one month later.

DISCUSSION

Human beings can serve as both the definitive and intermediate host for the pork tapeworm *Taenia solium*.¹¹ Intestinal infestation is acquired by ingesting undercooked pork containing the larval form, *Cysticercus cellulosae*. The larvae attaches to the intestine and develops into the adult tapeworm. The adult tapeworm consists of numerous segments, or proglottids. The terminal, egg-bearing proglottids occasionally separate and are discharged in the feces. Under the poor hygiene conditions existing in developing countries, both pigs and human beings can ingest ova in contaminated food and water. Embryos are released in the gastrointestinal tract, penetrate the intestines, and are eventually deposited in tissues, with a preference for muscle, subcutaneous tissue, and brain. Within 60 to 70 days embryos develop into larvae, or cysticerci, thus completing the life cycle.

Most patients with CNS cysticercosis are between the ages of 20 and 50, although no age is exempt.^{3,4,9,10,12-15} No significant differences ap-

pear to exist among races or the sexes.

CNS cysticerci cause illness through three major pathophysiologic mechanisms. Occasionally, a single cyst is large enough to cause signs and symptoms of a cerebral tumor.^{3,5,7,9,10} More often, the parasites obstruct the flow of cerebrospinal fluid (CSF) and cause either a communicating hydrocephalus from chronic meningitis or an obstructive hydrocephalus from ventricular involvement.^{3,5,7,9,10} In the third, or parenchymatous form, the cysts are numerous and produce diffuse cerebral swelling. A patient may exhibit a combination of these three types.^{3,5,16}

The clinical presentation of CNS cysticercosis is nonspecific and varied and depends on the number of cysticerci present and their location.^{3-10,15,17} Seizures, both focal and generalized, are common and occur in 30% to 92% of patients.^{2,5,8,9} Symptoms of increased intracranial pressure occur frequently and include nausea, vomiting, altered mental status, and headache. Psychosis, dementia, and impaired memory also have been reported.⁵ A wide variety of focal neurologic deficits, sometimes mimicking stroke or tumor, have been described. Invasion of the eye with cysts can produce visual abnormalities.^{2,5,8,9} CNS cysticercosis may be accompanied by painless nodules in striated muscle and subcutaneous tissue. The time from exposure to the first symptoms can be less than one year or as many as 30 years with 83% exhibiting symptoms within seven years.⁵ Man-

ifestations can develop insidiously but frequently present suddenly.⁵⁻¹⁰

Cerebellar cysts occur in up to 18% of autopsy cases⁵ but symptomatic cerebellar cysts are uncommon.⁹ Patients with symptoms of headache, vomiting, ataxia, vertigo, and nystagmus have been reported but the etiology usually has been hydrocephalus caused by disruption of the flow of CSF.^{3,5,7,10,18-21} Dixon and Lipscomb describe nine patients with this symptomatology.⁵ The causes were basilar meningeal involvement or obstruction of the fourth ventricle. Cerebellar pathology was not found. There was no evidence of hydrocephalus or basal meningitis in our patient.

Laboratory evaluation provides limited diagnostic information. A mild peripheral leukocytosis can be seen in as many as one-third of patients.^{8,9} Peripheral eosinophilia has been reported to occur in 3% to 35% of cases.^{6,8-10} Examination of the stool rarely reveals ova or parasites.^{9,10} The CSF frequently is abnormal. Elevated protein, depressed glucose, or pleocytosis occur in approximately 80% of patients with CNS cysticercosis.^{3,4,8-10} When Wright stains are performed on the CSF, eosinophilia is more evident, and in one report had an incidence of 29%.³ Serologic testing of the serum and CSF, using the indirect hemagglutination test, is positive in 60% to 100% of patients and frequently is the most important diagnostic information.^{8-10,18}

Radiographic examination often

will demonstrate evidence of cysticercosis and frequently will be diagnostic. Calcified cysticerci in soft tissue have been discovered on plain films in as many as 98% of patients,⁵ although more recent studies have found a lower incidence of soft tissue calcifications.^{9,10} Intracranial calcifications seen on skull radiographs strongly suggest the diagnosis of cerebral cysticercosis and occur in about 24% of patients.⁵

Computed tomography of the brain in patients with CNS cysticercosis exhibits several patterns and often is most helpful in achieving a diagnosis. The most frequent, and diagnostic, appearance on CT is multiple, small intraparenchymal calcifications.^{9,10,13,14} The second most common finding is circular, cystic lesions in the brain parenchyma.^{9,10,13,14} Other pathology on CT includes hydrocephalus, ventricular cysts, ring enhancement of cystic lesions when IV contrast is given, solid lesions, and lesions seen only with contrast enhancement. The CT may be normal.^{9,10,13,14} Air contrast studies will assist in the surgical management of selected patients by defining the intraventricular and subarachnoid spaces.^{10,13,22}

Treatment consists of therapy with praziquantel and dexamethasone, seizure control with conventional anti-convulsants, and surgery. Praziquantel is a broad-spectrum antihelminthic agent, and, when combined with steroid treatment, appears to reduce the morbidity and mortality associated with CNS cysticercosis.²³⁻²⁵ Surgery should be reserved for patients with hydrocephalus (decompressive procedures) and large symptomatic cysts. Operative mortality has been reported to be as high as 32%^{3,4} but more recent studies report no operative mortality.^{9,10}

SUMMARY

CNS cysticercosis has not been re-

ported previously in the emergency medicine literature. If immigration to the United States increases, however, CNS cysticercosis may become more prevalent. This disorder should be considered in Hispanic or Asian immigrants who present with seizures, focal neurologic deficits, symptoms of increased intracranial pressure, neuropsychiatric disorders, or visual abnormalities.

REFERENCES

- Nash TE, Neva FA: Recent advances in the diagnosis and treatment of cerebral cysticercosis. *N Engl J Med* 1984;34:1492-1496.
- Olive JI, Angulo-Rivero P: Cysticercosis of the nervous system. I. Introduction and general aspects. *J Neurosurg* 1962;19:632-634.
- Stepien L: Cerebral cysticercosis in Poland. *J Neurosurg* 1962;19:505-513.
- Lombardo L, Mateos HJ: Cerebral cysticercosis in Mexico. 1961; *Neurol* 11:824-828.
- Dixon HBF, Lipscomb FM: Cysticercosis: An analysis and follow-up of 450 cases. *Med Res Counc Spec Rep Ser* 1961;299:1-57.
- Latovitchi N, Abrams G, Clark C, et al: Cerebral cysticercosis. *Neurology* 1978;28:838-842.
- Shanley JD, Jordan MC: Clinical aspects of CNS cysticercosis. *Arch Intern Med* 1980;140:1309-1313.
- Grisolia JS, Wiederholt WC: CNS cysticercosis. *Arch Neurol* 1982;39:540-544.
- McCormick GF, Chi-Shing Zee, Heiden J, et al: Cysticercosis cerebri. Review of 127 cases. *Arch Neurol* 1982;39:534-539.
- Leo L, Braude A: Cerebral cysticercosis in San Diego. *Medicine* 1982;61:341-359.
- Mandel E (ed): *Principles and Practice of Infectious Disease*. New York, John Wiley and Sons, 1979, pp 1283-1287.
- Goni PB: Cysticercosis of the nervous system. III Clinical findings and treatment. *J Neurosurg* 1962;19:641-643.
- Byrd SE, Locke GE, Biggers S, et al: The computed tomographic appearance of cerebral cysticercosis in adults and children. *Radiology* 1982;144:819-823.
- Carbajal JR, Palacios E, Azar-Kia B, et al: Radiology of cysticercosis of the central nervous system including computed tomography. *Radiology* 1977;125:127-131.
- Sotelo J, Guerro V, Rubio E, et al: Neurocysticercosis: A new classification based on active and inactive forms. *Arch Intern Med* 1985;145:442-445.
- Cardenas JC: Cysticercosis of the nervous system II. Pathologic and radiologic findings. *Neurosurgery* 1962;19:635-640.
- Dixon HBF, Hargreaves WH: Cysticercosis — A further ten years clinical study, covering 284 cases. *Q J Med* 1944;13:107-121.
- Nieto D: Cysticercosis of the nervous system: Diagnosis by means of the spinal fluid complement fixation test. *Neurology* 1956;6:725-737.
- Bickerstaff ER, Cloake PC, Hughes B, et al: The racemose form of cerebral cysticercosis. *Brain* 1952;75:1-18.
- Arseni C, Samitca DC: Cysticercosis of the brain. *Br Med J* 1957;2:494-497.
- Bickerstaff ER: Cerebral cysticercosis — common but unfamiliar manifestations. *Br Med J* 1955;1:1055-1058.
- Stern WE: Neurosurgical consideration of cerebral cysticercosis. *J Neurosurg* 1981;55:382-389.
- Pearson RD, Guerant RL: Praziquantel: A major advance in anthelmintic therapy. *Ann Intern Med* 1983;99:195-198.
- de Ghetaldi LD, Norman RM, Douville AW, et al: Cerebral cysticercosis treated biphasically with dexamethasone and praziquantel. *Ann Intern Med* 1983;99:179-181.
- Sotelo J, Escobedo F, Carbajal JR, et al: Therapy of parenchymal brain cysticercosis with praziquantel. *N Engl J Med* 1984;310:1001-1007.