

Active management of the unconscious eclamptic patient

A. M. RICHARDS, J. MOODLEY *Consultant Obstetricians and Gynaecologists, Department of Obstetrics and Gynaecology, University of Natal, Durban, South Africa*
D. I. GRAHAM *Professor of Neuropathology, Department of Neuropathology, Institute for Neurological Sciences, Southern General Hospital, Glasgow, UK &*
M. R. R. BULLOCK *Consultant Neurosurgeon, Department of Neurosurgery, University of Natal, Durban, South Africa*

Summary. Of the many complications which may develop after eclamptic seizures, prolonged unconsciousness is one of the most difficult for obstetricians to manage as the pathophysiology of this condition remains largely unknown. Computed axial tomography (CT scan) was performed on 20 unconscious eclamptic patients, and autopsy was obtained on an additional two patients. Changes compatible with cerebral oedema were demonstrated in 75% of patients; cerebral haemorrhage occurred in 9%. A programme of intensive neurological management aimed at optimizing cerebral perfusion and controlling intracranial pressure is outlined. We have reduced the mortality rate for unconscious eclamptic patients from 50% to 17% in our institution.

Eclampsia still ranks as one of the most frequent causes of maternal death throughout the world, although improvement in antenatal care has reduced its incidence in Western countries (Augensen & Bergsjø 1984; Gibbs & Locke 1976).

In South Africa, as in many developing countries, eclampsia remains a common occurrence. Figures from King Edward VIII Hospital, University of Natal (1983) indicate the development of eclampsia in approximately 9 out of every 1000 deliveries. Between 5 and 10% of patients with eclampsia die from the disease process. Cerebral dysfunction, renal failure and pulmonary oedema are the most common terminal events (Donnelly *et al.* 1954).

Cerebral dysfunction, as manifest by a decreased conscious level, occurs in the majority

of patients with eclampsia for a variable period after seizures. Where cerebral dysfunction has been cited as the cause of death, post-mortem studies (Melrose 1984; Sheehan & Lynch 1973) have revealed intracerebral haemorrhage in up to 60% of patients, but the incidence of cerebral haemorrhage in non-fatal eclampsia (Beck & Menezes 1981) and the related pathophysiology (Souter 1980) remains unknown.

The advent of computed axial tomography (CT) scan has facilitated the study of living eclamptic patients with cerebral dysfunction, and several reports (Beeson & Duda 1981; Benedetti & Quilligan 1980; Drayer & Rosenbaum 1976) have documented CT scan appearances suggestive of cerebral oedema. Intracerebral haemorrhage appears to be a less frequent finding (Melrose 1984).

A programme of intensive neurological management was devised at King Edward VIII Hospital in an attempt to improve the outcome for the many eclamptic patients treated annually. This programme includes CT scanning

Correspondence: Dr A. M. Richards, Department of Obstetrics and Gynaecology, University of Natal, Faculty of Medicine, PO Box 17039, 4013 Congella, Durban, South Africa.

and intracranial pressure monitoring where indicated.

The purpose of this paper is to describe the CT scan changes found in these patients in relation to intracranial pressure recordings, and to suggest a management protocol aimed at reducing intracranial pressure and optimizing cerebral perfusion.

Patients and methods

A total of 192 patients with eclampsia was seen at King Edward VIII Hospital over the study period of 14 months (1 July 1983 to 30 September 1984). During this time approximately 19 000 deliveries were performed at this hospital.

All eclamptic patients were managed according to a standardized protocol (Moodley *et al.* 1984). Convulsions were immediately controlled with magnesium sulphate and blood pressure was lowered to a diastolic of between 100 and 105 mmHg with intravenous dihydralazine given in small doses. Dexamethazone was used routinely for the initial 24 h, in the belief that this may reduce cerebral oedema.

Central venous and radial artery pressures were monitored in all patients and endotracheal intubation was undertaken when required to secure an adequate airway, oxygen therapy and frequent arterial blood gas determinations were performed to prevent cerebral hypoxia. Termination of pregnancy was achieved by caesarean section, if vaginal delivery was not imminent within 4–6 h of admission. Urgent delivery was a management priority in comatose patients.

Patients remaining unconscious 6 h post-delivery and those with localizing neurological signs, underwent CT scanning. Intracranial pressure monitoring was then performed in patients with severe brain oedema on CT scan, where the Glasgow coma scale was 9/15 or less (i.e. those patients who are unable to open eyes, obey commands or speak) (Teasdale & Jennett 1974). A GE8800 CT scanner was used and intracranial pressure was monitored through a ventricular or subdural catheter via a Statham P50 transducer connected to a continuous bedside recording system.

High intracranial pressure was managed according to a fixed protocol as follows. All patients were nursed in a neurosurgical intensive care unit in the semi-sitting position (30°) to minimize intracranial venous pressure. When

high intracranial pressure persisted a 20% mannitol infusion (0.5 g/kg) was employed, followed by hyperventilation to reduce arterial P_{CO_2} levels (P_{CO_2} 28 ± 5 mmHg). Where these measures failed an infusion of Althesin was commenced at 24 μ g/kg/min. This was then titrated against intracranial pressure in an attempt to maintain optimal cerebral perfusion pressures. Intermittent drainage of CSF in 5-ml aliquots was used in two patients. Althesin (alphaxalone-alphadolone), a steroidal short-acting anaesthetic induction agent, has since been withdrawn from generalized usage, because of hypersensitivity reactions reported in 1 in 1000 patients (Evans & Keogh 1977). Its value in reducing high intracranial pressure has been confirmed by several authors (Stewart *et al.* 1983; McIlhany *et al.* 1983).

The illustrative case histories of two patients are presented below.

Patient no. 1

Miss N.N., a 20-year-old unbooked primigravid patient at approximately 26 weeks gestation, was admitted via a peripheral clinic to a district Mission Hospital, with a history of generalized convulsions. A diagnosis of eclampsia was made on a blood pressure recording of 170/140 mmHg, mean arterial pressure (MAP) of 150 mmHg and gross proteinuria. Intravenous diazepam was administered and transfer arranged.

On arrival at the referral hospital it was estimated that the patient had been fitting intermittently for 18 h. The fetal heart was not detected and the fetus was felt to be severely growth-retarded. There was minimal response to painful stimuli with flaccidity of all four limbs and no localizing neurological signs. She had evidence of early aspiration pneumonia, and gross generalized oedema.

Control of convulsions with magnesium sulphate and lowering of the blood pressure was undertaken. Following a hysterotomy, the patient was electively ventilated for 4 h.

Examination at this stage revealed no change in her level of consciousness, estimated at Glasgow coma scale 4/15. Her blood gases were normal, haemoglobin 9.5 g/l, white cell count 25 000 and crude clotting time 5 min. There was evidence of renal failure in that her serum potassium was 6.8 mmol/l and urea 12.6 mmol/l, with minimal urine output in response to i.v. frusemide.

A CT scan was performed and this revealed diffuse white matter low density consistent with vasogenic cerebral oedema (Fig. 1). The basal cisterns were visible at this stage.

An intracranial pressure monitor revealed an

initial pressure of 43 mmHg (normal 10–15 mmHg). Mannitol infusion (0.5 g/kg) and hyperventilation were commenced.

A clotting profile revealed elevated fibrinogen degradation products with low haemoglobin and

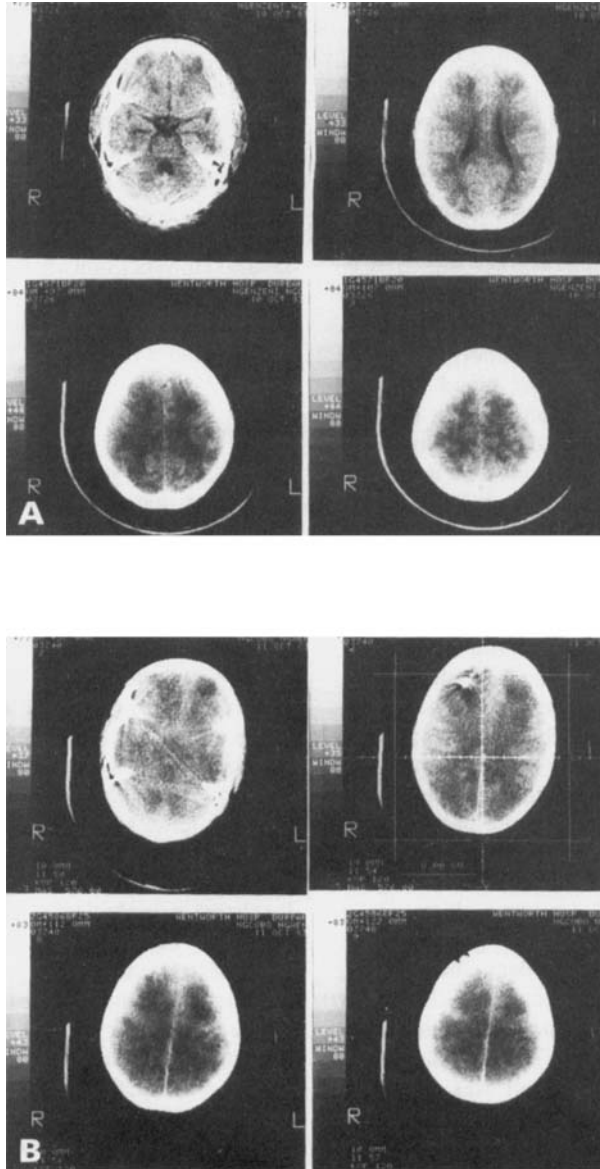


Fig. 1. (a) Scan series of patient no. 1 (N.N.) performed 8 h after caesarean section for eclampsia. Widely patent basal cisterns are noted in cut 2, and moderate diffuse white matter oedema is seen. (b) CT scan series performed in patient no. 1 (N.N.) 48 h later. Note complete effacement of basal cisterns in cut 2, and gross progression of brain oedema.

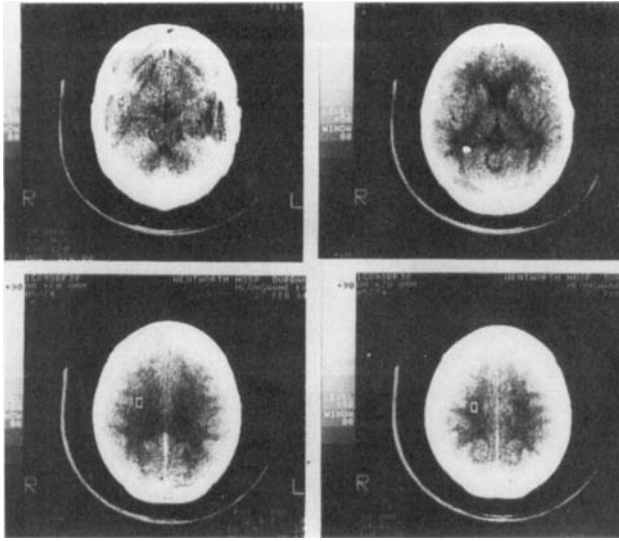


Fig. 2. CT scan series of patient no. 2. (K.H.) demonstrating 'watershed' pattern brain oedema. Basal cisterns are uneffaced. Low density areas involve the white matter of the temporo-parietal-parieto-occipital and high parietal regions.

platelet levels, suggestive of a consumptive coagulopathy.

Over the next 12 h intracranial pressure rose to reach levels around 60 mmHg in spite of large doses of diuretics, steroids, mannitol and subsequently an Althesin infusion. A repeat CT scan revealed massive progression of cerebral oedema with obliteration of basal cisterns (Fig. 1).

Shortly afterwards the patient developed fixed dilated pupils and her blood pressure dropped to 100/60 mmHg (MAP 73). A simultaneous fall in intracranial pressure was noted. Twelve hours later formal testing for brain function revealed the patient to be brain dead. Ventilation was therefore discontinued.

Post-mortem revealed haemorrhages in the liver and adrenal medulla, pulmonary oedema and a soft swollen brain with signs of uncal transtentorial herniation (coning). Neurohistology revealed fibrinoid arterial wall necrosis, perivascular microinfarcts and brain oedema. Widespread hypoxic/ischaemic neuronal damage was found.

Patient no. 2.

Mrs K.H., a 37-year-old para 7, gravidity 8, was delivered vaginally at home of a normal healthy

male infant weighing 3.1 kg. Shortly afterwards she became confused and developed seizures.

The patient was admitted to hospital within 2 h of delivery. On admission her blood pressure was 160/110 mmHg (MAP 126) and moderate proteinuria was demonstrated. She did not obey commands, and her Glasgow coma scale was 8/15.

Routine anticonvulsant and hypotensive therapy was commenced and the patient was referred for CT scanning which revealed patchy areas of low density indicative of white matter oedema (Fig. 2). Following insertion of an intraventricular pressure monitor the pressure was found to be 25 mmHg. This rapidly rose to 50 mmHg. A right hemiparesis was present. Steroids, mannitol, Althesin infusion and intermittent cerebrospinal fluid aspirations were carried out to control intracranial pressure.

On the third day after delivery, the intracranial pressure began to settle to normal levels and spontaneous eye opening occurred, but during the course of the afternoon the intracranial pressure suddenly rose again. A repeat CT scan showed progression of the cerebral oedema.

Over the following 24 h the patient's level of consciousness improved with spontaneous eye opening and movement. The intracranial pressure fell rapidly to near normal levels, and there

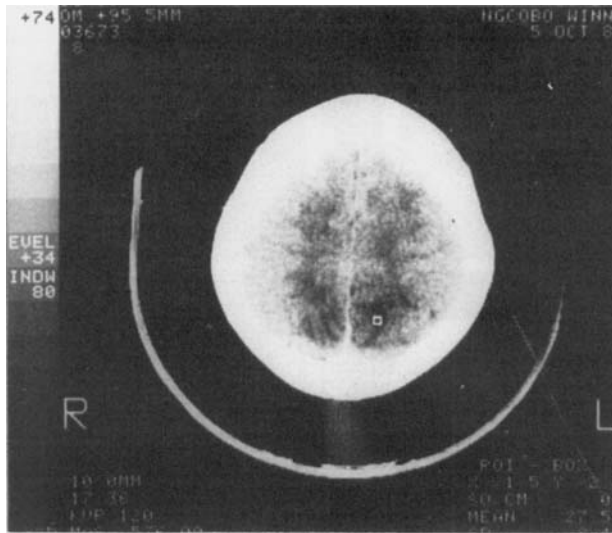


Fig. 3. Occipital oedema.

was no evidence of the previously recorded right sided weakness. The patient was extubated and discharged from the intensive care unit.

A 6-week follow-up visit revealed normal blood pressure, renal function and neurological status. A tubal ligation was advised.

Results

Clinical features

Twenty-two eclamptic patients remained in coma 6 h or more following delivery, two of these patients died before inter-hospital transfer

Table 1. Clinical features in 22 patients in coma after eclampsia

Clinical variable	Mean	(Range)
Age (years)	21.3	(15–37)
Gestation at onset of seizures (weeks)	36	(30–40)
Parity		(0–7)*
Glasgow coma scale	6	(3–9)
Time taken for seizure control (h)	5.6	(0.3–20)
Blood pressure on first hospital admission (mmHg)	166/110	(130/90–210/128)
Mean arterial pressure (mmHg)	128	(103–141)

*Eighteen patients were in their first pregnancy.

for CT scan. The clinical features of these 22 patients are outlined in Table 1. Most were young primigravida around 36 weeks gestation; the majority were unbooked or had received minimal antenatal care before their first presentation with seizures. Average blood pressure for the group measured at the time of first hospital admission was 166/110 mmHg (MAP 129). The interval between the first and last seizure ranged from 25 min to 20 h and reflects the long and often slow referral chain which operates in certain rural areas in Natal, which may be up to 300 km from King Edward VIII Hospital. This interval was significantly correlated with the severity of changes on CT scan (Table 2). The most marked CT changes were seen in those patients with the longest duration of seizures. Five patients died, two of whom were found to have an intracerebral haemorrhage (Table 3).

CT scan features

Twenty patients underwent CT scanning (Table 2). In five patients CT scan appearances were regarded as normal. A brain stem haemorrhage was diagnosed in one patient. The remaining patients all demonstrated CT scan low density areas interpreted as cerebral oedema of varying degrees.

'Diffuse white matter oedema' (Fig. 1a, b). Five patients demonstrated a low density pattern diffusely distributed throughout the white

Table 2. CT scan data in 20 patients in coma after eclampsia

	CT scan appearance				
	'Diffuse white matter oedema'	'Watershed pattern oedema'	'Occipital white matter oedema'	Normal	Brainstem haemorrhage
Number of patients	5	4	5	5	1
Basal cistern effacement	4	0	1	0	1
Intracranial pressure					
High	3	1	—	—	—
Low	1	—	—	—	—
(No. monitored)	(4)	(1)			
Mean period before control of seizures (h)	9.4*	6.3	3.0	0.8	5

High intracranial pressure, greater than 20 mmHg for >2 h.

*Significantly prolonged when compared to normal CT patients. $P < 0.05$. *Kruskal-Wallis test and Dunn's multiple comparison procedure for paired groups.

matter. This was regarded as the most severe form of oedema in that the majority of these patients showed associated basal cistern effacement which may indicate raised intracranial pressure (Teasdale *et al.* 1984). In addition, three of the four patients in this group, who underwent intracranial pressure monitoring, were found to have significantly raised pressure.

'Watershed oedema' (Fig. 2). A further four patients demonstrated the so-called watershed pattern oedema, maximal between middle cerebral and posterior cerebral artery distribution territories. The one patient in this group who underwent intracranial pressure monitoring was found to have high pressure.

Table 3. Details of the five patients who died

Patient	Cause of death
N.N.	Gross cerebral oedema, high ICP and renal failure
D.Z.	Intra-pontine bleed (demonstrated on CT scan)
T.N.	Died before CT scan, autopsy revealed oedematous brain with severe ischaemic/hypoxic neuronal damage
P.B.	Occipital oedema, recovered consciousness, but died from adult respiratory distress syndrome and renal failure
H.S.	Died before CT scan, autopsy revealed a large frontal intracerebral haematoma

'Occipital oedema' (Fig. 3). In the remaining five patients small patchy areas of low density were noted in the white matter of the occipital region.

Intracranial pressure monitoring.

Of the five patients who underwent intracranial pressure monitoring, four exhibited pressures in excess of 20 mmHg for >2 h duration. In three of these patients intracranial pressures rose to levels at which cerebral perfusion was jeopardized and at this stage Althesin infusion was employed (Fig. 4).

Cerebral haemorrhage

Two patients were found to have cerebral haemorrhages and both these patients subsequently died. The first patient, a 35-year-old para 4, fitted for 5 h before caesarean section, after which her level of consciousness remained at Glasgow coma scale 4/15. CT scan revealed an intra-pontine bleed. The second patient, a 15-year-old primigravida, was admitted moribund having fitted for many hours during inter-hospital transfer. Autopsy revealed a large frontal intracerebral haematoma.

Discussion

Eclampsia is still a relatively common occurrence in developing countries, and its pathophysiology remains largely unknown.

CT scans revealed low density areas suggestive of cerebral oedema in 70% (14 out of 20) of

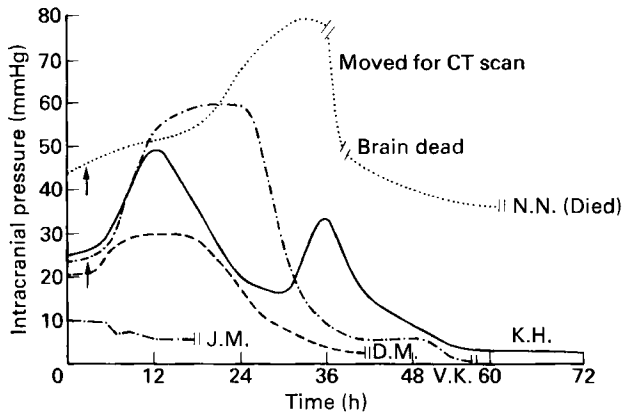


Fig. 4. Intracranial pressure changes in five patients in coma after severe eclampsia. Arrows indicate Althesin mannitol ventilation.

our patients remaining unconscious ≥ 6 h after delivery. Three patterns of cerebral oedema were demonstrated which, when correlated with basal cistern effacement on CT scan (Teasdale *et al.* 1984), measurement of intracranial pressure and duration of seizures, represent a spectrum of severity (Table 2). The changes being most marked in patients with the longest duration of seizures.

The pattern of oedema demonstrated on CT scan involved predominantly cerebral white matter (Fig. 1). Vasogenic brain oedema is known to produce this pattern of white matter low density (Miller 1979). The reasons for a vasogenic pattern of oedema are unclear but may be related to the generalized vasculopathy found in eclamptic patients. Vessel wall damage may allow transudation of plasma, this would be exacerbated by hypertension and seizures.

Rapid control of seizures is necessary to prevent widespread hypoxic cerebral damage. Maximal brain metabolism during seizure activity with consequent depletion of glucose and oxygen reserves, in addition to the absence of normal respiration, results in hypoxic damage. Recurring seizures constitute a particularly dangerous situation, for worsening cerebral hypoxic damage.

Maintenance of an adequate airway and respiration during seizures should be an immediate priority in eclamptic patients. Frequent arterial blood gas measurements are essential to quantify oxygen therapy. An arterial P_{O_2} level of at least 100 mmHg is recommended for all unconscious patients.

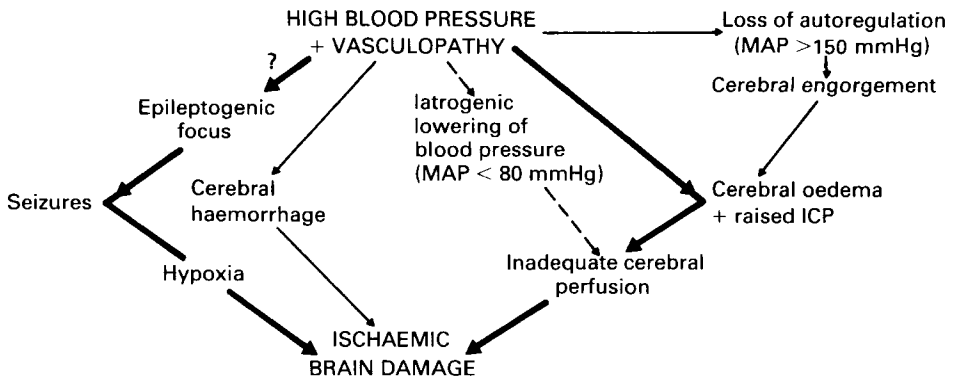
Optimal control of blood pressure in eclamp-

tic patients requires considerable judgment and caution. The need to reduce blood pressure to prevent intracerebral haemorrhage is well known. However, our post-mortem data have shown that a major cause of brain damage in eclamptics is cerebral ischaemia/hypoxia, and this may be greatly worsened by lowering the blood pressure below the level necessary to maintain cerebral perfusion in the face of raised intracranial pressure (Graham 1975; Ledingham & Rajagopalan 1979). Assuming a cerebral perfusion pressure around 40–60 mmHg is required to prevent brain ischaemia, and that intracranial pressure may be around 20–30 mmHg in severe eclamptics (Fig. 4), then a minimum mean arterial pressure around 80 mmHg would be required (Fig. 5).

On the other hand, when the mean arterial pressure exceeds 150 mmHg, the upper limit of cerebral autoregulation is breached, and widespread cerebral vasodilatation occurs, leading to engorgement, probable further oedema, and further elevation of the intracranial pressure (Fig. 5).

Injudicious rapid reduction of blood pressure maybe as dangerous as uncontrolled hypertension, therefore the optimal mean arterial pressure in eclamptic patients with suspected cerebral oedema would be between 80 and 100 mmHg.

Delivery of the fetus is desirable to terminate the eclamptic vasculopathic process. Caesarean section is usually the most rapid route available. Scrupulous anaesthetic technique aimed at avoiding blood pressure fluctuations is essential to optimize cerebral perfusion. Where general anaesthesia is employed, extubation should be



Cerebral perfusion pressure = mean arterial pressure (MAP) – intracranial pressure (ICP)

Fig. 5. Mechanisms for the development of brain damage in eclampsia.

delayed until the patient is fully awake and able to maintain an adequate airway.

Fluid replacement, predominantly with colloids, should be undertaken against central venous pressure measurement. Large volumes of crystalloids are held by certain authors to worsen brain oedema (Miller 1979).

We have empirically administered steroids to our patients for CT scan in the belief that the development of vasogenic oedema maybe retarded, although no concrete evidence exists that steroids are of benefit in eclampsia.

We have found that the decision to refer eclamptic patients should be delayed for several hours after delivery, except where localizing neurological signs are present, or where deterioration in consciousness occurs. Many apparently comatose eclamptic patients recover rapidly and uneventfully after delivery. However, we believe CT scanning is desirable for all those who are persistently unconscious 4–6 h after delivery. Our data suggests that the majority of these women will have cerebral oedema.

Intracranial pressure monitoring should only be considered in persistently comatose patients with marked CT scan abnormalities. We have used basal cisternal effacement on CT scan as a criterion of raised intracranial pressure (Teasdale *et al.* 1984), and this was an accurate predictor of high pressure in 60% of our cases in whom intracranial pressure was monitored. Intracranial pressure monitoring should be carried out in an intensive care unit, with the intention of controlling high pressure and improving cerebral perfusion. Measures we have found useful include posture (30° of head up tilt to improve venous drainage), 20% man-

nitrol (0.5 g/kg) given as an i.v. bolus, and hyperventilation to reduce arterial P_{CO_2} to 28 ± 4 mmHg. Where these measures failed, we employed Althesin, a steroidal anaesthetic induction agent which rapidly reduces brain activity and metabolism. We believe Althesin to be a safer agent than barbiturates, although barbiturate coma is employed in many neurosurgical centres to reduce high intracranial pressure.

In all of our surviving patients with high intracranial pressure, a dramatic fall occurred around 24–36 h after delivery (Fig. 4). We believe this corresponds to resolution of the vasculopathy rather than the brain oedema itself. We have observed persistent low-density on CT scan up to 7 days after delivery.

Five out of 192 eclamptic patients in our series died, a marked improvement in our previously reported maternal mortality. Early CT scanning allows differentiation between cerebral oedema and cerebral haemorrhage. Aggressive neurological management directed towards lowering intracranial pressure and preserving cerebral perfusion appears to greatly improve the prognosis for severe eclamptic patients.

Acknowledgments

We would like to thank the Natal Provincial Ambulance Service for the efficient and expert transportation of the patients in this study. We are also very grateful to Professor Van Dellen and the staff in both the CT scanning and Neurosurgical I.C.U. departments at Wentworth Hospital.

References

- Augensen, K. & Bergsjø, P. (1984) Maternal mortality in the Nordic Countries. *Acta Obstet Gynecol Scand* **63**, 115-121.
- Beck, D. W. & Menezes, A. H. (1981) Intracerebral hemorrhage in a patient with eclampsia. *J Am Med Assoc* **246**, 1442-1443.
- Beeson, J. H. & Duda, E. E. (1981) Computed axial tomography scan demonstration of cerebral oedema in eclampsia preceded by blindness. *Obstet Gynecol* **60**, 529-532.
- Benedetti, M. D. & Quilligan, E. J. (1980) Cerebral oedema in severe pregnancy-induced hypertension. *Am J Obstet Gynecol* **137**, 860-862.
- Donnelly, J. F., Lock, F. R. & Winston-Salem, N. C. (1954) Causes of death in five hundred and thirty three fatal cases of toxemia of pregnancy. *Am J Obstet Gynecol* **68**, 184-189.
- Drayer, B. P. & Rosenbaum, A. E. (1976) Brain oedema defined by cranial computed tomography. *J Computer Assisted Tomography* **3**, 317-323.
- Evans, J. M. & Keogh, J. A. M. (1977) Adverse reactions to intravenous anaesthetic induction agents. *Br Med J* **ii**, 735-736.
- Gibbs, C. E. & Locke, W. E. (1976) Maternal deaths in Texas, 1969 to 1973. *Am J Obstet Gynecol* **125**, 687-691.
- Graham, D. I. (1975) Ischaemic brain damage of cerebral perfusion failure type after treatment of severe hypertension. *Br Med J* **iv**, 739.
- Ledingham, J. G. G. & Rajagopalan, B. (1979) Cerebral complications in the treatment of accelerated hypertension. *Quart J Med* **48**, 25-41.
- McIlhany, M., Rapport, R., Dunn, R., Namazie, M. & Delilican, A. (1983) Althesin in the management of head injuries. A preliminary report. *Neurosurgery* **12**, 77-79.
- Melrose, E. B. (1984) Maternal deaths at King Edward VIII Hospital, Durban. *S Afr Med J* **65**, 161-165.
- Miller, J. D. (1979) Management of cerebral oedema. *Br J Hosp Med* **21**, 152-157.
- Moodley, J., Norman, R. J. & Reddi, K. (1984) Central venous concentrations of immunoreactive prostaglandins E, F, and 6-keto-prostaglandin F, in eclampsia. *Br Med J* **288**, 1487-1489.
- Sheehan, H. L. & Lynch, J. B. (1973) Pathology of toxæmia of pregnancy. Williams and Williams Co, Baltimore.
- Souter, W. P. (1980) The haemodynamic pathophysiology of pre-eclampsia. *S Afr Med J* **48**, 351-355.
- King Edward VIII Hospital, University of Natal (1983) *Statistics from the Department of Obstetrics and Gynaecology*.
- Stewart, G. O., Dobb, G. J. & Graig, I. A. (1983) Clinical trial of continuous infusion of Alphaxalone-Alphadolone in intensive care patients. *Anaesth Intens Care* **11**, 107-112.
- Teasdale, G. & Jennett, B. (1974) Assessment of coma and impaired consciousness: A practical scale. *Lancet* **ii**, 81-83.
- Teasdale, E., Cardose, E., Galbraith, S. & Teasdale, G. (1984) CT scan in severe diffuse head injury: physiological and clinical correlations. *J Neurol Neurosurg Psychiatry* **47**, 600-603.

Received 25 June 1985

Accepted 7 October 1985