

Painless Dissections of the Aorta Presenting as Acute Neurologic Syndromes

ODED GERBER, M.D., ERIC J. HEYER, M.D., PH.D.,* AND ULRICH VIEUX, M.D.

SUMMARY We describe three patients who had painless dissections of the aorta which resulted in neurologic syndromes at the time of presentation. Two patients had acute hemimotor and sensory findings. In one of these cases progression to paraplegia occurred. In a third patient, acute weakness and ischemia of a leg occurred at presentation. We review previously described painless aortic dissections. Such aortic dissections may be suspected in the setting of an acute neurologic event by abnormalities in the examination of the peripheral pulses and the heart and by attention to characteristic chest x-ray changes.

Stroke Vol 17, No 4, 1986

IN 1941 Willius and Cragg¹ cited four reasons for failure to diagnose dissecting aneurysms of the aorta. These were: 1) the relative infrequency of the condition; 2) the variation in its clinical manifestations and the absence of a characteristic syndrome; 3) the limitation of special diagnostic adjuncts; and 4) the lack of universal clinical suspicion. More than thirty years later, we have encountered three patients in whom the diagnosis of dissection of the aorta (DA) was overlooked at initial presentation. These patients exhibited variations from the usual clinical manifestations of DA. They did not demonstrate the features of what has become known as the characteristic syndrome of DA, which has generally included severe chest, back or abdominal pain. Our patients had painless dissections of the aorta resulting in acute neurologic syndromes. This presentation has not been previously reported.

Case 1

A 63 year old woman with a history of hypertension developed left sided weakness while walking. There was no loss of consciousness. She had a past history of bilateral corneal ulceration, alcoholism, multiple suicide attempts, erosive gastritis, and a "heart attack" three years earlier. One month prior to admission she had been seen at another hospital for dizziness, headache and hearing loss, and was studied with a cardiac Holter monitor, electroencephalography (EEG) and a computerized tomographic (CT) scan of the head. Physical examination and all studies were normal.

On admission, blood pressure in the upper extremities was unobtainable; her pulse was 68 beats per minute. Cardiac and abdominal examinations were normal. Her right leg was cool and the right toes were mottled. She had no right carotid pulse, no right femoral pulse nor any pulse in the upper extremities. The patient was alert and oriented. Her speech was fluent but slow and dysarthric. Because of her longstanding corneal ulceration she had no vision in the right eye

and minimal vision in the left eye. Visual fields could not be determined. Left facial weakness was present. A dense left hemiplegia was present. She had absent pin, vibration and joint position sensation on the left side. Chest x-ray on admission demonstrated a widened mediastinum. The electrocardiogram showed non-specific ST wave changes and poor R wave progression. An aortogram demonstrated a Type 1 dissecting aortic aneurysm involving the aortic arch, descending aorta and the right iliac artery. There was obstruction of the right brachiocephalic and right iliac arteries by the intimal flap. There was hypoperfusion of the right kidney. The left subclavian and left carotid arteries filled normally. During the subsequent eight months of hospitalization her neurologic examination remained essentially unchanged except for bouts of confusion and lethargy. In addition, she had several episodes of sepsis as a result of urinary tract infections and pneumonia. She expired after this time. Permission for post mortem examination was refused.

Case 2

A 69 year old woman with a past history of hypothyroidism and hypertension was well until she noted "a funny feeling" in her throat. Fifteen minutes later she lost consciousness briefly. When she awakened, she had left sided weakness.

On admission her blood pressure was 200/80 mm Hg, and her pulse 45 beats per minute. A left homonymous hemianopsia, left hemiparesis and left Babinski sign were present. The right carotid pulse was weak. Brachial, radial and femoral pulses were absent on the right. No cardiac murmurs were heard. The abdominal examination was normal. A neurological consultant found an alert patient who followed commands, was oriented, performed simple calculations and named the last several presidents accurately. There was neglect of her left side. A left homonymous hemianopia was present. Her head and eyes were deviated to the right at rest; however, she was able to move her eyes in all directions on command. She had left central facial weakness and drift of the left upper extremity. She would not cooperate with formal motor testing of the left extremities. There was extinction of touch and pin on the left side. Twelve hours after admission, when both lower extremities became painful below the knees, a vascular consultant diagnosed chronic vascular insufficiency. Twenty-four hours after admission, the patient developed a flaccid paraplegia. The neglect

From the Departments of Neurology, and Radiology, Mount Sinai Services at Elmhurst and The Mount Sinai School of Medicine of the City University of New York.

*Supported in part by NINCDS Teacher-Investigator Development Award (NS 00657).

Address correspondence to: Dr. Oded Gerber, Department of Neurology, Mount Sinai Services, City Hospital Center at Elmhurst, 79-01 Broadway, Elmhurst, New York 11373.

Received November 21, 1984; revision #2 accepted November 5, 1985.

syndrome and the left arm weakness had improved by then. A sensory level was found at T11 as well as at T5. Her mental status remained normal. A chest x-ray demonstrated elongation, tortuosity and calcification of the thoracic aorta. An electrocardiogram demonstrated sinus bradycardia. Several hours after the onset of her paraplegia an aortic arch study and abdominal aortogram were performed. These showed a Type 1 dissecting aortic aneurysm arising from the root of the aorta. (fig. 1) There was complete obstruction of the right brachiocephalic artery by the false lumen as well as narrowing of the true lumen of the aortic arch and the distal descending aorta. (fig. 2) The other major branches of the aortic arch were patent. Complete obstruction of the abdominal aorta below the level of the renal arteries by the false lumen had occurred. Two hours later she became comatose and died. Permission for post mortem examination was refused.

Case 3

A 78 year old man was admitted to the hospital because of left leg weakness. He was well until the day of admission, when he noticed the sudden onset of weakness and numbness of the left leg. In the emergency room this leg was cold and pulseless. He denied chest, back or leg pain. The admitting diagnosis was acute thrombotic or embolic occlusion in the left leg. His past medical history was negative except for a history of hypertension.

On admission the patient was afebrile. A grade 2

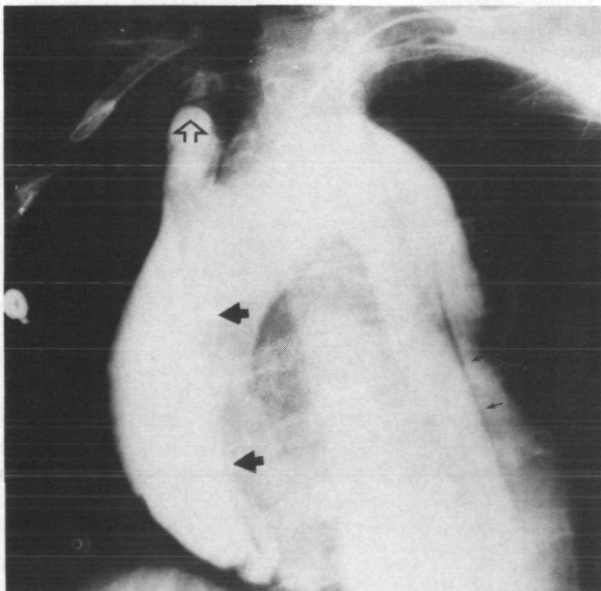


FIGURE 1. Patient 2. Thoracic aortogram in the right posterior oblique projection shows a dissection of the aorta starting from the ascending aorta. The intimal flap (solid arrows) can be seen in the ascending aorta. The false lumen is compressing and occluding the right brachiocephalic artery (open arrow). The left carotid and the left subclavian arteries fed by the true lumen were opacified in previous films. The intimal flap between the false and true lumens is well demonstrated in the descending aorta (small arrows).

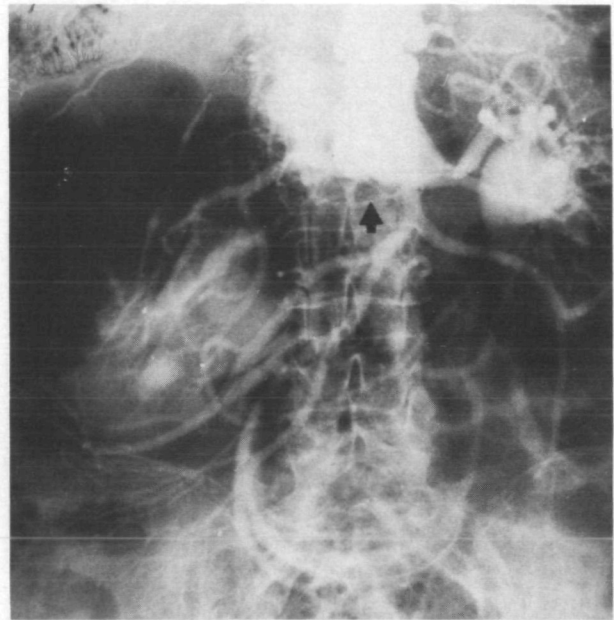


FIGURE 2. Patient 2. The true lumen of the abdominal aorta is seen giving off both renal arteries and the superior mesenteric artery. There is an aneurysmal dilatation of the false lumen characterized by splaying of the branches of the superior mesenteric artery and occlusion of the true lumen (arrow).

diastolic murmur was heard loudest at the third intercostal space on the left. His abdomen was soft, nontender with normal bowel sounds present and no organomegaly. The left leg was cold and no pulses were found at the popliteal, posterior tibial or dorsalis pedis areas. Except for decreased strength and sensation in the left leg, the neurological examination was normal. The chest x-ray showed enlargement of the mediastinum as a result of the widening and tortuosity of the descending aorta. (fig. 3) An abdominal sonogram

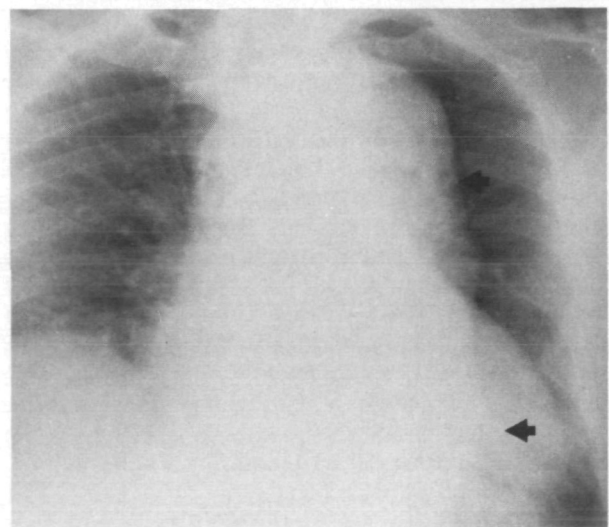


FIGURE 3. Patient 3. A frontal chest radiograph shows enlargement of the mediastinum as a result of widening and tortuosity of the descending thoracic aorta (arrows). The left ventricle is enlarged and the right hemidiaphragm is elevated.

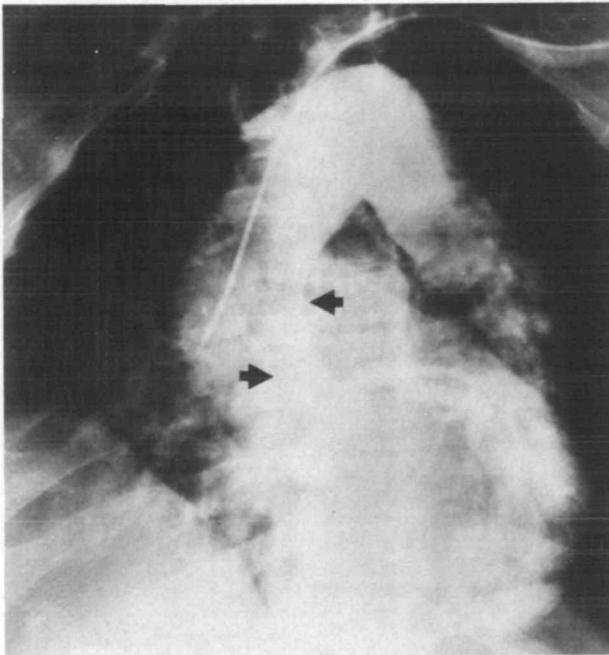


FIGURE 4. Patient 3. A thoracic aortogram reveals a Type I dissection involving the ascending aorta. The true lumen (between arrows) is well visualized. The false lumen is not opacified. The aortic valve and left coronary artery can be well visualized.

demonstrated an aneurysm starting 5 cm above the diaphragm and extending 14 cm below it. An angiogram demonstrated a Type I dissecting aortic aneurysm stopping just above the level of the diaphragm. (fig. 4 and 5) The renal arteries were ectatic bilaterally as were the internal iliac arteries and deep femoral arteries. There was abrupt cut off of contrast in the left common femoral artery and occlusion of the right superficial femoral artery at its origin. Three days after admission the patient had three generalized seizures and postictally had a left hemiparesis. Neurological examination at that time disclosed that the patient was alert and oriented. His memory to events immediate, recent and past was normal. He had no aphasia. There was mild weakness in the left arm and leg with decreased graphesthesia in the left hand and impaired position sense in the left hand and foot. Pin and vibration sensations were normal. Deep tendon reflexes were symmetric, but left plantar response was equivocal. Gait was broadbased. A CT scan of the head without contrast was performed two days later which demonstrated a calcified lesion in the right frontal area that did not enhance significantly with contrast. This lesion was thought to be a meningioma. Subsequently, the patient had an above the knee amputation on the left. He was discharged six months later after multiple medical complications.

Discussion

The three patients described represent DAs proven by angiography. Each patient is an example of painless dissection resulting in a neurologic or neurovascular

syndrome. As pain is by far the most characteristic symptom of DA, its absence in these patients, initially diverted attention from the correct diagnosis. However, attention to such simple clinical signs as absent peripheral pulses in combination with the abnormal chest roentgenograms, provided ready clues to the diagnosis of DA. DAs are classified into three categories.² Type I represents those with a tear of the intima in the ascending aorta, usually with progression around the arch into the descending and abdominal aorta. Type II dissections are similar to Type I but are confined to the ascending aorta. This type of dissection ends prior to the origin of the great vessels. Type III dissections originate distal to the vessels of the arch in the descending aorta. On occasion, Type III DAs may progress in a retrograde manner into the arch and the ascending aorta.

Neurologic involvement in DA has been reported to occur in approximately 18% of all instances of DA.³ Weisman and Adams⁴ were the first to describe a series of patients with neurologic syndromes as a result of DA. In contrast to the more common instances of dizziness and alterations of consciousness which may occur as a result of major organ failure, Weisman and Adams described specific classes of neurologic dysfunction resulting from direct vascular compromise to the nervous system. These consisted of: 1) ischemic necrosis of peripheral nerves; 2) ischemic necrosis of the spinal cord; and 3) ischemic necrosis of the brain.

Each of our patients represents an example of one or more of the syndromes described by Weisman and Adams.⁴ However, our patients differed as a result of the painless nature of their dissections. In patient 1, a

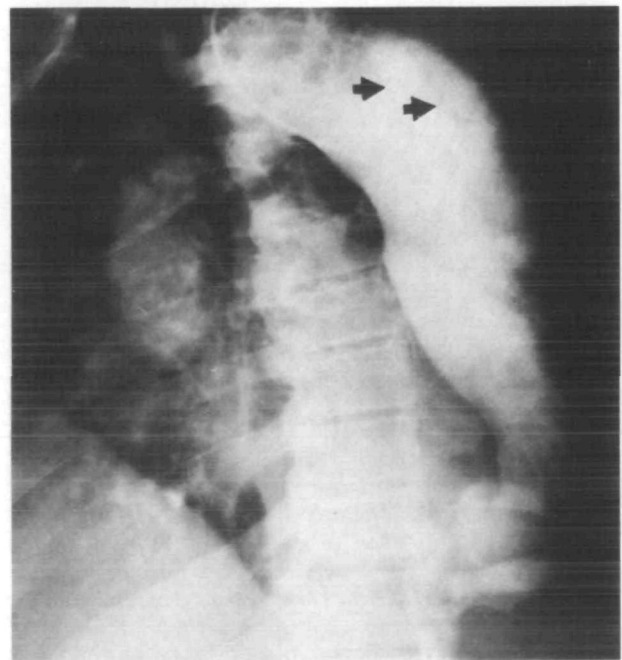


FIGURE 5. Patient 3. With the tip of the catheter in the descending aorta, contrast medium fills both the true and false lumens outlining the intimal flap (arrows).

clinically profound right cerebral syndrome was caused by occlusion of an innominate artery by the dissection. In patient 2, similarly, innominate occlusion occurred as a result of dissection of the aorta resulting in right cerebral ischemia. The active dissection must have initially stopped, only to resume later, and result in thoracic and abdominal aortic dissection with a consequent ischemic myelopathy. In patient 3, the motor and sensory involvement of the left leg represented an acute ischemic neuropathy. This most likely was caused by an embolus from the dissection. The time of occurrence of actual dissection cannot be determined. The seizures and the right hemispheric signs in this patient may have been related to the dissection, or alternatively were caused by the meningioma.

The incidence of the absence of pain in DA has varied in different series. In an early series comprised of post mortem discovered cases and consequently predominantly of chronic DAs, Baer and Goldburgh⁵ reported that 55% of 44 patients with DA did not have a history of pain. According to the large review by Hirst³ 14% of 409 patients in whom symptoms were recorded, did not mention pain. More recent series compiled by clinicians and radiologists and therefore including more acute cases^{2, 6-8} note an incidence of painless DA of only about 10%.

In the past many individual cases have been reported as having painless dissecting aneurysms. All of these patients have had absence of the characteristic syndrome, although many cannot be classified as true painless DAs. In a large number of such patients the diagnosis was established weeks to years after the actual dissection.⁹⁻¹³ In such cases pain may not have been remembered at the time of diagnosis or its occurrence may have been attributed to another cause. In others there existed changes in consciousness, mentation, memory or speech such that these patients could not describe a pain syndrome.^{14, 15} In still others pain was present but not in the classically recognized locations.¹⁶ These patients had pain in the groin, hips and elsewhere. Still others had disturbing subjective symptoms other than pain.^{10, 17} These included such diverse complaints as oppressive feelings in the chest and epigastric discomfort.

Several explanations have been advanced over the years for the absence of pain in some patients with DA. None have been entirely satisfactory. These have included speculation that slow dissection may not result in pain,¹¹ that sparing of the adventitia may obviate pain,^{11, 13} and that circumventing and thus sparing intercostal, lumbar and splanchnic vessels may result in painless dissection.¹⁶ Our patients represent examples of painless DAs presenting with acute neurologic syndromes. The first two patients represent acute dissections. The third patient belongs in the category of dissection of indeterminate duration. In all three patients there was clear evidence on general physical examination of sudden occlusion of one or more major branches of the aorta. This combination of the absence of one or more peripheral pulses¹³ and a vascular neur-

ologic syndrome should lead to a suspicion of DA even in the absence of pain. In addition, at least two of our patients (patients 1 and 3) had findings on chest x-ray compatible with DA.¹⁸

Conclusion

Our case descriptions are intended to illustrate a category of patients that may be easily overlooked and therefore go untreated by those who are primarily concerned with the patients' neurological condition. These patients may be seen by a neurologist for an event or a series of events involving ischemia to the brain, spinal cord or the limbs and their nerve trunks.

Diagnosis of painless DA in such patients should routinely be pursued by careful attention to some of the characteristic and simple non-neurological aspects of DA. These should include, in particular, examination of the peripheral pulses, auscultation for aortic insufficiency murmurs and attention to some of the commonly described chest roentgenographic changes.

References

1. Willius FA, Cragg RW: Cardiac Clinics LXXIX. A talk on dissecting aneurysm of the aorta. Proc of Staff Meeting Mayo Clinic 16:41-4, 1941
2. Dalen JE, Howe JP: Dissection of the aorta: current diagnostic and therapeutic approaches. JAMA 242: 1530-1532, 1979
3. Hirst AE, Johns VJ, Kime SW: Dissecting aneurysm of the aorta: a review of 505 cases. Medicine 37: 217-279, 1958
4. Weisman D, Adams RD: The neurological complications of dissecting aortic aneurysm. Brain 67: 69-92, 1944
5. Baer S, Goldburgh HL: The varied clinical syndromes produced by dissecting aneurysm. Am Heart J 35: 198-211, 1948
6. Vech RJ, Besterman EMM, Bromley LL, Eastcott HHG, Kenyon JR: Acute aortic dissection: historical perspective and current management. Am Heart J 102: 1087-1089, 1981
7. Lindsay J, Hurst JW: Clinical features and prognosis in dissecting aneurysm of the aorta. Circulation 35: 880-887, 1967
8. Slater EE, DeSanctis RW: The clinical recognition of dissecting aortic aneurysm. Am J Med 60: 625-633, 1976
9. Ambos MA, Rothberg M, Lefleur RS, Weiner S, McCanley D: Unsuspected aortic dissection: The chronic "healed" dissection. AJR 132: 221-225, 1979
10. Garcia R, Torbey P, Anbe DT, Drake EH: Painless dissecting aneurysm of the thoracic aorta: report of eight cases masquerading as gross aortic insufficiency, severe hypertension, myocardial infarction and mediastinal enlargement. Henry Ford Hosp Med J 25: 21-32, 1977
11. Wood FC, Pendergrass EP, Ostrum HW: Dissecting aneurysm of the aorta with special reference to its roentgenographic features. A J Roentgenology and Radium Ther 28: 437-465, 1932
12. Cohen S, Littman D: Painless dissecting aneurysm of the aorta. N Engl J Med 271: 143-145, 1964
13. O'Donovan TPB, Osmundson PJ, Payne WS: Painless dissecting aneurysm of the aorta: report of a case. Circulation 29: 782-786, 1964
14. Chase TN, Rosman NP, Price DL: The cerebral syndromes associated with dissecting aneurysm of the aorta. A clinicopathological study. Brain 91: 173-192, 1968
15. Rosenberg GA: Transient global amnesia with a dissecting aortic aneurysm. Arch Neurol 36: 255, 1979
16. Amer NC, Schaeffer HC, Domingo RT, Sawyer PN, Wesolowski SA: Aortic dissection presenting as iliac occlusion — an aid to early diagnosis. N Engl J Med 266: 1040, 1962
17. Hamburger M, Ferris EB: Dissecting aneurysm: study of six recent cases. Am Heart J 16: 1-13, 1938
18. Smith DC, Jang GC: Radiological diagnosis of aortic dissection. In: Doroghazi RM, Slater EE. Aortic dissection. McGraw-Hill, NY, pp 71-132, 1983