

Thromboembolic Complications of the Jarvik-7 Total Artificial Heart: Case Report

Mark M. Levinson, Richard G. Smith, Randall C. Cork, Joseph Gallo,
Robert W. Emery, Timothy B. Icenogle, Richard A. Ott, *Gregory L. Burns, and
Jack G. Copeland

*Departments of Cardiovascular Surgery, Biomedical Engineering, and Anesthesiology, University Medical Center, Tucson, Arizona, and *Department of Surgery, Division of Artificial Organs, The University of Utah, Salt Lake City, Utah, U.S.A.*

Abstract: The Jarvik-7 total artificial heart (TAH) has now been implanted in seven patients, with four (57%) suffering cerebral embolic events. Functional recovery in two patients was impaired by subsequent intracranial hemorrhage from anticoagulant therapy. The findings of a Jarvik-7 TAH explanted following a cerebral embolus are reported here. Thrombotic deposition was seen in the inner crevice formed between the two components of the aortic quick connector. In addition, deposition was seen around all four valves in the crevice formed between the valve ring and the plastic valve housing. On the atrioventricular valves, the deposition in this crevice was most

severe on the outflow surface adjacent to the minor flow orifice. On the pulmonic valve, deposition was seen around the entire circumference of both the inflow and the outflow crevices. No thrombi were seen on the diaphragm, the diaphragm-housing junction, or the housing of the left ventricle. Hypercoagulability of the patient's blood gradually developed during implant, reaching a maximum on the evening before the clinical embolus. Increasing resistance to heparin was also demonstrated by in vitro testing. **Key Words:** Artificial heart—Jarvik-7 heart—Thromboembolic complications—Hypercoagulation.

After prolonged animal testing and documentation of survival, the Jarvik-7 total artificial heart (TAH) has reached the stage of initial human clinical trials. Two separate trial pathways are currently under way, one for permanent implantation, and one for short-term implantation. The most important postoperative problem identified in human trials of the Jarvik-7 TAH is cerebral embolism. Although renal failure, bleeding, infections, respiratory failure, and other serious sequelae have been described following implantation, the neurologic problems have far outweighed all others in importance. Each implanted patient has been treated with a vigorous regimen of anticoagulation, but presently no drug or drug combination has proved effective in eliminating this complication. Indeed, such powerful anticoagulation has been used that

severe bleeding complications have been described by all centers participating in these trials. Five of the first seven patients have required reexploration of the mediastinum for perioperative hemorrhage. The combined morbidity of the neurologic and bleeding complications has greatly diminished the potential benefit of this promising new therapy for end-stage heart disease.

As of this writing, a total of seven patients have been implanted, with four (57%) suffering embolic neurologic events. Two of the four patients recovered completely, including the one described here. The remaining two patients were left with permanent neurologic deficits; in both, recovery has been impaired by the subsequent development of cerebral hemorrhage from anticoagulant therapy.

The presence of surface defects on the blood-contacting layers of mechanical devices has long been known to favor thrombosis following implantation (1). With improved quality control and elimination of microcracks, microbubbles, and dust particles, thrombosis on the flexing diaphragm or

Received February 1986.

Address correspondence and reprint requests to M. M. Levinson at University Medical Center, 1501 N. Campbell Avenue, Tucson, AZ 85724, U.S.A.

semirigid housing has been greatly reduced in the current Jarvik-7 TAH design. When thrombosis or embolization occurs in implanted valves, septicemia is often present (2). Primary nonseptic thrombosis occurs in 25–30% of implanted valves, usually around the atrial cuffs or the mechanical valves (3–5).

The locations of thrombi associated with the Jarvik-7 TAH explanted from a "bridge-to-transplant" patient are reported here. This case constitutes the first successful use of a TAH as an interim step prior to cardiac transplantation. In addition, this is the first report of the areas of thrombotic deposition in the Jarvik-7 TAH following human implantation, embolization, and explantation. It is believed that this study identifies areas of increased thrombogenicity where attention to redesign and modification can be centered in future models of this device.

This patient also illustrated the dynamic and changing nature of the blood–material interface during the period of implantation. Just prior to the neurologic deficit, a relative hypercoagulable state existed, and *in vitro* coagulation studies returned abruptly to normal. Elevated serum coagulation factors, rising platelet counts, and increasing resistance to continuous heparin infusion were an integral part of these changes. The combination of all these factors predisposed the patient to an acute thrombotic episode on the 7th postimplant day. Improvements in the device and the methods of anticoagulation show considerable promise in eliminating embolic complications of this TAH device.

CASE REPORT

M.D. was a 25-year-old man with end-stage idiopathic cardiomyopathy. Following marked clinical deterioration, the patient developed refractory cardiogenic shock despite high-dose pressor and inotropic therapy. No suitable donor could be located; and both the patient and the family accepted the alternative of TAH implantation as an interim step until human cardiac transplantation could be performed.

On August 29, 1985, the Jarvik-7 TAH was implanted. Hemodynamic stabilization after bypass occurred without incident. Initial cardiac outputs were 6.0 L/min. Protamine (550 mg) was given to reverse intraoperative heparin. No further anticoagulation therapy was given until verification of the absence of mediastinal bleeding. Fifteen hours following closure of the chest, heparin was begun at 100 U/h by continuous infusion. Partial thrombo-

HEPARIN DOSE

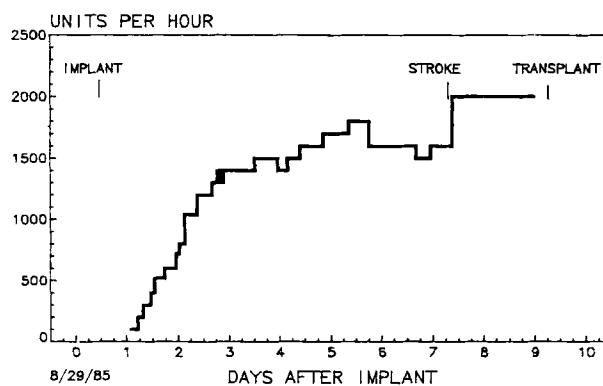


FIG. 1. Heparin dose (U/h) as a reflection of time during the implant period.

plastin times (PTT) were monitored every 4 h but failed to respond to increasing doses of heparin. Figure 1 displays the rising dose of heparin during the first 2 days. After reaching a steady dose of 1,400 U/h with no alteration in the PTT (Fig. 2), thrombin times (TT) were monitored, since this test is more sensitive to the agent. Thrombin times were maintained between two and three times control values from the 3rd to the late 6th postimplant day (Fig. 3). Continuous heparin, between 1,400 and 1,800 U/h, was needed to maintain this level of effect. No antiplatelet agents were given prior to the neurologic event. No bleeding complications from mediastinal, gastrointestinal, other mucosal, or needle puncture sites were identified.

Following prolonged serous drainage, the mediastinal tubes were removed on the 5th postoperative day. Severe pulmonary edema was treated with aggressive diuretic management. Contraction of the interstitial fluid compartment induced gradual resolution of the postoperative pulmonary edema. A total of 17 L of negative fluid balance was incurred in the first 6 days following operation. Successful extubation on the afternoon of the 4th postoperative day demonstrated the effectiveness of this therapy. In addition, there was dramatic clearing of the chest radiograph and further pulmonary problems were absent following extubation.

The remainder of the postoperative course was uneventful until the morning of the 7th day. At this time, the patient abruptly developed a dense aphasia affecting the expressive and receptive areas of the cerebral cortex (Table 1). In addition, the subcortical white matter was involved, as was evidenced by a conductive aphasia clearly apparent

PARTIAL THROMBOPLASTIN TIMES

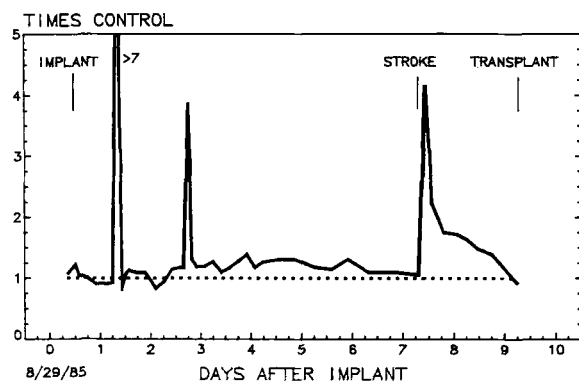


FIG. 2. Partial thromboplastin times (PTT) graphed over the period of implantation. Patient values expressed as a ratio against laboratory control values. Dotted line represents equality to control. Sharp peaks in PTT represent errors in obtaining blood samples.

later that day. A patchy right hemiparesis involving the forearm flexors and the distal leg muscles with partial involvement of the proximal right upper extremity muscle groups also occurred. Bilateral Babinski's and mild parietal lobe signs were also detectable.

Cerebral computer axial tomographic (CAT) scanning 2 h, 5 days, and 8 days post-event failed to show evidence of cerebral necrosis. In view of the absence of intracranial hemorrhage on CAT, increasing levels of heparin were administered. Following a bolus of 7,500 U, the infusion was raised

THROMBIN TIMES

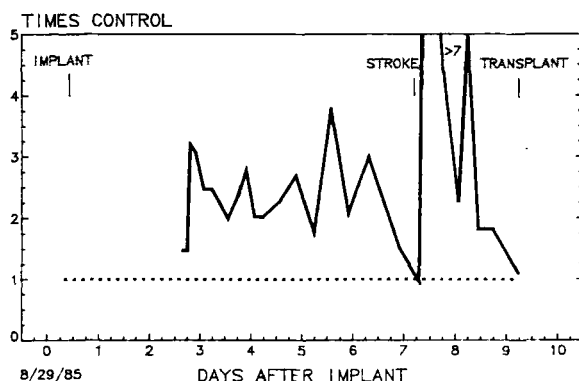


FIG. 3. Thrombin times (TT), with patient values expressed as a ratio against laboratory control values. Dotted line represents equality to control. Note return of TT to control values at the time of this patient's stroke.

TABLE 1. *Clinical findings*

Aphasia
Expressive
Receptive
Conductive
Right hemiparesis
Arm drift
Decreased hand grip
Diminished dorsiflexion of foot
Bilateral Babinski's
Mild parietal lobe signs

to 2,000 U/h and maintained at this level until transplantation was performed (Fig. 1). Dextran 40 (25 ml/h) was also added.

Neurologic resolution began ~4 h following onset. At this time, the receptive aphasia cleared, followed shortly thereafter by a considerable improvement in the expressive aphasia. For several days, the conductive aphasia was apparent, but it then gradually resolved. The right hemiparesis cleared >90% by the first 4 h following onset. Subsequent to transplantation and recovery from post-transplant complications, there are no focal neurologic deficits, and speech is normal.

Nine days following implantation, the patient was returned to the operating room, where cardiac transplantation and explantation of the device were performed. Figure 4 shows a photograph of the left ventricular prosthesis. Immediately apparent is a thrombus that lines the circumference of the inner crevice created where the two components of the aortic quick connector snap together. Part of this crevice, however, is devoid of macrothrombus. In the closeup view, Fig. 5, a nonadherent freely mobile remnant of the clot is visible. It is suspected that a clot previously occupied the remainder of this crevice but broke free and embolized to the cerebral circulation.

Patchy thrombotic deposition can also be seen on the titanium valve ring, particularly in the minor flow orifice position. Careful inspection shows a small amount of deposition on the under surface of the aortic valve along the crevice where the titanium and the hard plastic valve housing join. In addition, there are tiny thrombi at the junction between the Dacron aortic graft and the polyurethane ring that constitutes the female portion of the aortic quick connector.

Figure 6 shows the histologic appearance of the thrombus along the aortic valve ring. It is a very fresh, unorganized, unmodified acute thrombus with intact red blood cells, white blood cells, and immature fibrin. Thrombi associated with the other

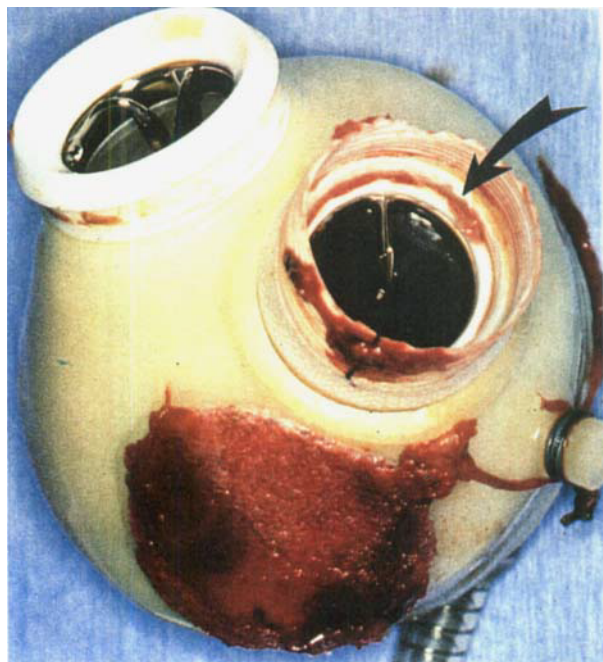


FIG. 4. Explanted left ventricle. Note thrombus located in the inner crevice where the two components of the aortic quick connector snap together (arrow).

valve rings were of similar composition. The mitral valve as seen from the atrial side is pictured in Fig. 7. The inflow surface is free of thrombi, but the outflow/ventricular surface shows a rim of

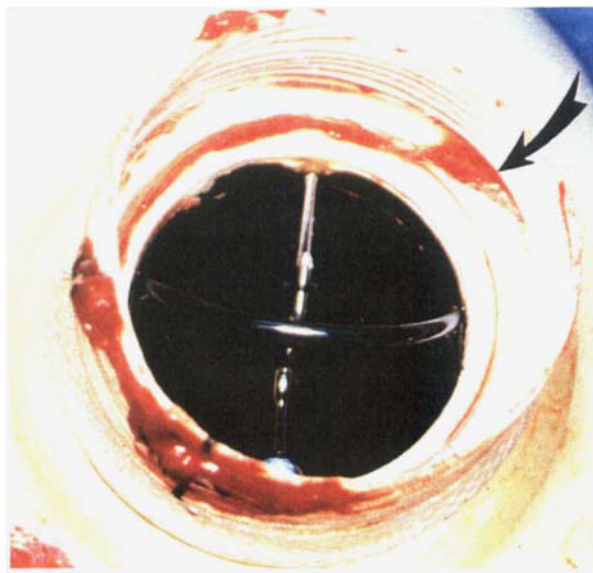


FIG. 5. Closeup of Medtronic Hall aortic valve. Note loosened remnant of thrombus displaced out of the aortic quick connector crevice (arrow).

thrombus adherent to the crevice formed between the valve ring and the valve housing. This thrombus is present only in the minor flow orifice and extends from the rod-guide of the Medtronic Hall

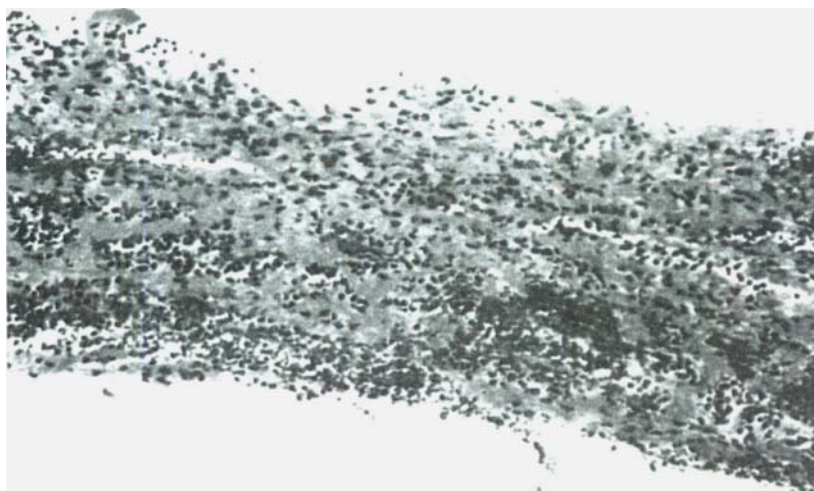

FIG. 6. Photomicrograph, with hematoxylin and eosin stain, of thrombus from around aortic valve. No evidence of organization is present, implying recent thrombus formation. $\times 250$.

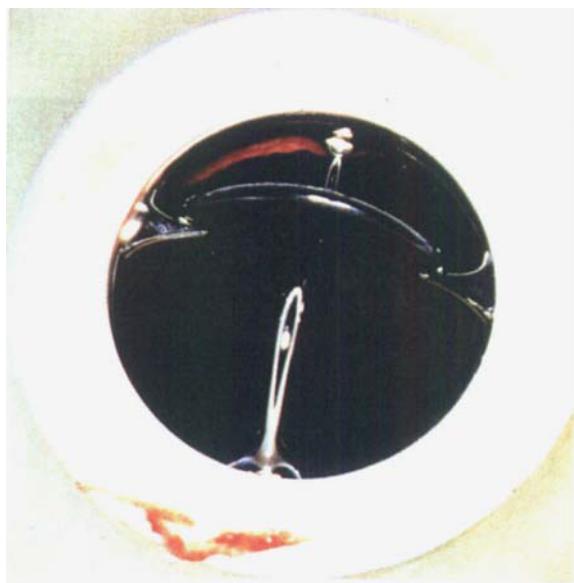


FIG. 7. Mitral valve. Note thrombus adherent to the outflow valve ring crevice adjacent to the minor flow orifice of this tilting disc valve.




FIG. 8. Ventricular surface of mitral valve (after formalin preservation). Arrow highlights the fine rim of thrombus, which starts at the central strut and extends along the valve ring crevice.

valve to the retaining pin. After formalin preservation, the ventricles were opened and this thrombus could then be seen from the ventricular side (Fig. 8).

The body of the left ventricle was free of thrombus. The polyurethane monolayer that covers the housing, the diaphragm-housing junction, and the blood-contacting surfaces of the diaphragm did

not show any signs of thrombi following this 9-day implantation (Fig. 9). The right ventricle, when opened, did display some tiny white patches on the diaphragm-housing junction, and a small thrombotic stain at the surface defect created where the de-airing needle punctured the polyurethane monolayer (Fig. 10).

The right ventricular valves demonstrated many

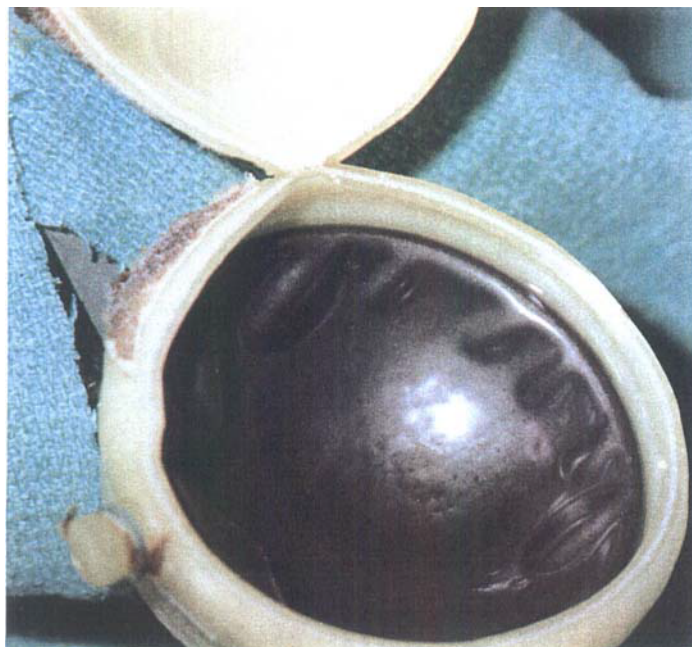

FIG. 9. The body and pumping diaphragm of the left ventricle were free of visible thrombi.




FIG. 10. Right ventricle, showing thrombotic stain on de-airing port and flecks of white material (arrow) along diaphragm housing junction.

of the same findings as did the left. Figure 11 shows the tricuspid valve from the atrial view. Again, there is thrombus adherent to the crevice formed between the valve ring and the valve housing. The thrombus is adherent to the ventricular surface of this crevice and extends from the rod-guide to the first retaining pin in a fashion similar to that seen on the mitral valve. In addition, there are a few small thrombi adherent to the crevice on the atrial side of this valve. The pulmonic valve is pictured in Fig. 12. The crevice created between the titanium valve ring and the hard plastic housing can easily be seen. Small thrombi are scattered throughout the entire circumference of both the inflow and outflow crevices of this valve.

The acute thrombotic event occurred as a result of a complex of multiple factors, many of them unrelated to the device. It was discovered that progressive hypercoagulability developed during the implant, reaching a maximum on the 6th day. Not only was resistance to heparin manifest at that time, but analysis of coagulation factor levels revealed simultaneous supranormal concentrations of all important coagulation mediators on the same day. The platelet count underwent a two-fold increase the day preceding the stroke. Fibrinogen peaked at almost twice normal. Factor X, albumin, and antithrombin III all underwent similar, though less dramatic, increases.

Coupled with these trends was a progressive fall in cardiac output during the previous several days, reaching a minimum of 4.0 L/min on the sixth post-operative day. Lower pump flows were seen at this time because of severe volume contraction following aggressive diuresis. Although this therapy was effective in removing pulmonary edema fluid, the resulting hemoconcentration and hypovolemia were deleterious to pump output and the effectiveness of anticoagulation therapy. It is believed that the unfortunate combination of increasing serum cofactor concentrations with lowered cardiac outputs predisposed this patient to acute thrombosis at the sites described above.

DISCUSSION

Cerebral thromboembolic complications have proved to be the most serious drawback uncovered in the initial human trials of the Jarvik-7 TAH. Despite aggressive anticoagulation therapy of different types, no definitive solution has been found. Of the first seven implanted patients, four have had embolic strokes, and two of these patients have also developed intracranial hemorrhage secondary to

anticoagulant therapy. Although two of the initial four patients have resolved their strokes, the risk of permanent neurologic deficit is a major clinical concern when TAH replacement is recommended to a patient with dwindling cardiac function.

A solution to this problem must be obtained before widespread clinical use of this device can be recommended. The first step in this solution certainly must be an analysis of the source of emboli from affected patients. Of these seven patients receiving implants, the patient described here is the first individual reported from whom the device was explanted shortly following a cerebral embolic event. Localization of the sites of thrombosis was possible. It was also possible to intelligently speculate that the aortic quick connector was the site of origin of the cerebral embolism in this particular case.

Although similar sites of thrombosis are seen in animal implants (3–5), bacteremia or septicemia is postulated to be a major causative factor in this investigative model (2). The exact sites of thrombosis of the Jarvik-7 TAH when it is in contact with aseptic human blood have not previously been described. It was observed in this one case that the critical areas with a high propensity for thrombus formation are the following (Fig. 13): (a) the inner crevice of the aortic quick connector, (b) the junction of the quick connector and the aortic Dacron graft, and (c) the inflow and outflow crevices of each valve where it is seated into the hard plastic valve housing. In addition, there is a possibility that thrombus can deposit at a surface defect created where the de-airing needle punctures through the polyurethane membrane of the housing.

In order to reduce the risk of thromboembolic disease with the Jarvik-7 design, several possibilities must be considered. First, a reduction in surface defects where the inflow and outflow valves are mounted is certainly important. A new technique for mounting the valves must be designed to minimize the formation of anatomic crevices. The quick connector system should also be changed to provide a crevice-free, smooth-surfaced transition that is less thrombogenic. It appears that the housing and the diaphragm of the current Jarvik-7 design pose a minimal risk for thrombosis in short-term human implants.

Second, anticoagulation systems that are more effective in preventing thrombosis without significant hemorrhage are desperately needed. Warfarin, aspirin, dipyridamole, and heparin have all been used in various combinations without complete success in preventing embolization. In addition, se-




FIG. 11. Tricuspid valve, showing sites of thrombotic deposition similar to those seen in the mitral valve. Deposits also occur on the inflow surface of the valve ring crevice (arrows).

vere bleeding problems in TAH recipients have been reported in most patients treated with these agents (R. J. Jarvik, et al., unpublished observations). It is difficult to determine exactly which in vitro assay best follows the degree of the in vivo anticoagulation effects obtained with these medications. Thus, it is also difficult to decide which dose range is the ideal target for their antithrombotic effects. In addition, multicomponent therapy has increased the complication rate without protecting against thromboembolism. Research into new anticoagulants such as protease inhibitors, low-molec-

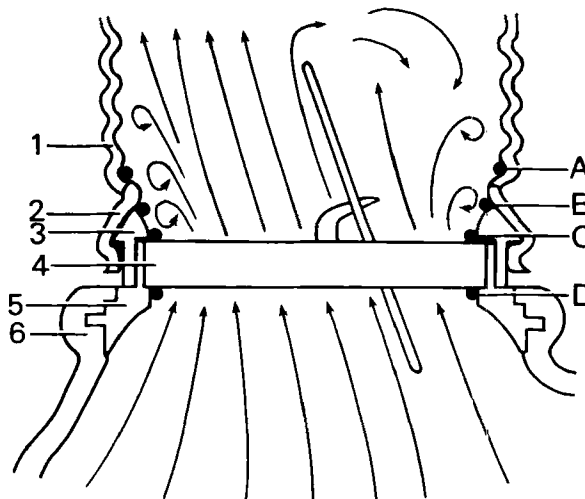


FIG. 13. Conceptual cutaway diagram of the aortic outflow and quick connector system, indicating sites of thrombosis in this patient and the corresponding surface defects. Components of the Jarvik-7 outlet port: 1: Dacron aortic graft; 2: Skirt of aortic quick connect; 3,5: Valve mounting apparatus; 4: Titanium ring of Medtronic Hall outflow valve; 6: Polyurethane housing of blood pump. Sites of thrombosis: A: Dacron-quick connect junction; B: Aortic quick connect crevice (possible source of cerebral embolus); C: Outflow valve ring crevice; D: Inflow valve ring crevice.

ular-weight heparin, fibrinolytic agents (tissue-type plasminogen activator), and new antiplatelet drugs such as prostaglandin analogs and calcium channel blockers provides a new frontier of research and potential therapy for this difficult problem.

A third component of the solution to this important complication is the recognition of alterations in the patient that may induce coagulation (Table 2). Following implantation, the liver may respond dramatically to the relief of heart failure and shock. Subsequent outpouring of coagulation factors can occur, which induces a hypercoagulable state. In

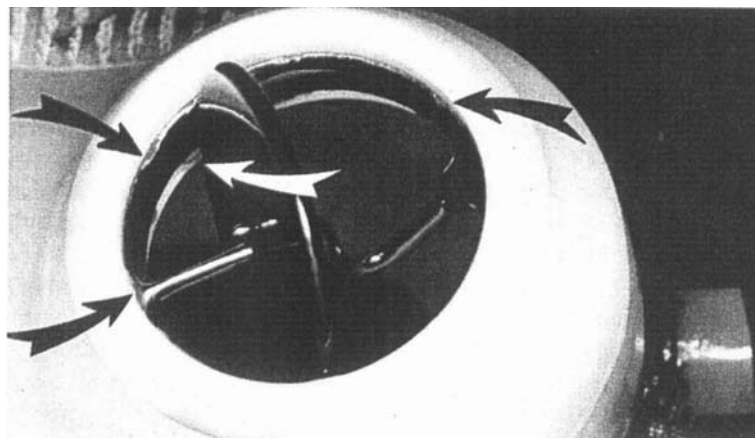


FIG. 12. Pulmonic valve, showing thrombotic deposits adherent to both valve ring crevices around the entire circumference (arrows).

this respect, the sharp rise in "acute phase reactants" normally seen after any surgical stress assumes a great deal more importance in recipients of TAH devices. The acute increase in platelet count just prior to embolism in this patient was also seen in at least two of the permanent Jarvik-7 TAH recipients (W. C. DeVries, personal communication) and is a potentially important observation. This phenomenon may be the earliest sign of impending thrombotic events. Further experience will determine if changes in these "acute phase reactants" following TAH implantation actually provide an early clue to thrombotic complications. If so, anticoagulant therapy could be modified at these times if such trends are recognized prior to neurologic sequelae.

Iatrogenic factors worsening these effects include dehydration and transfusion of plasma cofactors to treat bleeding complications. Volume contraction also increases serum viscosity and osmolarity, which may predispose acute thrombosis. Hemoconcentration may account for a great deal of the increased levels of serum cofactors seen in this case. In addition, dehydration lowers venous filling pressure, pump filling volumes, and mean cardiac output. This, in turn, causes decreased velocity of blood flow across the critical thrombogenic areas of this device. After the 1st or 2nd postoperative day, cardiac outputs should probably be maintained at ≥ 3 L/min/m² to counter this effect. Unfortunately, the patient described here had a hypercoagulable state at the same time low cardiac outputs were obtained. This unfortunate combination may well have overcome the effects of the anticoagulant system used in this patient (Table 2).

TABLE 2. Cause of stroke: identifiable factors

Thrombogenicity of the device
Aortic quick connector crevice
Valve ring crevices
Minor flow orifice characteristics
Step-off at aortic quick connector
Dehydration effects
Decreased pump flows
Decreased surface washings
Increased eddy currents in minor flow orifices
Hemoconcentration
Increased levels of coagulation cofactors
Hyperosmolarity-hyperviscosity
Recovery of hepatic function
Increased synthetic function, contributing to elevated cofactor levels
Thrombocytosis
Acute two-fold increase in platelet concentration noted during the 48 h preceding the neurologic event

It is believed that heparin has not been given an adequate trial as a single agent for the prevention of thromboembolism in the Jarvik-7 TAH. Heparin retains many ideal properties for an anticoagulant in this setting (Table 3). It may be that with more experience this agent could be successfully used for short-term implants. Prospective monitoring of important laboratory values, including the serum fibrinogen, Factor X, albumin, and antithrombin III levels; platelet count; and serum osmolarity, may detect the simultaneous concentration of these factors before resistance to anticoagulation therapy develops. The role of adjunctive antiplatelet agents such as Dextran 40 may also be important but is still unproven.

TABLE 3. Selection of anticoagulants for short-term total artificial heart recipients: advantages vs. disadvantages

	Mechanism	Duration	Route	Acutely "reversible"	Ease of titration	Monitoring assay	Risk of bleeding at TXN
Heparin	Antithrombotic	30 min	i.v.	Yes	Yes	PTT WBaPTT	Minimal
Warfarin	Antithrombotic	3-5 days	p.o.	No	None	TT	Moderate
Aspirin	Antiplatelet	7-10 days	p.o.	No	None	PT BTG	High
Dipyridamole	Antiplatelet	6-8 h	p.o.	No	None	TX b ₂ , aggregation BTG	Moderate
Sulfinpyrazone	Antiplatelet	18 h	p.o.	No	None	TX b ₂ , aggregation ?	?
Dextran 40	Antiplatelet	6-12 h	i.v.	No	Minimal	None	Minimal

TXN, heart transplantation; PTT, partial thromboplastin time; WBaPTT, whole blood activated PTT; TXb₂, thromboxane b₂; TT, thrombin time; BTG, beta thromboglobulin.

REFERENCES

1. Olsen DB, Unger F, Oster H, Lawson J, Kessler T, Kolff J, Kolff WJ. Thrombus generation within the artificial heart. *J Thorac Cardiovasc Surg* 1975;70:248-55.
2. Hastings WL, Aaron JL, Deneris J, Kessler TR, Pons AB, Razzeca KJ, Olsen DB, Kolff WJ. A retrospective study of nine calves surviving five months on the pneumatic total artificial heart. *Trans Am Soc Artif Intern Organs* 1981;27:71-6.
3. Vasku MJ. Artificial heart: pathophysiology of the total artificial heart and of cardiac assist devices. Acta Facultatis Medicae Univ Brunensis, JE Purkyne University Brno, Medical Faculty, Brno, 1982:180-25.
4. Kessler TR, Pons AB, Jarvik RK, Lawson JH, Razzeca KJ, Kolff WF. Elimination of predilection sites for thrombus formation in the total artificial heart—before and after. *Trans Am Soc Artif Intern Organs* 1978;24:532-5.
5. Olsen DB, Kessler TR, Pons AB, Razzeca K, Lawson JH, Kolff WJ. Fabrication, implantation, and pathophysiology of the total artificial heart in calves for 6 months. In: Pierce WS, ed. *US-USSR Joint Symposium on Circulatory Assistance and the Artificial Heart, Tbilisi, USSR*. Washington, D.C., NIH publication No. 80-2032, 1981:3155.