

JNS 2697

Thalamic Hemorrhage with Neglect and Memory Disorder

Stephen G. Waxman, George A. Ricaurte and Scott B. Tucker

Department of Neurology, Stanford University School of Medicine, Veterans Administration Medical Center, Palo Alto, CA 94304 (U.S.A.)

(Received 5 February, 1986)

(Revised, received 21 March, 1986)

(Accepted 21 March, 1986)

SUMMARY

A patient with right thalamic hemorrhage developed left-sided hemi-inattention, indifference, motor neglect, and hypokinesia. He also developed a severe memory deficit at the time of hemorrhage. Observations in this patient suggest that, in addition to a syndrome of neglect and hypokinesia, an amnesic syndrome can arise from unilateral lesions involving the right thalamus.

Key words: *Hemorrhage – Hypokinesia – Memory disorder – Motor neglect – Thalamus*

INTRODUCTION

While hemi-inattention and neglect syndromes are most common following lesions of the parietal lobe, these abnormalities have also been reported following right thalamic hemorrhage (Watson et al. 1979; Cambier et al. 1980; Schott et al. 1980). Several previously reported patients with right thalamic hemorrhage were also noted to have a memory defect (Watson et al. 1979; Choi et al. 1983). However, most prior reports of thalamic memory disorder were derived from patients with bilateral thalamic lesions. In the unilateral cases reported by Watson and Heilman (1979), the authors were not certain that memory deficit did not antedate thalamic hemorrhage. In the case

This work was supported in part by the Medical Research Service, Veterans Administration.
Address for correspondence: Stephen G. Waxman, M.D., Ph.D., Department of Neurology, Yale Medical School, 333 Cedar Street, New Haven, CT 06510, U.S.A.

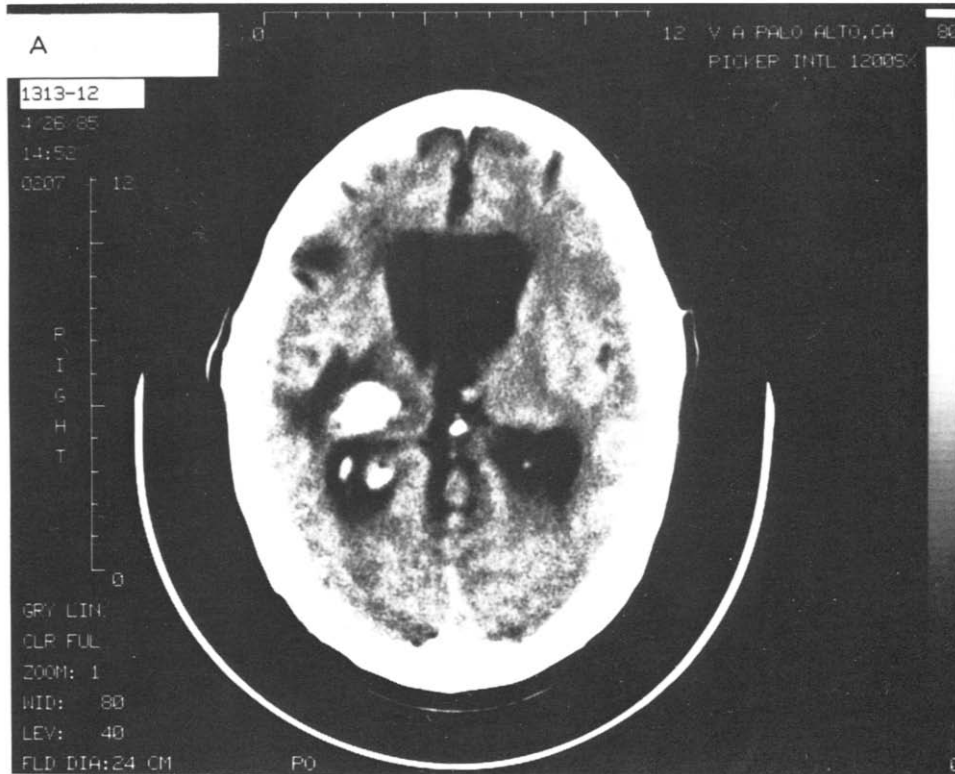


Fig. 1. *A*: CT scan, showing right thalamic hemorrhage several hours following patient's deterioration. *B*: Follow-up CT scan, obtained 3 weeks later. Lucency in right frontal lobe represents enlarged gyrus due to cerebral atrophy, and was present in prior CT scan obtained four months prior to development of thalamic hemorrhage.

of Choi et al. (1983), the authors pointed out that right thalamic hemorrhage occurred in the context of previous contralateral disease, and that it was thus not possible to address the relationship between unilateral lesions and memory disorders.

We have had the opportunity to observe a patient whose right thalamic hemorrhage evolved while in the hospital. This patient's course included the development of a syndrome characterized by left-sided hemisensory and motor neglect, hypokinesia, emotional flattening, and a severe memory deficit.

CASE REPORT

This 61-year-old right-handed white male was well until 4 months prior to admission, when he developed numbness on the left side of his body. CT scan revealed cerebral atrophy, but no infarction or hemorrhage was noted. Angiogram showed complete occlusion of the right internal carotid artery, with high grade stenosis of the left internal carotid artery. A left carotid endarterectomy was performed, and the patient was treated with aspirin and persantine. He did well until the day prior to admission, when he suddenly felt dizzy, vomited, and fell to the floor without losing consciousness.

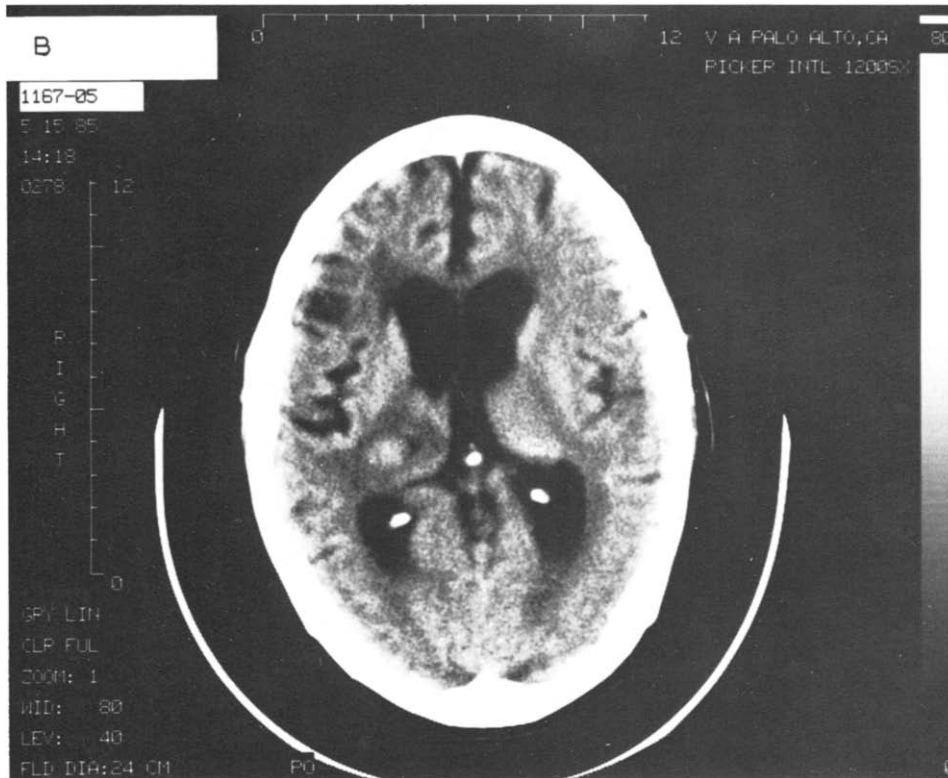


Fig. 1B

At this time, he noted worsening of residual numbness on the left side of the body. He also noted clumsiness of the left extremities, and developed an occipital headache.

On evaluation in the emergency room on the following day, the patient was awake and alert and his blood pressure was 160/90. The neck was supple, and there was a left carotid bruit. Neurological examination revealed normal mental status with intact memory, appropriate affect, and no inattention or neglect. There was intermittent extinction on the left on double simultaneous stimulation. Sensory examination was remarkable for decreased touch, pin prick, joint position, and vibration sense on the left side. Graphesthesia and stereognosis were also decreased on the left. Deep tendon reflexes were slightly increased on the left relative to the right, but plantar responses were flexor bilaterally. Motor examination was normal except for slightly decreased dexterity of the fingers on the left. The patient was admitted to the hospital.

Two days following admission, the patient vomited, his level of consciousness deteriorated over a period of several hours, and he became stuporous. Pupils were midsized and sluggishly reactive. A mild left hemiparesis and an extensor plantar response on the left developed. The patient was incontinent of urine. CT scan at this time revealed an intracerebral hemorrhage in the region of the right thalamus (Fig. 1). There was blood in the ventricles. The patient was treated with dexamethasone. Three

hours later, the patient became comatose, with decerebrate posturing in response to painful stimulation. Plantar responses were extensor bilaterally.

Two days later, the patient was awake, and was oriented to person but not to place or time. Speech was fluent and non-aphasic, with normal naming, repetition, and comprehension. Right-left orientation was intact. During this examination and over the subsequent 3 weeks, the patient was noted to be disoriented, with marked apathy and neglect on the left. His memory was grossly impaired.

On examination 3 weeks following admission, the patient was awake but markedly apathetic and indifferent. He expressed no concern when he was told that he had suffered a stroke. There was a paucity of spontaneous movements and facial expression. The patient was markedly hypokinetic, and would sit without any movements except blinking for periods of minutes. During these periods, the patient's eyes were open, and he would follow the examiner around the room with his gaze. These periods of immobility were punctuated by very slow (30 s to shift position) changes in posture after which the patient would again sit, statue-like, without moving. The patient moved very slowly in response to vigorous command, taking 30 s, for example, to rise from a chair, and 3–4 min to write a sentence. The patient did not resist passive movement, and on the contrary would maintain various postures into which he was placed. For example, if his arms were placed in an outstretched position or over his head, he would maintain this posture in a statue-like manner for several minutes, before slowly returning to a position of rest which he would maintain without moving.

The patient exhibited left-sided neglect. There was extinction on the left side in response to double simultaneous stimulation in the visual and tactile domains. The patient tended to move the left side much less than the right. Even in responding to

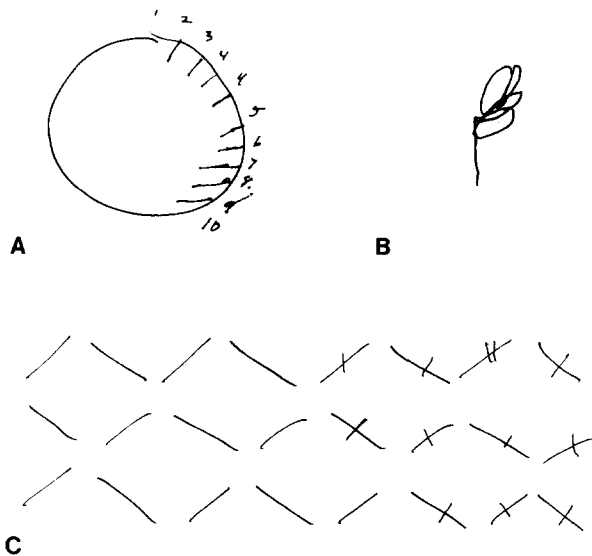


Fig. 2. *A*: Patient's attempt at drawing the numbers on a clock. *B*: Patient's attempt at copying a daisy. *C*: Line-crossing test (Albert 1973) as completed by patient. Note inattention on the left.

noxious stimuli on the left side of the body, he tended to use the right hand. However, with urging he could move the left side with as much facility as the right, and exhibited full strength. He wrote on the right one-half of the page neglecting the left, and repeatedly drew in numbers on the right half of a clock (Fig. 2A). He neglected the left side of the page on the line-crossing test (Albert 1973) (Fig. 2B). The patient copied only the right one-half of a daisy (Fig. 2C).

The patient's memory was severely impaired. He was not confused. He recalled zero out of 3 objects at 3 min and could not select the items from a list; cuing did not help. He could not recall a simple story after 3 min. He could not remember the names of his doctors. He did not recall the years of his induction into, or discharge from, military service, and did not remember that he had stopped smoking or that his brother had been sick. The patient appeared unconcerned about his memory deficit. Gross confabulation ("I saw you yesterday in church") was present.

Examination over the ensuing month showed only mild improvement, with persistence of left-sided hemi-inattention and motor neglect together with apathy, and with only slight improvement in his memory.

DISCUSSION

This 61-year-old right-handed man exhibited a clinical course which suggested thalamic hemorrhage (Walshe et al. 1977). CT scanning confirmed the presence of a hemorrhage in the right thalamus. The subsequent clinical picture included left-sided hemisensory neglect, left-sided motor neglect, hypokinesia, marked apathy, and a profound memory disorder. While this patient exhibited previous CT scan evidence of cortical atrophy and had a history of bilateral carotid disease with left carotid endarterectomy, the clinical course suggests that this acute clinical picture was related to the right thalamic hemorrhage.

Neglect syndromes most commonly arise in the context of disorders involving the parietal lobe (Critchley 1966; Denny-Brown and Banker 1974; Heilman et al. 1979). Human neglect syndromes have also been described with lesions of the frontal lobe (Heilman and Valenstein 1972; Damasio et al. 1980), cingulate gyrus (Watson et al. 1983), and putamen (Heir et al. 1977). The possibility that thalamic lesions could contribute to hemi-inattention syndromes was suggested by early ablation studies (Trevarthen 1968; Schneider 1969), which showed that the colliculus-pulvinar-parietal lobe pathway is involved in detection of, and orientation to, stimuli. Zeil and von Cramon (1979) studied visual function in a patient with a left pulvinar lesion. The most striking abnormality was neglect for the periphery of the visual hemifield contralateral to the lesion; there was also a paucity of spontaneous eye movements toward this hemifield, and prolonged latency of visually evoked saccadic eye movements toward this hemifield. Watson and Heilman (1979) described 3 patients with right thalamic hemorrhage who showed contralateral neglect, together with limb akinesia and emotional flattening. They suggested that an activation defect, possibly due to dysfunction of the intralaminar thalamic nuclei, was involved in this neglect syndrome. Cambier et al. (1980) described 2 additional patients with right thalamic hemorrhages in whom the

clinical picture was similar to that produced by non-dominant parietal lobe lesions; in these patients, there was constructional apraxia in addition to left-sided inattention.

Contralateral motor neglect has been described by several authors following thalamic lesions. Watson and Heilman (1979) described 'limb akinesia' with decreased spontaneous movements and a paucity of movement that was out of proportion to weakness, of the limbs contralateral to right thalamic hemorrhage. Similarly, transient reduction in the spontaneous use of the limbs contralateral to a thalamotomy (with preservation of motor function in response to command) has been reported (Zoll 1980). Schott et al. (1981) described motor neglect following right thalamic hemorrhage, with lack of spontaneous movements of the left side of the body (particularly the upper limb) in the context of preserved movement in response to verbal command. In each of these cases, preservation of response to command distinguishes the deficit from hemiparesis. This clinical picture is clearly illustrated in the present patient.

The present patient exhibited striking hypokinesia. Heilman et al. (1978) have studied hypoarousal in patients with neglect syndromes and emotional indifference due to right-hemisphere lesions. Observations of decreased galvanic skin responses were interpreted as suggesting that neglect is associated with disturbances in bilateral arousal which may, in part, be responsible for the apathy that accompanies some inattention syndromes. Interestingly, patient 3 of Watson and Heilman (1979) was noted to be hypokinetic. Apathy and indifference have also been described in association with neglect syndromes. The present patient exhibited all of these characteristics.

The patient described in this paper developed, while in the hospital, an amnesic syndrome, including anterograde and retrograde memory disorder together with confabulation. Since memory was intact prior to the patient's deterioration and memory deficit developed together with other signs of thalamic hemorrhage, it is probable that it developed as a result of this event. It is not possible, on the basis of the available radiographic evidence, to rule out damage to the fornix in this patient. It should be noted, however, that the available evidence from other patients indicate that lesions of the fornix do not necessarily produce memory loss in man (Umbach 1966; Woolsey and Nelson 1975). It might be suggested, therefore, that memory loss in the present patient reflects, at least in part, unilateral damage to the right thalamus.

On the basis of clinicopathological studies of patients with the alcoholic Wernicke-Korsakoff syndrome, Victor et al. (1971) suggested that bilateral lesions of the medial dorsal thalamus were responsible for memory disorder in these patients. McIntee et al. (1976) have more recently described a patient who developed severe memory disorder in association with bilateral tumor invasion of the medial and posterior thalamus, including medial dorsal nuclei. Similarly, Schott et al. (1980) described a case of anterograde memory disorder in a patient with bilateral lesions of the medial thalamus.

A number of recent studies have suggested the possibility that unilateral thalamic lesions might produce memory disorder. Geschwind and Fusillo (1966) and Benson et al. (1974) have described amnesic syndromes in patients with unilateral (left-sided) infarctions in the territory of the posterior cerebral artery. Several reports examine the relationship between left-sided thalamic lesions and memory deficits. Squire and Moore

(1979) have reported a remarkable case of severe verbal memory deficit secondary to a penetrating lesion of the diencephalon; in this case, CT scanning localized the lesion to the left dorsal thalamus, with no radiographic evidence of other damage in the diencephalon or cerebral cortex. These findings suggest that left thalamic dysfunction can interfere with the formation of verbal memory. Choi et al. (1983) described 3 patients who exhibited amnesia and confusion as presenting features of thalamic hemorrhage. In 2 of these patients, the hemorrhage was in the left thalamus, and there was no radiographic evidence of contralateral lesions. Both of these patients had severe memory deficits.

There are also several reports of right-sided thalamic lesions in patients with memory loss. A case of abrupt memory loss, associated with glioma with major involvement of the right thalamus, was reported by Ziegler et al. (1977). The patient displayed anterograde and retrograde memory loss without confabulation. However, while this latter case might be interpreted as suggesting a relationship between right thalamic lesions and memory disorder, bilateral invasion of the thalamus makes interpretation difficult. Similarly, case 3 of Choi et al. (1983) describes a patient with a right thalamic hemorrhage who exhibited memory loss without confabulation. However, as noted by the authors, previous contralateral disease makes it difficult to address the relationship between right-sided brain lesions and memory deficit on the basis of this case. In a previous report of right thalamic hemorrhage, Watson and Heilman (1979) noted memory defect in 2 out of 3 patients. In these cases there was no radiographic or pathological evidence for contralateral lesions. However, because the authors were uncertain that the memory defect did not antedate thalamic hemorrhage, they emphasized that they could not be certain about the relationship between memory defect and thalamic hemorrhage in these patients. Speedie and Heilman (1983) have described a patient with memory deficits for visuospatial material following infarction of the right thalamus. In this latter case, CT scan indicated a unilateral lesion involving the right thalamic nucleus, with encroachment into pulvinar and anterior and posterior lateral groups.

In the present case, memory was known to be intact prior to the patient's deterioration in the hospital. Memory loss developed with a time course similar to that of other signs of thalamic hemorrhage, and CT scan showed right thalamic hemorrhage without evidence of a contralateral lesion. In view of this, it appears probable that memory loss in the present patient is related to hemorrhage into the right thalamus. While the details of the mechanisms by which thalamic lesions lead to memory loss remain unstudied, it appears that unilateral lesions, affecting either the right or left thalamus, can contribute to memory deficits.

The present case illustrates the fact that relatively focal cognitive abnormalities can arise in the context of subcortical pathology. A syndrome of diffuse encephalopathy can be observed after nondominant thalamic infarction (Friedman 1985). However, right-sided thalamic hemorrhage may also produce a syndrome that includes neglect, hypokinesia, apathy, and memory disorder. In patients exhibiting this syndrome, the diagnosis of thalamic lesion must be considered.

REFERENCES

- Albert, M.L. (1973) A simple test of visual neglect, *Neurology*, 23: 658–664.
- Benson, D.F., C.D. Marsden and J.C. Meadows (1974) The amnesic syndrome of posterior cerebral artery occlusion, *Acta Neurol. Scand.*, 50: 133–145.
- Cambier, J., D. Elghozi and E. Strube (1980) Lésions du thalamus droit avec syndrome de l'hémisphère mineur — Discussion du concept de négligence thalamique, *Rev. Neurol. (Paris)*, 136: 105–116.
- Choi, D., L. Sudarsky, S. Schachter, M. Biber and P. Burke (1983) Medial thalamic hemorrhage with amnesia, *Arch. Neurol. (Chic.)*, 40: 611–613.
- Critchley, M. (1966) *The Parietal Lobes*, Hafner, New York.
- Damasio, A.R., H. Damasio and H.C. Chui (1980) Neglect following damage to frontal lobe or basal ganglia, *Neuropsychologia*, 18: 123–132.
- Denny-Brown, D. and B.Q. Banker (1954) Amorphosynthesis from left parietal lesions, *Arch. Neurol. (Chic.)*, 71: 302–313.
- Friedman, J.H. (1985) Syndrome of diffuse encephalopathy due to nondominant thalamic infarction, *Neurology*, 35: 1524–1526.
- Geschwind, N. and W. Fusillo (1966) Color-naming defects in association with alexia, *Arch. Neurol. (Chic.)*, 15: 137–146.
- Heilman, K.M. and E. Valenstein (1972) Frontal lobe neglect in man, *Neurology (Minneap.)*, 22: 660–664.
- Heilman, K.M., D.N. Pandya and N. Geschwind (1970) Trimodal inattention following parietal lobe ablations, *Trans. Amer. Neurol. Soc.*, 95: 259–261.
- Heilman, K.M., H.D. Schwartz and R.T. Watson (1978) Hypoarousal in patients with the neglect syndrome and emotional indifference, *Neurology*, 28: 229–232.
- Heir, D.B., K.R. Davis, E.P. Richardson et al. (1977) Hypertensive putaminal hemorrhage, *Ann. Neurol.*, 1: 152–159.
- McEntee, W.J., M.P. Biber, D.P. Perl and D.F. Benson (1976) Diencephalic amnesia — A reappraisal, *J. Neurol. Neurosurg. Psychiat.*, 39: 436–441.
- Schott, B., F. Mauguière, B. Laurent, O. Serclerat and C. Fischer (1980) L'amnésie thalamique, *Rev. Neurol. (Paris)*, 136: 117–130.
- Schott, B., B. Laurent, F. Mauguière and G. Chazot (1981) Négligence motrice par hématome thalamique droit, *Rev. Neurol. (Paris)*, 137: 447–455.
- Speedie, L.J. and K.M. Heilman (1983) Anterograde memory deficits for visuospatial material after infarction of the right thalamus, *Arch. Neurol. (Chic.)*, 40: 183–186.
- Squire, L.R. and R.Y. Moore (1979) Dorsal thalamic lesion in a noted case of human memory dysfunction, *Ann. Neurol.*, 6: 503–506.
- Trevarthen, C.B. (1968) Two mechanisms of vision in primates, *Psychol. Forsch.*, 31: 299–337.
- Umbach, W.L. (1966) Long-term results of fornicotomy for temporal lobe epilepsy, *Confin. Neurol.*, 27: 121–123.
- Victor, M., R.D. Adams and G.H. Collins (1971) *The Wernicke-Korsakoff Syndrome*, F.A. Davis, Philadelphia.
- Walshe, T.M., K.R. Davis and C.M. Fisher (1977) Thalamic hemorrhage — A computed tomographic-clinical correlation, *Neurology*, 27: 217–222.
- Watson, R.T. and K.M. Heilman (1979) Thalamic neglect, *Neurology*, 29: 690–694.
- Watson, R.T., K.M. Heilman, J.C. Cauthen and F.A. King (1973) Neglect after cingulectomy, *Neurology*, 23: 1003–1007.
- Woolsey, R.M. and J.S. Nelson (1975) Asymptomatic destruction of the fornix in man, *Arch. Neurol. (Chic.)*, 32: 566–568.
- Ziegler, D.K., A. Kaufman and H.E. Marshall (1977) Abrupt memory loss associated with thalamic tumor, *Arch. Neurol. (Chic.)*, 34: 545–548.
- Zihl, J. and D. Von Cramon (1979) The contribution of the 'second' visual system to directed visual attention in man, *Brain*, 102: 835–856.
- Zoll, J.G. (1969) Transient anosognosia associated with thalamotomy — Is it caused by proprioceptive loss? *Confin. Neurol.*, 31: 48–55.