

Demonstration of Superior Sagittal Sinus Thrombosis by Indium-111 Platelet Scintigraphy

Samuel L. Bridgers, MD; Edward Strauss, MD; Eileen O. Smith; Douglas Reed, MD; Michael D. Ezekowitz, MD, PhD

• Superior sagittal sinus thrombosis, documented by cerebral angiography, was demonstrated by indium-111 platelet scintigraphy in a 40-year-old man presenting with seizures and intracerebral hematoma. Early scintigraphy demonstrated focal increased indium-111 activity at the two ends of the thrombus, while later scintigraphy showed diffuse increased activity in the area of the sinus. This initial experience suggests that platelet scintigraphy may provide unique information regarding the natural history of intracranial venous thrombosis.

(*Arch Neurol* 1986;43:1079-1081)

Indium-111 platelet scintigraphy has been used successfully for the detection of peripheral and intracardiac thrombosis.^{1,2} There has been only limited experience, however, in the diagnosis of intracranial thrombosis.^{3,5} We report the demonstration of superior sagittal sinus thrombosis by platelet scintigraphy in a case where contrast-enhanced computed tomography (CT) failed to yield the diagnosis.

REPORT OF A CASE

A 40-year-old man was transferred to the Veteran's Administration Medical Center, West Haven, Conn, after the discovery of a left parietal intracerebral hematoma on CT at another hospital, where he had been taken after a seizure earlier in the day. The patient suffered two more generalized seizures in the emergency room of the first hospital, and was treated with intravenous phenytoin sodium and diazepam. Over the course of the day, he also reported a worsening bifrontal headache.

The patient, a chronic alcoholic acknowledging consumption of a quart of whiskey daily for several months, had a history of lumbar radiculopathy but no other prior neurologic complaints. During an episode of bronchopneumonia treated at another hospital 2½ years earlier, a question of

bilateral lower extremity deep-vein thrombosis had been raised, but the diagnosis was never confirmed, and the patient's symptoms resolved without anticoagulant therapy.

Neurologic examination on arrival at the Veteran's Administration Medical Center was remarkable only for right upper extremity apraxia unaccompanied by frank weakness, reflex changes, or sensory deficit. Cognitive and language functions were intact. Fundoscopic examination was unremarkable. The patient was mildly tremulous.

The patient continued to receive phenytoin, and was also given sedatives for incipient alcohol withdrawal. He persisted with headache during his early hospitalization and had several episodes of vomiting. On day 2, he underwent contrast-enhanced CT (Fig 1), which demonstrated the known hematoma and surrounding edema. No lucency was noted in the superior sagittal sinus. On day 4, the patient developed frank weakness of the right upper extremity and a right Babinski's sign after an episode of vomiting. Repeat noncontrast CT showed a possible extension of the hemorrhage and more pronounced edema. Dexamethasone acetate therapy was initiated. On day 5, cerebral angiography was performed. Selective left internal carotid artery injection was remarkable in the arterial phase only for mass effect, while the venous phase revealed no filling of the superior sagittal sinus (Fig 2). The patient underwent two series of scintigraphic studies following injection of labeled autologous platelets on day 6 and day 14 (see below).

The patient's subsequent hospital course was unremarkable. He was not treated with antiplatelet or anticoagulant agents. His headache gradually resolved, as did his right upper extremity deficit. Repeated CT on day 29 showed some resolution of the hemorrhage and edema. Lumbar puncture performed on day 30 was remarkable only for an opening pressure of 270 mm cerebrospinal fluid (CSF).

On admission, the patient's platelet count, prothrombin time, and partial thromboplastin time were normal, and these remained so throughout the hospitalization. In addition, bleeding time, thrombin time, antithrombin III activity, erythrocyte sedimentation rate, antinuclear antibody titer, complement levels, and lipoprotein electrophoresis were unremarkable.

Platelet Scintigraphy

Platelets were labeled according to a previously described modification⁶ of the method of Heaton et al,⁷ which was derived from that of Thakur et al.⁸ The process involves separation of platelets from a

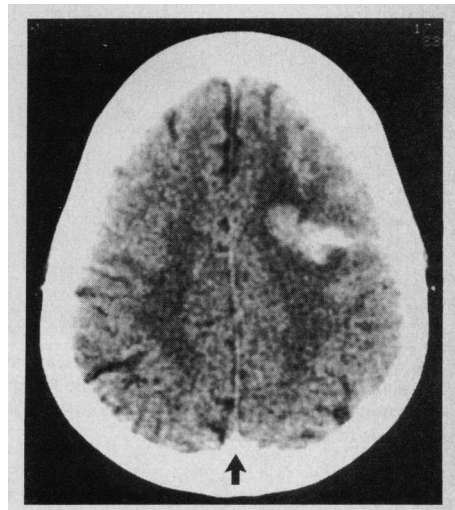


Fig 1.—Computed tomography. Contrast-enhanced computed tomographic scan performed on day 2 shows left parietal hemorrhage and surrounding edema, but there is no lucency or "open delta" sign in superior sagittal sinus (arrow) to suggest thrombosis.

citrated 43-mL sample of autologous blood, incubation with indium-111-oxine complex (Amersham) for labeling, and resuspension in platelet-poor plasma for reinjection. After provision of informed consent, this patient underwent two labeled platelet injections, as previously noted, both involving approximately 200 microcuries of indium-111 activity. Following both injections, ten-minute images were obtained at 24 and 48 hours, using a small-field gamma camera with medium-energy parallel-hole collimator set on both energy peaks of indium-111 with 20% windows (Fig 3). Lateral and posterior images obtained 24 hours after the injection on day 6 showed two foci of intense indium-111 activity in the area of the superior sagittal sinus, presumed to represent the two ends of the thrombus, while a 48-hour posterior image revealed a diffuse increase in activity in the sinus. A similar, but less pronounced, diffuse increase in activity was seen following the second labeled platelet injection on both 24- and 48-hour images.

COMMENT

In this case, platelet scintigraphy, while not used to make the diagnosis, provided a dramatic demonstration of the superior sagittal sinus thrombosis. Two previous reports have suggested that this diagnosis could be made using platelet scintigraphy, but neither provided confirmation by angiography, computed tomography,

Accepted for publication June 23, 1986.

From the Veterans Administration Medical Center, West Haven, Conn (Drs Bridgers, Strauss and Ezekowitz, and Ms Smith); the Departments of Neurology (Dr Bridgers), Medicine (Dr Ezekowitz and Ms Smith), and Diagnostic Radiology (Drs Strauss, Reed, and Ezekowitz), Yale University School of Medicine, New Haven, Conn.

Reprint requests to Neurology Service (127), Veterans Administration Medical Center, West Spring street, West Haven, CT 06516 (Dr Bridgers).

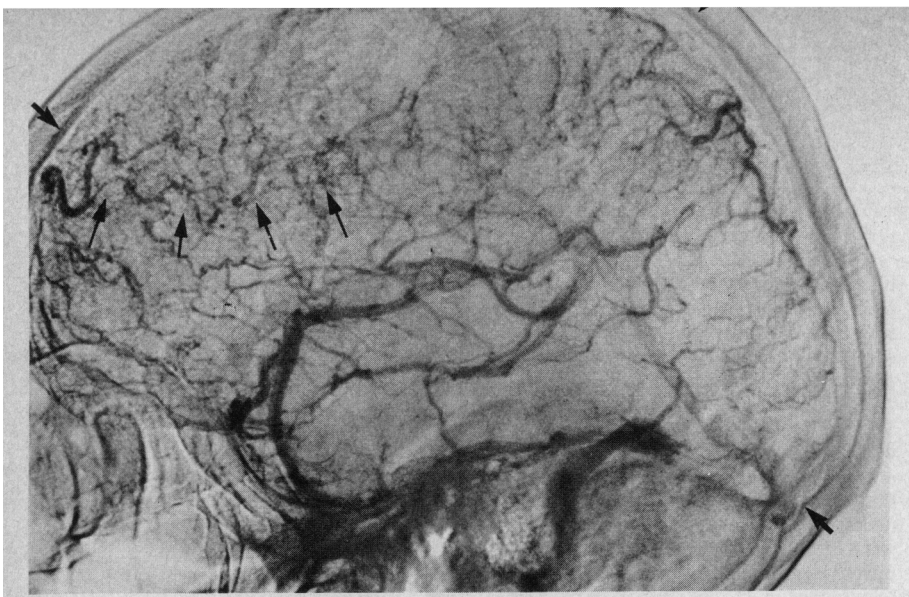
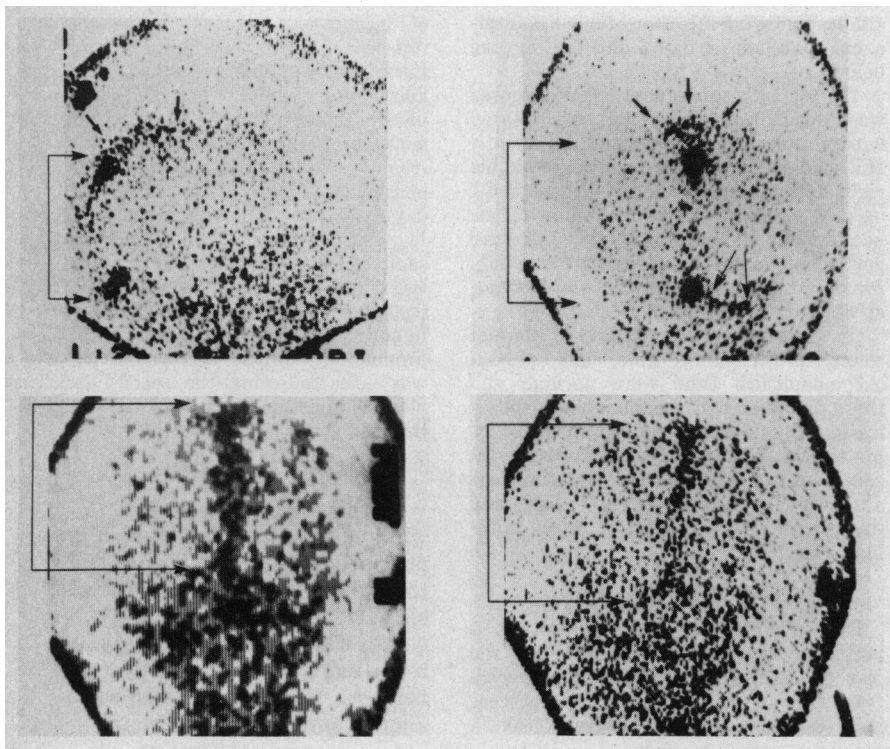


Fig 2.—Cerebral angiography. Lateral view in venous phase after transfemoral left internal carotid artery contrast injection shows no filling of superior sagittal sinus (large arrows). Marked enlargement of deep medullary veins (area demarcated by small arrows) represents collateral flow due to sinus occlusion.

Fig 3.—Platelet scintigraphy. Top left, Right lateral ten-minute image obtained on day 7 of patient's illness, 24 hours after injection of indium-111 labeled autologous platelets. Occiput is on left side of image. Two foci of intense indium-111 activity are seen, posterior to vertex and near region of torcular Herophili (connected arrows). Less intense but still increased activity extending forward in superior sagittal sinus (unconnected arrows) could represent less active thrombosis or blood pooling. Halo surrounding image in this and subsequent scintigraphs is "edge-packing" artifact, consequence of physical characteristics of collimator shielding and duration of imaging. Total counts equal 34K. Top right, Corresponding posterior ten-minute image. Intense foci are indicated by connected arrows, and less clearly abnormal but increased activity in sinus are indicated by upper unconnected arrows. Similar moderately increased activity is noted in right transverse sinus (lower unconnected arrows). Again, this may represent extension of thrombus. Total counts equal 37K. Bottom left, Posterior ten-minute image obtained 48 hours after first injection. Diffuse increased activity is evident in region of superior sagittal sinus (connected arrows). Total counts equal 27K. Bottom right, Posterior ten-minute image obtained on day 15, 24 hours after second injection of labeled platelets. Now, only slight diffuse increase in activity is evident in region of superior sagittal sinus between connected arrows. Total counts equal 29K.



or autopsy.^{3,4} In our case, angiography established the existence of sinus occlusion. In both of the previous cases, apparent diffuse increase in indium-111 activity in the sinus was seen, similar to the second sequence of images obtained in our patient; both studies were performed approximately two weeks after ictal events. Since labeled platelets not incorporated into thrombus or sequestered in the spleen remain in the blood pool, the interpretation of diffuse increased activity in a large vascular structure such as the superior sagittal sinus must be approached with caution when dual-isotope subtraction techniques are not used. By obtaining platelet scintigraphy earlier in the patient's course, we successfully demonstrated active focal platelet uptake at the two ends of the thrombus. The later demonstration of diffuse uptake may imply patency of the sinus inapparent at angiography. Clarification of the role of blood-pool activity in such situations can be achieved with dual-isotope scintigraphy using technetium-99m-labeled red blood cells as well as labeled platelets.⁵ Subtraction of the technetium-99m scintigram allows correction for the blood pool's influence on indium-111 activity.

The described CT signs of sagittal sinus occlusion, while useful when present, are too frequently absent to allow CT to be used in isolation for exclusion of this diagnostic possibility.^{9,10} Our experience suggests that platelet scintigraphy could join digital intravenous angiography¹¹ and magnetic resonance imaging¹² as an alternative means to diagnose cerebral venous occlusion, as well as an ancillary procedure to differentiate new thrombosis from either older thrombus or nonthrombotic occlusion. Clearly, more experience will be necessary to determine just what the role of this technique should be.

Sagittal sinus thrombosis is an uncommon entity, and little is known about the temporal evolution of the thrombotic process. Our experience suggests that platelet scintigraphy can provide unique information regarding natural history. Without antithrombotic therapy, labeled platelet uptake declined markedly over the two weeks after this patient's original presentation, suggesting that active thrombosis likewise declined in the interval. In light of continuing controversy concerning the use of anticoagulants in the treatment of this disorder,¹⁰ such information may eventually prove useful in determining the need for therapy.

Supported by the Medical Research Service, US Veterans Administration.

References

1. Ezekowitz MD, Wilson DA, Smith EO, et al: Comparison of indium-111 platelet scintigraphy and two-dimensional echocardiography in the diagnosis of left ventricular thrombi. *N Engl J Med* 1982;306:1509-1513.
2. Powers WJ, Siegel BA: Thrombus imaging with indium-111 platelets. *Semin Thromb Hemost* 1983;9:115-131.
3. Kessler C, Kniffert T, Botsch H: Der Nutzen der Plattchenszintigraphie zur Aufklärung intrakranieller vaskularer Prozesse. *Aktuel Neurol* 1980;7:27-29.
4. Kessler C, Trabandt R: Thromboszintigraphie mit 111-Indium. *Arch Psychiatr Nervenkr* 1982;231:449-457.
5. Sutherland GR, King ME, Peerless SJ, et al: Platelet interaction with giant intracranial aneurysms. *J Neurosurg* 1982;56:53-61.
6. Ezekowitz MD, Leonard JC, Smith EO, et al: Identification of left ventricular thrombi in man using indium-111 labeled autologous platelets. *Circulation* 1981;63:803-810.
7. Heaton WA, Davis HH, Welch MJ, et al: Indium-111: A new radionuclide label for studying human platelet kinetics. *Br J Haematol* 1979;42:613-622.
8. Thakur ML, Welch MJ, Joist JH, et al: Indium-111 labeled platelets: Studies on preparation and evaluation of in vitro and in vivo functions. *Thromb Res* 1976;9:345-357.
9. Rao KCVG, Knipp HC, Wagner EJ: CT findings in cerebral sinus and venous thrombosis. *Radiology* 1981;140:391-398.
10. Bousser M, Chiras J, Bories J, et al: Cerebral venous thrombosis: A review of 38 cases. *Stroke* 1985;16:199-213.
11. Barnes BD, Brant-Zawadzki M, Mentzer W: Digital subtraction angiography in the diagnosis of superior sagittal sinus thrombosis. *Neurology* 1983;33:508-510.
12. Cascino TL, Wiebers DO, Forbes GS: Digital subtraction angiography and NMR scanning for diagnosing dural sinus thrombosis in tumor patients. *Neurology* 1984;34(suppl 1):85.

High-Field Magnetic Resonance Imaging in the Diagnosis of Cavernous Sinus Thrombosis

Peter J. Savino, MD; Robert I. Grossman, MD; Norman J. Schatz, MD; Robert C. Sergott, MD; Thomas M. Bosley, MD

Cavernous sinus thrombosis is an important but difficult clinical diagnosis to confirm by most imaging modalities.^{1,2} Until the advent of high-field magnetic resonance imaging (MRI), the imaging method of choice for evaluating thrombus formation in the cavernous sinus was transarterial or intravenous digital subtraction angiography. This article discusses the MRI findings in the diagnosis of cavernous sinus thrombosis.

REPORT OF A CASE

A 73-year-old woman noticed pain around her left eye ten days before examination. Over the next four days, her left upper eyelid drooped, and she experienced double vision. She was hospitalized elsewhere, and computed tomography (CT) showed a mass in the left anterior cavernous sinus. A cerebral arteriogram was normal. The patient was treated with systemic corticosteroids (prednisone, 80 mg/d), with no resolution of the pain or ocular motility disturbance.

Five years prior to admission, the patient had an episode of painful ophthalmoplegia that was described as a partial third and total sixth cranial nerve palsy on the left side. She had 3 mm of left ptosis, absent left medial and lateral rectus function, but good vertical movement and preserved intorsion on attempted downward

gaze. The pupil was normal. This gradually resolved over several months, and the patient's final resolution was described as a 14-prism-diopter esotropia in extreme left and right gaze. She stated that she had had four of these episodes prior to the present one, with resolution of each within days to weeks.

The patient's visual acuity was 6/7.5 OD and 6/9+1 OS. Results of exophthalmometry at base 103 were 15 OD and 16 OS. She had complete immobility of the left eye except for intorsion on attempted downward gaze. The left pupil was dilated and did not react to light, but there was no relative afferent pupillary defect. Fundus examination showed no abnormality, and visual fields were full. Neurologic examination showed only decreased corneal sensation on the left side.

Further investigation included a search for collagen vascular as well as metastatic disease. Findings from a mammography and two lumbar punctures were normal. A CT scan with intravenous contrast enhancement revealed bulging of the lateral margin of the left cavernous sinus, suggesting a mass lesion (Fig 1).

The MRI scan, performed the day after the CT scan, showed a serpiginous structure with hyperintensity on T1- and T2-weighted images (WI) representing the thrombosed posterior portion of the superior ophthalmic vein (Fig 2). Thrombus formation was also demonstrated as high-signal abnormality on T1WI in the anterior portion of the cavernous sinus (Fig 3).

The specific findings of cavernous sinus thrombosis on MRI permitted corticosteroid therapy to be discontinued. The patient was discharged without medication with a diagnosis of thrombosis in the left anterior cavernous sinus and superior ophthalmic vein, most likely from a dural vascular malformation. When last examined four months after the present episode, there was no change in ocular findings.

COMMENT

This patient presented with dysfunction of cranial nerves III, IV, V₁, and VI, indicating a lesion of the cavernous sinus or superior orbital fissure. Pathologic conditions that produce this syndrome may be intrinsic cavernous sinus mass lesions (aneurysm or meningioma) or masses from adjacent structures (pituitary adenoma or chordoma).³ Metastatic lesions may also produce a cavernous sinus syndrome.⁴ Inflammation in this area (Tolosa-Hunt syndrome) may be indistinguishable from mass lesions but usually produces more pain. These inflammatory processes typically respond dramatically to systemic corticosteroid therapy.⁵

Our patient had no history of neoplastic disease, and none was detected on evaluation. The lack of response to

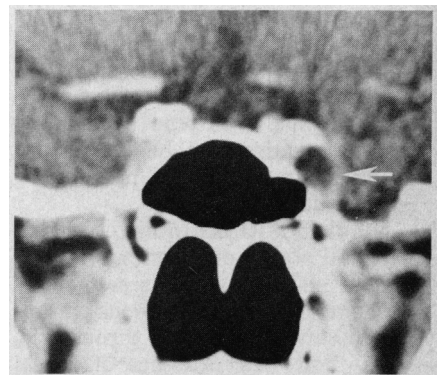


Fig 1.—Contrast-enhanced coronal computed tomographic scan demonstrating bulging of left cavernous sinus by nonenhancing mass (arrow).

Accepted for publication May 19, 1986.

From the Neuro-Ophthalmology Service, Wills Eye Hospital, Thomas Jefferson University (Drs Savino, Schatz, Sergott, and Bosley), and the Department of Radiology, Hospital of the University of Pennsylvania (Dr Grossman), Philadelphia.

Reprint requests to Wills Eye Hospital, Ninth and Walnut streets, Philadelphia, PA 19107 (Dr Savino).