

sions. These histological, immunohistochemical and electronmicroscopical studies suggest that varicella-zoster-virus may be the cause of granulomatous angiitis in the central nervous system. The mechanism of aneurysm formation and rupture is not clear, but necrosis of the vascular wall with giant cell reaction does play an important role in this course. Thus, clinicians should be aware of the granulomatous angiitis in the central nervous system in patients with herpes zoster.

References

- Cravioto H, Feigin H: Noninfectious granulomatous angiitis with a predilection for the nervous system. *Neurology (Minneapolis)* 9: 599-608, 1959
- Gilbert GJ: Herpes zoster ophthalmicus and delayed contralateral hemiparesis. Relationship of the syndrome to central nervous system granulomatous angiitis. *JAMA* 229: 302-304, 1974
- Rosenblum WI, Hadfield MG, Young HF: Granulomatous angiitis with preceding varicella zoster. *Ann Neurol* 3: 374-375, 1978
- Rosenblum WI, Hadfield MG: Granulomatous angiitis of the nervous system in cases of herpes zoster and lymphoma. *Neurology* 22: 348-354, 1972
- Linnemann CC, Alvira MM: Pathogenesis of varicella-zoster angiitis in the CNS. *Arch Neurol* 37: 239-240, 1980
- Reyes MG, Fresco R, Chokroverty S, Salud EQ: Virus-like particles in granulomatous angiitis of the central nervous system. *Neurol* 26: 797-799, 1976
- Guesdon JL, Ternynk T, Avrameas S: The use of avidin-biotin interaction in immunoenzymatic techniques. *J Histochem Cytochem* 27: 1131-1139, 1979
- Hsu SM, Raine L, Fanger H: The use of avidin-biotin-peroxidase complex (ABC) in immunoperoxidase techniques: A comparison between ABC and unlabeled antibody (PAP) procedure. *J Histochem Cytochem* 29: 577-580, 1981
- Kolodny EH, Rebeiz JJ, Caviness Jr CVS, Richardson Jr EP: Granulomatous angiitis of the central nervous system. *Arch Neurol* 19: 510-524, 1968
- Hughes JT, Brownell B: Granulomatous giant-celled angiitis of the central nervous system. *Neurology (Minneapolis)* 16: 293-298, 1966
- Naumann G, Donald JMG, Font RL: Histopathology of herpes zoster ophthalmicus. *Am J Ophthalmol* 65: 533-541, 1968
- Budzilovich GB, Feigin I, Siegel H: Granulomatous angiitis of the central nervous system. *Arch Pathol* 76: 250-256, 1963
- Nurick S, Blackwood W, Mair WGP: Giant cell granulomatous angiitis of the central nervous system. *Brain* 95: 133-142, 1972
- Liang G, Simkin PA, Mannik M: Immunoglobulins in temporal arteritis. Immunofluorescent study. *Ann Int Med* 81: 19-24, 1974
- Arthur G, Margolis G: Mycoplasma-like structures in granulomatous angiitis of the central nervous system: case reports with light and electron microscopic studies. *Arch Pathol Lab Med* 101: 382-387, 1977

Progressive Lacunar Infarction With Demonstrated Patency of the Middle Cerebral Artery

JAMES H. HALSEY, M.D.

SUMMARY Two cases of progressive hemiplegia were closely followed by daily clinical examination. In both, the CT scan and CSF were normal on admission. In both, objective aggravation occurred in three or more steps over four days, progressing from minor finger clumsiness to total paralysis of the arm. In both cases a second CT scan a day after appearance of hemiplegia demonstrated a lacune in the corona radiata just above the internal capsule. In one case an intravenous digital subtraction angiogram demonstrated patency of the middle cerebral artery during the course of the progression. In the other case, serial study with transcranial Doppler ultrasound documented the continued patency of the middle cerebral artery. These two cases demonstrate that it is not necessary to postulate transient occlusion of the middle cerebral artery as an essential mechanism for progressive lacunar infarction.

Stroke Vol 17, No 5, 1986

THE TERM LACUNE refers to a small infarction of the basal ganglia, internal capsule, or brain stem. Characteristic clinical syndromes which are highly predictive of the anatomical lesion have been described by Fisher.¹ The subject has recently been definitively reviewed by Mohr.² The lesion is usually attributed to occlusion of a penetrating end arterial branch of one of the major vessels of the circle of Willis or basilar artery. The evidence for this is usually an inference from the appearance of the lesion on CT

scan or at autopsy,³ though the occluded vessel itself has been recovered by very careful painstaking examination of serial sections in some cases.^{1,2}

Mohr, in his article, emphasized the frequency of a progressive evolution in many cases, sometimes with a time course of up to 48 hours or more.² The underlying lesion in these has often remained speculative since arteriography performed later, or subsequent autopsy, could not take account of the possibility of transient occlusion of a large parent artery with subsequent spontaneous clot lysis.

As a contribution to this issue we wish to present two similar cases in whom serial neurologic examination documented progressive evolution from minor hemiparesis to total hemiplegia, while intravenous digital subtraction angiography in one, and ultrasound in the other clearly documented that the horizontal portion of the middle cerebral artery was patent during

From the Department of Neurology and Stroke Research Center, University of Alabama Medical Center, Birmingham, Alabama 35294.

This work was supported in part by grants #NS088802 and #AG05014.

Address correspondence to: James H. Halsey, M.D., Department of Neurology, The University of Alabama at Birmingham, 1919 7th Avenue South, Birmingham, Alabama 35294.

Received November 20, 1985; accepted January 9, 1986.

the period of clinical progression. In both cases, the CT scan was normal on admission, but on the day after the hemiplegia had become complete, repeat CT scan revealed an appropriately located lacune in the corona radiata just above the internal capsule.

Case Reports

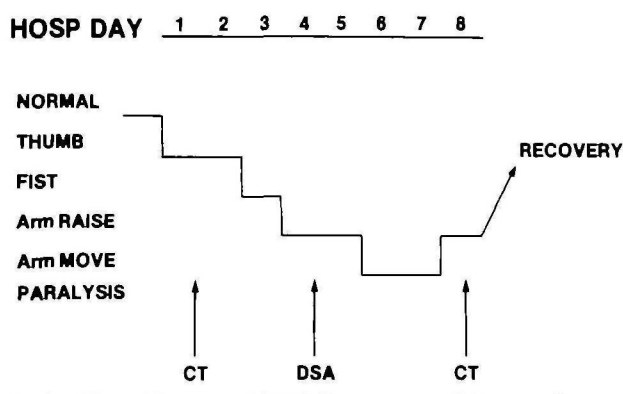
Case 1

An 80 year old black male was admitted 12 hours after onset of right hand weakness. Initial examination on day 1 revealed that though he could open and close the fist, he could not oppose the thumb to the fingers of the right hand. He was the same on day 2, but on day 3 he could not open and close the fist. He could hold the arm in the air and lift his foot from the bed. On day 4 he had great difficulty lifting his arm from the bed. He was unable to extend the elbow completely nor to lift the leg from the bed. There was no change on day 5 but on day 6 he became unable to lift his elbow from bed but he could move his arm in bed. He could not lift his foot from bed even if the knee was supported. No change occurred the next day. Thereafter he began to make steady recovery, becoming able to walk on the 12th day and to hold a cup in his hand. One month later examination revealed no abnormality (fig 1).

CT scan was normal on admission. When repeated on day 8 it revealed a lacune in the corona radiata of the left hemisphere (fig 2). On day 4 intravenous digital subtraction angiography showed a patent carotid siphon and horizontal segment of middle cerebral artery. Ultrasound image and Doppler spectrum of the carotid bifurcation were normal.

Case 2

A 75 year old white woman was admitted 18 hours after occurrence of right hand weakness. The next day she had difficulty opposing the thumb to the fingers successively. On day 2 she could not lift the arm from the bed though she could move it in bed. On day 3 she was capable of only flicker contraction of the biceps muscle. Thereafter strength progressively returned



PROGRESSIVE LACUNAR HEMIPARESIS

FIGURE 1. Case 1. Summary of the course of clinical disability and timing of the studies.

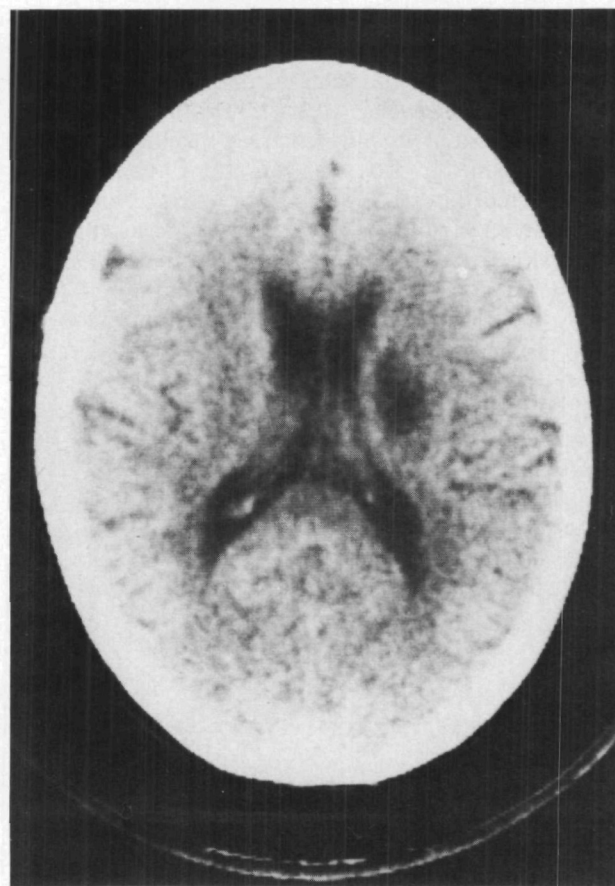

FIGURE 2. Case 1. CT scan on day 8 demonstrating lacune in the corona radiata.

such that by discharge at day 12 she could still not oppose the thumb to the fingers but strength was otherwise normal.

CT scan was normal on admission. When repeated on day 4 it revealed a lacune in the corona radiata of the left hemisphere, virtually identical to that of case 1. Through the course of the illness, the velocity of pulsatile flow in the middle cerebral arteries was studied according to the method of Aaslid et al, using the TECA TE 2-64 transcranial Doppler recorder, operating at 2.0 MHz. This was repeated daily. On each occasion the velocity was normal 30–50 cm/sec on the right, but moderately increased on the left 60–90 cm/sec.

Discussion

Both cases were treated with heparin and glycerol and received IV fluids throughout the course of progression and recovery. Because of this and normal routine laboratory work, hyperviscosity seems an unlikely cause of the progressive disability. Since in both cases the blood pressure was measured frequently and maintained in the range 140–160/75–90, hypotension also can reasonably be excluded. In the first case the intravenous digital subtraction angiogram was performed in close proximity to an episode of progression and followed by further progression so it is unlikely that an occlusion could have been present and then

lysed. With a little lower certainty we can also exclude the carotid siphon and carotid bifurcation as sources of recurrent emboli to the same location. The most reasonable interpretation is that the whole process was due to occlusion of one (or a few) lenticulo-striate vessels which the DSA was not sensitive enough to visualize. In the second case, the increased middle cerebral arterial flow velocity might be consistent with stenosis of the artery. However the art of intracranial vascular diagnosis by Doppler ultrasound is in its infancy, and reliable only as a qualitative index of the presence of flow. But this simple fact is the fundamental point of the presentation: That flow through the full length of the horizontal portion of the middle cerebral artery was repeatedly demonstrated during the clinical progression of disability.

What could have been the mechanism of the clinical progression? Of course we cannot know if the postulated lenticulo-striate arterial thrombus propagated or was static during the period of clinical progression.

Edema would be a very unattractive hypothesis: The ultimate lesion in each case was so small that it is difficult to envision enough change in local tissue pressure to affect local flow. Moreover both patients remained completely alert during the whole process. No ventricular distortion was evident on the second CT scan in either case. Though a definitive elucidation of the mechanism of progressive lacunar stroke is not yet possible, the negative conclusion is now clear: It is not necessary to postulate occlusion of the parent middle cerebral artery.

References

1. Fisher CM, Curry HM: Pure motor hemiplegia of vascular origin. *Arch Neurol* 13: 30-44, 1965
2. Mohr JP: Lacunes. *Stroke* 13: 3-11, 1982
3. Rascol A, Clanet ML, Manelfe C, Guiraud B, Bonafe A: Pure motor hemiplegia: CT study of 30 cases. *Stroke* 13: 11-17, 1982
4. Aaslid R, Markwalder T-M, Nornes H: Noninvasive transcranial Doppler ultrasound recording of flow velocity in basal cerebral arteries. *J Neurosurg* 57: 769-774, 1982

Horizontal Gaze Paresis in Hemispheric Stroke

ROGER E. KELLEY, M.D.,* AND ANDREW G. KOVACS, M.D.†

SUMMARY Of 156 stroke patients prospectively and consecutively evaluated, one-third had a homonymous hemianopia. Of those 52 patients, 46% had a horizontal conjugate gaze paresis at the time of presentation. This gaze paresis was most commonly seen with large hemispheric stroke. The overall prognosis in patients with a gaze paresis was poor. The 30-day case fatality rate was 49% which was significantly higher than for stroke patients presenting with homonymous hemianopia without a gaze paresis.

Stroke Vol 17, No 5, 1986

WE FOUND HOMONYMOUS HEMIANOPIA (HH) to be the most common neuro-ophthalmological manifestation of stroke in a prospective, consecutive series of patients. A significant number of these patients (46%) had an initial gaze paresis with conjugate, horizontal eye deviation toward the involved hemisphere. HH is most commonly caused by cerebrovascular disease.¹ It results from a lesion of either the optic tract, lateral geniculate body, optic radiation or calcarine cortex. Horizontal gaze paresis, on a hemispheric basis, is usually attributed to a destructive lesion of the contralateral frontal eye field (FEF).² Typically, the patient looks toward the lesion and this has been interpreted as representing a visual neglect.³ Such a gaze paresis does not have to be associated with a visual field defect as shown by experimental studies in which a discrete lesion was produced in the FEF of the monkey.⁴ On the other hand, we found that moderate to large strokes are often associated with HH and a con-

comitant gaze paresis. The purpose of our study is to assess whether or not the combination of these two neuro-ophthalmological findings in hemispheric stroke had prognostic significance.

Materials and Methods

We prospectively and consecutively assessed 156 patients with completed stroke admitted to Temple University Hospital over an eight month period. All patients were personally examined by the authors within 24 hours of presentation and computed tomographic (CT) brain scan was performed in all patients with a followup scan in one-third. Each patient had an assessment of visual acuity and visual fields when neurological status allowed this. Confrontation visual field techniques included finger counting and color comparison with each eye tested separately. Response to threat in each eye was utilized in obtunded patients. We also assessed pupillary size, pupillary response to light and accommodation, direction of gaze, extraocular motility, and optokinetic response. Evaluation of oculoccephalic reflex and cold caloric response was performed when appropriate.

Patients were followed an average of 76 days for survivors and 23 days for nonsurvivors. Serial medical

From the Department of Neurology,* University of Miami School of Medicine, Miami, Florida; and †Temple University Hospital, Philadelphia, PA.

Address correspondence to: Roger E. Kelley, M.D., Department of Neurology (D4-5), 1501 N.W. 9th Avenue, Miami, FL 33136.

Received July 23, 1985; revision #1 accepted December 5, 1985.