

# Contrapulsion of Saccades and Ipsilateral Ataxia: A Unilateral Disorder of the Rostral Cerebellum

Paul J. Ranalli, MD, and James A. Sharpe, MD

---

Contralateral pulsion of saccades and ipsilateral limb ataxia were manifestations of unilateral damage to the rostral cerebellum studied in a patient with occlusion of one superior cerebellar artery. The saccadic disorder consisted of three elements: (1) horizontal saccades away from the lesion during attempted vertical saccades, resulting in oblique trajectories; (2) hypermetria of contralateral saccades; and (3) hypometria of ipsilateral saccades. Magnetic search coil oculography showed that durations of the horizontal components of oblique contrapulsive saccades were lengthened toward the durations of the vertical components. Lengthening of horizontal vectors indicated temporal coupling of the orthogonal components, as occurs in normal oblique saccades. The bias of saccades arose proximal to brainstem loci that decompose commands for oblique saccades into their horizontal and vertical vectors. Contrapulsion of saccades may be explained by imbalanced cerebellar outflow.

Ranalli PJ, Sharpe JA: Contrapulsion of saccades and ipsilateral ataxia: a unilateral disorder of the rostral cerebellum. *Ann Neurol* 20:311-316, 1986

---

The role of specific regions of the cerebellum in the control of eye movements has not been precisely defined in human beings. Studies have concerned diffuse cerebellar degenerations [22], encephalopathies [5], demyelination [18], and large masses [17]. The skeletal motor deficits resulting from focal cerebellar strokes are well recognized [4, 7, 9], but detailed analysis of eye movement abnormalities is lacking.

Infarction of the lateral medulla causes a horizontal bias of saccades and limb and trunk movements termed *lateropulsion* [2, 3, 12]. In the lateral medullary syndrome the saccadic bias is directed toward the side of the lesion. We now describe a motor disorder caused by infarction in the distribution of the superior cerebellar artery. In this disorder, which we call *contrapulsion*, the vector of saccadic bias is away from the side of rostral cerebellar damage.

## Patient and Methods

A 17-year-old female student had had episodic bitemporal throbbing headaches over the previous year after starting oral contraceptive pills. Headaches lasted about 2 hours and were not accompanied by neurological symptoms. She was a smoker. There was no family history of migraine. A severe throbbing bitemporal headache was accompanied by photophobia, vertigo, and repeated vomiting that lasted for 12 hours before admission to the hospital. On examination she was found to be drowsy but rousable, with normal pulse rate

and blood pressure. Her visual acuity, visual fields, fundi, and pupils were normal. Gaze was full in all directions, but rightward saccades consistently overshot the target and were followed by one or two leftward corrective saccades. Leftward refixation was achieved by a series of hypometric saccades. Attempted vertical saccades were accompanied by rightward oblique deviation of the eyes and corrected by oblique leftward movements, resulting in triangular trajectories. The movements appeared to be conjugate. No post-saccadic drift or nystagmus was present. Pursuit was saccadic in all directions. During eyelid closure, the eyes were deviated to the extreme right, but when she opened her eyes, a saccade brought them to the midposition. Function of the other cranial nerves was normal. A large-amplitude, arrhythmic, proximal tremor of the left arm was evident when it was outstretched and with action. Finger-to-nose, heel-to-shin, and rapid alternating movements of the left limbs were ataxic. Power, tone, and fine movements were intact. All tendon reflexes were normal, not pendular. Plantar responses were flexor. Findings from sensory examination were normal. The patient's gait was narrow-based, but she tended to list to the left.

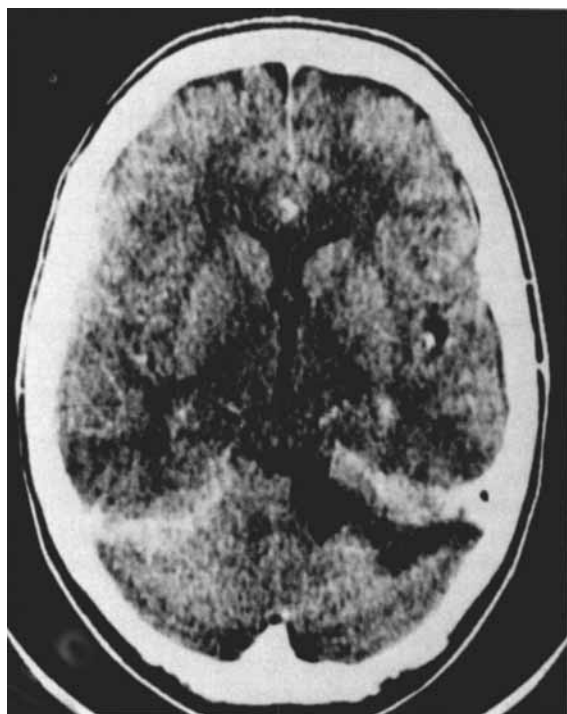
Computed tomography (CT) (Fig 1A), performed 20 hours after the onset of symptoms, and magnetic resonance imaging (MRI) showed an anterosuperior left-hemisphere cerebellar infarct without mass effect. Four-vessel angiograms demonstrated smooth tapering of the lumen of the left superior cerebellar artery 2 cm distal to its origin, and complete occlusion of the vessel along the superior aspect of the

---

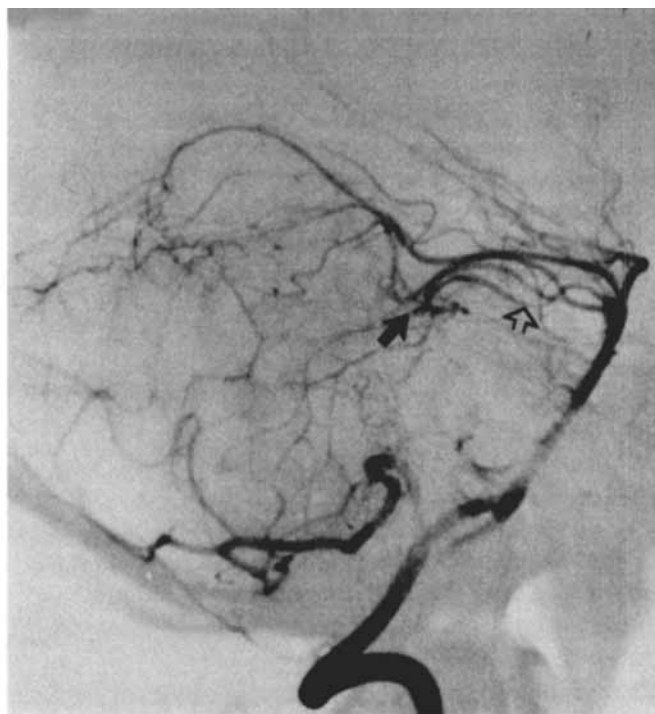
From the Neuro-ophthalmology Unit, Division of Neurology and the Playfair Neuroscience Unit, Toronto Western Hospital, and the Departments of Medicine and Ophthalmology, University of Toronto, Toronto, Ontario, Canada.

Received Aug 5, 1985, and in revised form Nov 13. Accepted for publication Dec 15, 1985.

Address reprint requests to Dr Sharpe, Division of Neurology, Toronto Western Hospital, 399 Bathurst St, Toronto, Ontario M5T 2S8, Canada.



A



B

Fig 1. (A) Computed tomographic scan, with contrast, outlines a left hemisphere cerebellar infarction involving the superior peduncle, most of the anterior lobe, and the lateral regions of lobulus simplex and crus 1 of the posterior lobe. (B) Lateral view of selective left vertebral artery angiogram shows smooth tapering of the left superior cerebellar artery (open arrow), followed by complete occlusion (closed arrow).

left cerebellar hemisphere (Fig 1B). All other vessels were normal. Electrocardiogram and echocardiogram were normal. Platelet count, hemoglobin, erythrocyte sedimentation rate, prothrombin time, partial thromboplastin time, fasting blood glucose content, complement levels, and antithrombin III activity were normal. Rheumatoid factor and antinuclear antibody tests were negative. Cerebrospinal fluid was normal.

The ocular motor findings and limb ataxia persisted for 6 weeks, except for the rightward deviation of the eyes during eye closure, which stopped after 3 days. Drowsiness and vertigo cleared within 48 hours and headache and nausea subsided over 1 week. No further headaches or neurological deficits have occurred during follow-up over 8 months. No source of embolism was found to account for the cerebellar infarct. Occlusion of the left superior cerebellar artery was attributed to migraine, associated with smoking and oral contraceptives.

### Oculographic Study

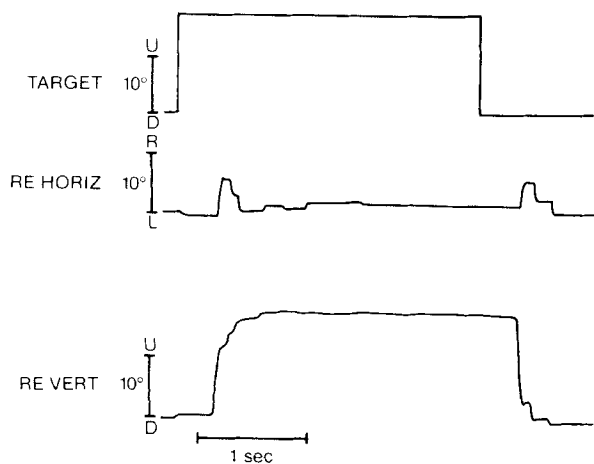
Horizontal and vertical movements of the right eye were recorded 6 days and 6 weeks after admission by the magnetic search coil technique. The full system bandwidth was DC to 400 Hz. Blinks were detected by skin electrodes located above and below the left eye. An occipital support restrained the head, while head position was monitored by a search coil on a head band. Analogue signals of target and eye position and velocity were stored on magnetic tape and displayed on an ink jet rectilinear polygraph.

Saccades were made horizontally and vertically toward light-emitting diode targets arrayed on a stimulus arc and stepped at amplitudes of 5, 10, 20, and 40 degrees. In darkness, saccades were made to remem-

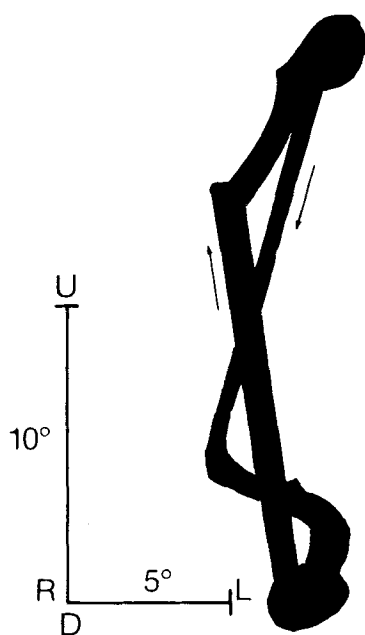
bered positions of 20-degree targets. We calculated smooth pursuit gain from polygraph recordings by dividing optimal smooth-eye-movement velocity by the maximal velocity of a target moving sinusoidally at peak-to-peak amplitudes of 10, 20, and 40 degrees at frequencies of 0.125, 0.25, 0.5, and 1.0 Hz ( $n > 10$  at each frequency and amplitude).

### Vertical Saccades

Vertical refixations were typically achieved by an initial large saccade followed by several hypometric saccades, but some consisted of three or four hypometric saccades throughout the excursion. Upward saccades were more frequently hypometric than were downward ones. Each vertical saccade was associated with a single rightward saccade (Fig 2A) that was not perfectly synchronous. The durations of horizontal components were longer (Table) than were those of purely horizontal saccades of equivalent amplitudes; for purely horizontal saccades averaging 4.4 degrees with a standard deviation (SD) of 0.7, mean duration was 32.8 msec (SD, 6.2). These were in the normal range reported in the literature (*cf.* [10]) and in this laboratory, where the mean duration of 5-degree horizontal



A



B

Fig 2. Vertical saccades. (A) Each vertical saccade (lower trace) is accompanied by a synchronous rightward saccade (middle trace) followed by small leftward saccades that return the eyes to the horizontal midposition. (B) Saccade trajectories during vertical refixation saccades. Eye position signals stored on magnetic tape were projected on an oscilloscope screen to reconstruct the path of refixations. An upward and downward saccade (arrows) are superimposed. Initial large oblique rightward saccades are followed by oblique leftward corrective saccades. (U = upwards; D = downwards; R = right; L = left.)

saccades is 35 msec (SD, 3.0). The durations of vertical saccadic components (see Table) did not differ significantly from the durations of purely vertical saccades of three normal subjects in our laboratory or one normal subject reported on [10]. The smaller rightward saccadic components began slightly later and ended slightly earlier than did their associated vertical components (see Table); velocity peaks were close together. Oblique saccades with larger differences in component

durations had less synchrony of the onset and offset of their orthogonal components.

The rightward components of these oblique saccades (Fig 2B) were usually followed by a small staircase of leftward hypometric saccades, and rarely by single steps, that returned the eyes to the target position. The rightward-component amplitudes varied (see Table) and were not related to the size of the vertical components or to initial eye position, whether vertical saccades began with the eyes in horizontal midposition, 20 degrees to the right, or 20 degrees to the left. In response to increasing amplitudes of vertical target steps, vertical saccades increased, but horizontal saccadic components did not show corresponding increments with increasing vertical saccadic amplitudes (see Table). Horizontal components did not consistently accompany small vertical saccades of less than 7 degrees. During vertical saccades to command in darkness, the amplitudes of horizontal saccadic components diminished, and the trajectory changed from triangular to diagonal (up to the left, down to the right). Blinking did not evoke lateral deviation when recorded 6 days after the infarction.

#### Horizontal Saccades

Rightward saccades were consistently hypermetric; each saccadic overshoot was followed by one or two leftward corrective saccades (Fig 3A). Oscillations about the fixation position seldom occurred. Leftward saccades were consistently hypometric, achieved by three or more small saccades. This pattern of rightward hypermetria and leftward hypometria persisted whether saccades were directed toward or away from midposition. The pattern was present for small (5-degree) and large (40-degree) target steps. Horizontal saccades did not evoke vertical saccades. In darkness, rightward saccades no longer overshoot the final eye position, but leftward saccades remained hypometric (Fig 3B).

#### Smooth Pursuit

Smooth-pursuit gain, the ratio of eye velocity to target velocity, was low in all directions, but downward gain was significantly lower than was upward gain. For example, at  $\pm 20$  degrees and 0.25 Hz, mean upward gain was 0.70 (SD, 0.22) and mean downward gain was 0.38 (SD, 0.19;  $p < 0.01$  by two-tailed  $t$  test). Vertical catch-up saccades, like vertical voluntary saccades, were accompanied by simultaneous rightward saccades, resulting in oblique saccades. Rightward and leftward pursuit gains were not significantly different but were subnormal; for example, at  $\pm 10$  degrees and 0.5 Hz, mean rightward gain was 0.26 (SD, 0.06) and mean leftward gain was 0.35 (SD, 0.15). Normal gain at this target velocity in our laboratory is 0.89 (SD, 0.07). Reduced smooth eye movement velocities resulted in frequent corrective saccades. Catch-up sac-

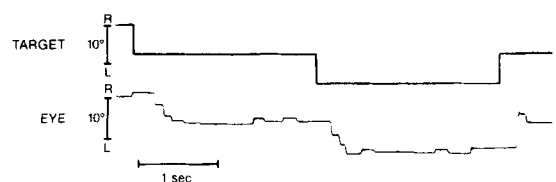	Vertical Amplitude (degrees $\pm$ 1 SD <sup>a</sup> )			
	8.2 $\pm$ 0.7	10.2 $\pm$ 0.6	12.2 $\pm$ 0.4	15.5 $\pm$ 0.9
Vertical duration (msec)	83.0 $\pm$ 13.9	78.3 $\pm$ 9.8	83.6 $\pm$ 18.2	97.5 $\pm$ 10.4
Horizontal amplitude (degrees)	4.7 $\pm$ 2.7	5.3 $\pm$ 1.3	3.9 $\pm$ 1.9	2.9 $\pm$ 1.1
Horizontal duration (msec)	49.0 $\pm$ 19.8	50.3 $\pm$ 3.5	53.5 $\pm$ 8.0	43.8 $\pm$ 10.3
Onset difference (msec) <sup>b</sup>	13.2 $\pm$ 7.5	10.4 $\pm$ 1.1	20.0 $\pm$ 4.8	21.3 $\pm$ 7.0
Offset difference (msec) <sup>b</sup>	14.0 $\pm$ 8.2	18.6 $\pm$ 10.7	17.1 $\pm$ 9.1	31.8 $\pm$ 13.9
Synchrony of velocity peaks (msec) <sup>c</sup>	6.6 $\pm$ 10.9	10.4 $\pm$ 5.4	8.6 $\pm$ 6.9	9.3 $\pm$ 5.1

<sup>a</sup>Saccades of different amplitudes in response to 20-degree vertical target steps were grouped into four bins of 7–9, >9–11, >11–13, and >13–16 degrees ( $4 \leq N \leq 7$  for each amplitude bin).

<sup>b</sup>Vertical components began before the onsets (onset difference) and ended after the terminations (offset difference) of their associated horizontal components.

<sup>c</sup>Mean difference in timing of velocity peaks of horizontal and vertical components. Vertical velocity peaks always occurred slightly before horizontal velocity peaks.

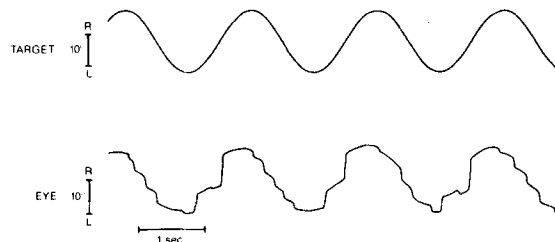
SD = standard deviation.



A



B



C

**Fig 3.** (A) Horizontal saccades. Refixations to the left toward the side of the cerebellar lesion are hypometric, achieved by a staircase of small saccades. Rightward refixations are hypermetric, with an initial saccadic overshoot followed by a corrective leftward saccade back to the target. (B) In darkness, rightward saccades no longer overshoot the final horizontal position, while leftward saccades remain hypometric. Leftward smooth eye drift in darkness is periodically corrected by rightward saccades. (C) Horizontal pursuit requires compensatory saccades in both directions. Rightward catch-up saccades are large, and leftward catch-up saccades are small. Although leftward tracking is accompanied by more frequent saccades, the gains of rightward and leftward smooth eye movements were the same. (L = left; R = right.)

saccades were much larger rightward than leftward (Fig 3C). Although tracking was asymmetrical, actual horizontal smooth-eye-movement velocities were similar in both directions. The apparent smooth-pursuit asymmetry was caused by the asymmetry of saccade amplitudes.

#### Fixation

Frequent square-wave jerks disrupted fixation. Vertical eye position was stable without nystagmus on up or down gaze. During attempted fixation of an imaginary target in darkness, the eyes drifted slowly leftward (1.3 degrees/sec) and rightward saccades created a nystagmus pattern. The rate of drift did not exceed normal [18] but was consistently leftward; the eyes deviated slowly to the left. During vertical saccades in darkness, the leftward eye drift was faster (2.9 degrees/sec). When target lights were restored, saccades promptly returned the eyes to the midposition.

#### Discussion

The cardinal ocular motor abnormalities associated with unilateral infarction in the distribution of the superior cerebellar artery comprised the following triad: (1) contralateral saccades evoked by attempted vertical saccades; (2) hypometria of ipsilateral saccades; and (3) hypermetria of contralateral saccades. That is, saccades contralateral to the lesion overshoot the target while ipsilateral saccades fell short of the target. Each vertical saccade was accompanied by a synchronous rightward saccade resulting in oblique trajectories: up and contralateral, down and contralateral.

Ipsilateral limb dysmetria and static arm tremor are typical of occlusion of the superior cerebellar artery [4, 7, 9]. Ipsilateral Horner's syndrome and contralateral spinothalamic sensory loss are features of proximal occlusions of this artery [4], but were absent in our patient who had more distal occlusion. Gaze-evoked or primary-position vertical nystagmus can occur [9], but

bilateral or midline ischemia resulting from disease of the distal basilar artery branches may be responsible, since it is absent in most cases [4, 9] as in our patient.

The combination of saccadic hypermetria in one horizontal direction, hypometria in the opposite direction, and horizontal saccades evoked by vertical saccades was recognized by Kommerell and Hoyt [12] in a patient with lateral medullary infarction and called *lateropulsion of saccades*. The unidirectional error in saccadic accuracy is applied both to the saccadic pulse (the phasic burst of motor neuron discharge that drives the eyes rapidly to a new position) and to the saccadic step (the tonic motor neuron discharge that holds the eyes in their new position). In subsequent case reports, lateropulsion has been considered a specific sign of lateral medullary damage from infarction in the territory of the posterior inferior cerebellar artery [3, 11], demyelination [13], encephalitis [13], or tumor [6]. In each patient, the lateropulsion was toward the side of the medullary lesion, ipsilateral to the ataxic limbs. We cannot attribute the saccadic bias to transient ischemia occurring in the medulla as the result of migraine, since there was no clinical, CT, or MRI evidence of a medullary lesion, and since the saccadic bias persisted for over 6 weeks. The lateropulsion of saccades was directed away from the side of the cerebellar lesion, contralateral to the ataxic limbs. *Contrapulsion* and *ipsipulsion* seem to be two distinct forms of saccadic lateropulsion, the former signifying damage to the rostral cerebellum and the latter indicating involvement of the lateral medulla or adjacent cerebellum.

Pulsion of saccades in our patient was present during vertical saccades both to target steps and to command in darkness. In darkness, the trajectory changed from triangular to diagonal, as reported in a case of lateral medullary infarction [11]. Illusory tilt of the visual environment is occasionally a feature of lateral medullary infarction [2]; our patient did not experience this. In Wallenberg's syndrome, both trunk and limb movements veer toward the side of the lesion; the ipsipulsion of saccades is thus part of the unidirectional bias of skeletal movements that Bjerver and Silfverskiöld [2] called *lateropulsion*. In contrast, when walking our patient veered toward the side of the rostral cerebellar damage, but the pulsion of saccades was contralateral. In patients with lateral medullary lesions, the eyes deviate toward the lesion during eye closure [3, 12, 13], in the direction of saccadic pulsion. In our patient, during eye closure the eyes also deviated in the direction of saccadic bias for the first two days. Contrapulsion of saccades persisted for over 6 weeks.

Oblique saccades are composed of horizontal and vertical vectors. The duration of a saccade is linearly proportional to its amplitude. The duration of the smaller vector of an oblique saccade is stretched to nearly match the duration of the larger vector [10, 19]. Considerable mismatch of the durations or timing of

velocity peaks of the orthogonal components would cause curved saccades. The oblique contrapulsive saccades in our patient were quite straight. Horizontal components began somewhat after the onsets and ended somewhat before the terminations of the larger vertical saccades that evoked them; their velocity peaks were close together. Slight curvature at the beginning and end of saccades was not apparent clinically or on oscilloscope reconstructions at the resolution that we employed (see Fig 2B). The trajectory was triangular, consisting of a large oblique saccade followed by one or more oblique or horizontal corrective saccades that returned the eyes to their target.

Van Gisbergen and associates [19] suggested that oblique saccades are first dispatched by a vectorial pulse generator and subsequently decomposed into horizontal and vertical saccadic pulses. According to their hypothesis [19], a signal of oblique target position on the retina is relayed to this vectorial pulse generator, rather than directly to the separate brainstem pulse generators for horizontal and vertical saccades. As in normal oblique saccades [10, 19], the orthogonal components of contrapulsive oblique saccades are temporally linked. This indicates integrity of the vectorial pulse generator [19] and implies that the horizontal error, which is evoked by vertical saccades, is applied "proximal" to it. If the horizontal deviation were introduced "below" the locus of decomposition into horizontal and vertical pulses, temporal coupling of these components of contrapulsive saccades would not be expected. Retinal error is anatomically coded in a neural map across the superior colliculus [8, 19], but it is not known how this spatial coding is translated into the temporal coding necessary for brainstem burst neurons to generate accurate saccades [14, 16]. The rostral cerebellum participates in the regulation of saccadic accuracy and receives relays from the superior colliculus [8]. Cerebellar lesions may impair the accuracy of saccades by disrupting circuits that transmit spatial information from the superior colliculus to saccadic pulse generators in the brainstem tegmentum.

The infarct involved lobulus simplex, crus I, and vermal lobe V (see Fig 1A), areas where stimulation evokes ipsilateral oblique saccades [16]. Destruction of this area in our patient caused contralateral oblique saccades. Ablation of the dorsal vermis and paravermis causes errors of saccadic amplitude [1, 14], while ablation of the flocculus leads to errors in the maintenance of eye position after saccades [23]. Experimental lesions of the dorsal vermis or medial cerebellar nuclei cause hypermetric centripetal saccades, but centrifugal saccades may be hypermetric [14, 20] or hypometric [15, 20]. In our patient, ipsilateral saccades were hypometric, whether centripetal or centrifugal, and contralateral saccades were hypermetric, whether centripetal or centrifugal. This hypermetria is distinguished from overshoot dysmetria with oscillation

about the intended fixation position after saccadic gaze shifts [17]. The overshoots of contrapulsion were followed by one or more saccades back to the new fixation position, usually without oscillation.

Inaccuracy of horizontal saccades was similar to that produced by unilateral ablation of vermal and paravermal cortex in the monkey [1]. The direction of inaccuracy appears to be quite idiosyncratic with diffuse cerebellar degeneration [22], midline masses [17], and bilateral experimental lesions [14, 15, 20], but saccadic errors are consistently unidirectional after unilateral lesions of the cerebellar cortex [1] or the lateral medulla [3, 12, 13]. Further quantitative oculographic correlation with well-defined unilateral lesions confined to the rostral cerebellum will be required to confirm the consistent unidirectional saccadic bias exhibited by our patient. The infarct was anterior and lateral to vermal and paravermal cortex [1], but it also involved the superior peduncle and possibly the upper surface of the middle peduncle and the deep cerebellar nuclei, which are all perfused by the superior cerebellar artery [4]. Contrapulsion might result from infarction of the cortex, the deep nuclei, or their projections into the superior peduncle. We suggest that imbalanced cerebellar outflow causes contrapulsion of saccades.

The unilateral cerebellar infarct in our patient impaired smooth pursuit in all directions. Unilateral cerebellectomy in the monkey causes ipsilateral pursuit defects [21], but this might result from damage to the flocculus [23]. The difference in amplitudes of horizontal catch-up saccades caused a spurious appearance of smooth pursuit asymmetry in our patient. Contralateral catch-up saccades were larger than ipsilateral catch-up saccades, reflecting the contralateral hypermetria and ipsilateral hypometria. Determination of actual smooth-eye-movement gain, rather than estimation of the frequency or amplitudes of catch-up saccades, is necessary to detect genuine smooth pursuit asymmetry. Although ipsilateral tracking required more catch-up saccades, measurement of smooth-eye-movement velocities demonstrated symmetry of horizontal smooth pursuit.

This distinctive combination of contrapulsion of saccades with ipsilateral postural tremor and dysmetria of the limbs was associated with rostral cerebellar damage in the distribution of the superior cerebellar artery. Impaired smooth pursuit and hypometric vertical saccades accompanied this disorder of ocular and skeletal motor control.

---

Supported by Medical Research Council of Canada grants ME5509 and MT5404 (Dr Sharpe) and by the Toronto Western Hospital (Dr Ranalli). Dr Ranalli is a Medical Research Council of Canada Fellow in Neuro-ophthalmology.

We thank Dr C. Miller Fisher of Boston, MA, and Dr Eugene Benjamin of Winston-Salem, NC, for subsequently providing information confirming our observation of saccadic contrapulsion in other

patients with rostral cerebellar infarcts. We are grateful to Mr P. Nguyen for technical work, Dr J. A. Saint-Cyr for thoughtful discussion, and Mrs R. Armstrong for manuscript preparation.

## References

1. Aschoff JC, Cohen B: Changes in saccadic eye movements produced by cerebellar cortical lesions. *Exp Neurol* 32:123-133, 1971
2. Bjerver K, Silfverskiold BP: Lateropulsion and imbalance in Wallenberg's syndrome. *Acta Neurol Scand* 44:91-100, 1968
3. Crevits L, vander Eecken H: Ocular lateropulsion in Wallenberg's syndrome: a prospective clinical study. *Acta Neurol Scand* 65:219-222, 1982
4. Davidson C, Goodhart SP, Savitsky N: The syndrome of the superior cerebellar artery and its branches. *Arch Neurol Psychiatry (Chicago)* 33:1143-1174, 1935
5. Ellenberger C, Keltner JL, Stroud MH: Ocular dyskinesia in cerebellar disease. *Brain* 95:685-692, 1972
6. Frisen L: Lateropulsion of the eyes—a localizing brainstem sign. *J Neurol* 218:171-177, 1978
7. Hiller F: The vascular syndromes of the basilar and vertebral arteries and their branches. *J Nerv Ment Dis* 116:922-1016, 1952
8. Huerta MF, Harting JK: Connectional organization of the superior colliculus. *Trends Neurosci* 7:286-289, 1984
9. Kase CS, White JL, Joslyn JN, et al: Cerebellar infarction in the superior cerebellar artery distribution. *Neurology (Cleveland)* 35:705-711, 1985
10. King WM, Lisberger SG, Fuchs AF: Oblique saccadic eye movements of primates. *J Neurophysiol* (in press)
11. Kirkham TH, Guitton D, Gans M: Task dependent variations of ocular lateropulsion in Wallenberg's syndrome. *Can J Neurol Sci* 8:21-26, 1981
12. Kommerell G, Hoyt WF: Lateropulsion of saccadic eye movements: electro-oculographic studies in a patient with Wallenberg's syndrome. *Arch Neurol* 28:313-318, 1973
13. Meyer KT, Baloh RW, Krohel GB, Hepler RS: Ocular lateropulsion: a sign of lateral medullary disease. *Arch Ophthalmol* 98:1614-1616, 1980
14. Optican LM, Robinson DA: Cerebellar-dependent adaptive control of primate saccadic system. *J Neurophysiol* 44:1058-1076, 1980
15. Ritchie L: Effects of cerebellar lesions on saccadic eye movements. *J Neurophysiol* 39:1246-1256, 1976
16. Ron S, Robinson DA: Eye movements evoked by cerebellar stimulation in the alert monkey. *J Neurophysiol* 36:1004-1022, 1973
17. Selhorst JB, Stark L, Ochs AL, Hoyt WF: Disorders in cerebellar ocular motor control. I. Saccadic overshoot dysmetria: an oculographic, control system and clinico-anatomical analysis. *Brain* 99:497-508, 1976
18. Sharpe JA, Goldberg HJ, Lo AW, Herishanu YO: Visual-vestibular interaction in multiple sclerosis. *Neurology (NY)* 31:427-433, 1981
19. van Gisbergen JAM, van Opstal AJ, Schoenmakers JJM: Experimental test of two models for the generation of oblique saccades. *Exp Brain Res* 57:321-336, 1985
20. Vilis T, Hore J: Characteristics of saccadic dysmetria in monkeys during reversible lesions of medial cerebellar nuclei. *J Neurophysiol* 46:828-838, 1981
21. Westheimer G, Blair SM: Functional organization of primate oculomotor system revealed by cerebellectomy. *Exp Brain Res* 21:463-472, 1974
22. Zee DS, Yee RD, Cogan DG, et al: Ocular motor abnormalities in hereditary cerebellar ataxia. *Brain* 99:207-234, 1976
23. Zee DS, Yamazaki A, Butler PH, Gucer G: Effects of ablation of flocculus and parafoveolus on eye movements in primate. *J Neurophysiol* 46:878-899, 1981