

INFARCTION IN THE TERRITORY OF THE ANTERIOR CHOROIDAL ARTERY

A CLINICAL AND COMPUTERIZED TOMOGRAPHIC STUDY OF 16 CASES

by J. P. DECROIX,¹ PH. GRAVELEAU,² M. MASSON¹ and J. CAMBIER¹
(From the ¹Clinique Neurologique, Hôpital Beaujon, Clichy, and ²the Service de Neurologie, Hôpital Foch, Suresnes, France)

SUMMARY

Sixteen cases of the anterior choroidal artery syndrome are reported. In its completed form, this rare syndrome combines the triad of hemiplegia, hemianaesthesia, and homonymous hemianopia. CT examination confirms the diagnosis by revealing an area of reduced density situated in the posterior limb of the internal capsule, sparing the thalamus medially and encroaching upon the tip of the globus pallidus laterally, and corresponding to the distribution of the anterior choroidal artery. Incomplete forms of the syndrome are more frequent. Left-sided spatial neglect may accompany right-sided lesions, as may slight disorders of speech in left-sided lesions. Clinical-anatomical correlations are discussed.

INTRODUCTION

The syndrome of the anterior choroidal artery was described in 1925 by Foix *et al.*, although 2 cases had been reported by Kolisko in 1891. Subsequent cases, with anatomical confirmation, were published by Poppi (1928), Ley (1932), Abbie (1933), and Buge *et al.* (1979), making a total of 7 cases. In its complete form, the syndrome comprises hemiplegia, hemianaesthesia, and homonymous hemianopia contralateral to the lesion. The absence of a cognitive deficit classically permits the differential diagnosis from cortical and subcortical lesions. In 1983 and 1984 we reported 5 cases and described the clinical, neuropsychological and computerized tomographic (CT) signs (Masson *et al.*, 1983; Viader *et al.*, 1984). There have been subsequent descriptions by Ward *et al.* (1984) and Derouesné *et al.* (1985). The present study of 11 new cases makes it possible to distinguish the principal signs and their variations related to infarction in the territory of the anterior choroidal artery.

Correspondence to: Dr J. P. Decroix, Clinique Neurologique, Hôpital Beaujon, 100 Bd du Général Leclerc, 92110 Clichy, France.

CASE REPORTS

The clinical observations are summarized in Table 1 and the CT scans in fig. 4. Cases 1, 2, 4, 6 and 15 have already been published (Cambier *et al.*, 1983; Masson *et al.*, 1983; Viader *et al.*, 1984).

Case 1 (N 2260 D)

A right-handed man, aged 62 years, was admitted to hospital on September 13, 1981, with a left hemiplegia of sudden onset. He had previously had untreated arterial hypertension and diabetes. Examination on admission revealed a massive left hemiplegia, anaesthesia for all sensory modalities down the left half of the body, and a left homonymous hemianopia.

TABLE 1. CLINICAL SYMPTOMS

Case	Sex/Age (yrs)	Side of lesion	Hemiplegia	Sensory deficit	Homonymous hemianopia	Language deficit	Neglect syndrome
1	M/62	R	Severe	Severe	+	0	Severe
2	M/53	R	Severe	Severe	+	0	Severe
3	F/64	L	Moderate	Moderate	+	0	0
4	F/68	R	Severe	Severe	Visual extinction	0	Moderate
5	M/71	R	Brachiofacial	Moderate	0	0	0
6	F/68	L	Moderate	Moderate	0	'Thalamic' aphasia	0
7	M/45	L	Moderate	Moderate	0	Dysarthria	0
8	F/67	L	Moderate	Moderate	0	'Thalamic' aphasia	0
9	F/83	L	Moderate	Moderate	0	Dysarthria	0
10	F/60	R	Severe	0	0	Dysarthria	0
11	F/75	R	Brachiofacial	0	0	0	0
12	M/46	L	Severe	0	0	Dysarthria	0
13	M/72	L	0	Severe	0	0	0
14	F/42	L	0	Severe	0	0	0
15	M/84	L	Severe	Moderate	0	Dysarthria	0
16	F/71	L	Moderate	Moderate	0	Dysarthria	0

Neuropsychological examination was undertaken between the second and ninth days after the stroke. Orientation in time and space was satisfactory, but he showed severe visual neglect to the left; the head and eyes were permanently turned to the right. He could look to the left on command, turning first his head and then his eyes. When asked to cross out marks, only those on the extreme right-hand edge of the page were deleted. When asked to describe a picture, only the right-hand quarter was identified. The placing of principal towns on an outline map of France was correctly performed, despite some imprecision; this test did not reveal left visual neglect, as there was no displacement of town sites to the right. Voluntary drawing (circle, square, cube, bicycle, flower) was defective and imprecise; the pictures were nevertheless complete except for the flower, which lacked petals on the left. When copying a picture, the drawing was identical, but neglect of the left part was more evident. There was a partial agnosia for pictures which seemed to depend on the left visual neglect: out of 21 pictures, 11 were correctly identified immediately, 5 after one or more mistakes, and 5 were not identified or wrongly identified. In Poppelreuter's test, performance was better when the picture was presented in its normal form than when enlarged; in the latter case the left part was then ignored. There was no agnosia for objects or colours, and no prosopagnosia. Language was normal. Reading of letters gave rise to a constant error, as W was identified as N. Syllables were correctly identified if they comprised only two letters, although the first was sometimes neglected. From 3 letters upwards, paralexia was frequent owing to neglect of one or more letters at the beginning of the syllable. Reading of words was correct

with the exception of rare but significant mistakes: *mappemonde* was read *monde* and *esquimau* as *mau*. In general, mistakes were more frequent when the right-hand part of the word, in isolation from the left, was meaningful: *plateau* was read as *eau* and *cartable* as *table*. When reading a text, the left-hand part was neglected and there were mistakes in changing line; the result was incoherent. Dichotic listening revealed a total extinction on the left. There was motor impersistence, but no anosognosia.

CT scan without contrast (17/9/81) showed an area of reduced density in the posterior limb of the right internal capsule. ECG revealed left ventricular hypertrophy. The neurological signs and symptoms remained virtually unchanged. At discharge after one month the hemiplegia was as severe as on admission, hypoaesthesia for all modalities persisted down the left half of the body, and the hemianopia was unchanged, but the neglect syndrome had improved.

Case 2 (N 2191 D)

A right-handed man, aged 53 years, was admitted to hospital following a left hemiplegia of sudden onset on August 7, 1981. He had had a primary tuberculous infection at the age of 20. Examination on admission showed a severe left hemiplegia, anaesthesia for all sensory modalities down the left half of the body, and a left homonymous hemianopia. Blood pressure was normal.

Neuropsychological examination was carried out between the days 26 and 28 after the stroke. Orientation in space and time was satisfactory. There was severe visual neglect on the left. The head and eyes were spontaneously turned to the right, but the patient could look to the left on command,

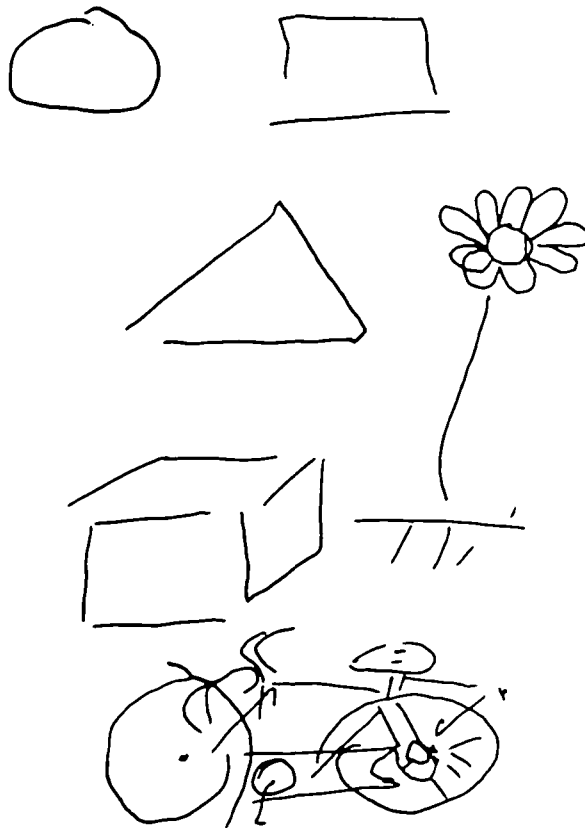


FIG. 1. Case 2. Spontaneous drawings.

turning first his head and then his eyes. When asked to cross out marks on paper, only those on the extreme right of the page were deleted. When asked to describe complex images, only the right fifth of the picture was identified. Placement of towns on an outline map of France was correct, as were freehand drawings of a cube, a flower and a bicycle (fig. 1). However, when copying the same pictures from a model, the left-hand part was completely neglected (fig. 2). Copying Rey's figure produced

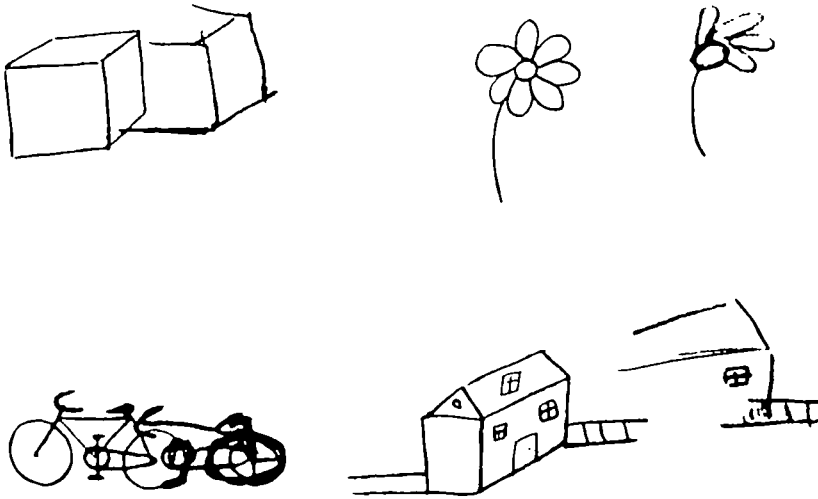


FIG. 2. Case 2. Copied drawings.

disorganization of the left part of the figure. There was partial agnosia for image recognition, with 10 mistakes in 32 pictures. In Poppelreuter's test, performance was better when the design was presented in its normal form than when enlarged, when the left part was neglected. There was no agnosia for objects, colours or prosopagnosia. Speech was normal. When writing spontaneously or from dictation, the patient did not use the left-hand side of the paper. When copying from a text, only the right-hand part of the sentences were copied. There were reading deficits, such that Y was identified as I; all other letters were correctly identified. Reading of syllables revealed neglect of the left-hand part, particularly if the syllable comprised more than three letters: *oul* was read as *ul*, *drain* as *ain*, *splan* as *plan* and *stronc* as *tronc*. Reading of logatomes revealed the same deficit. Mistakes appeared in the reading of words, particularly when the right-hand part, isolated from the left, retained a meaning (*chevrefeuille* was read as *feuille*). When reading a text, the left-hand part was completely ignored. The patient was aware of the resulting incoherence but was unable to correct it. There was motor impersistence: the patient was unable to keep his eyes closed on command, and every verbal communication automatically produced opening of the eyes, despite repeated requests to close them. Immediately after admission, there was anosognosia.

Cervical Doppler, ECG, Holter and echocardiogram were normal. CT scan without contrast (21/8/81) showed an area of diminished density in the posterior limb of the right internal capsule (fig. 3), which was unchanged by injection of contrast. Right carotid angiography did not reveal atheroma in the cervical or cranial vessels and the right anterior choroidal artery was visible and apparently normal. The neurological deficits did not change. A month later, the patient suffered an infarct in the territory of the left middle cerebral artery, suggesting a diagnosis of multiple emboli of cardiac origin, despite the negative cardiac findings.

Case 3 (N 5713 D)

A woman, aged 64 years, was admitted on February 14, 1983, with a right hemiplegia. There was no significant previous history. The right hemiplegia had developed suddenly on the previous day. Examination on admission showed an incomplete right hemiplegia, anaesthesia for pin prick over the whole right half of the body, a defect of deep sensation on the right and a right homonymous hemianopia. There was no speech deficit. Blood pressure was normal. ECG and Doppler examination of the cervical vessels were normal. Fasting blood sugar was slightly elevated at 8.7 mmol/l. CT scan (15/2/1983) showed diminished density in the posterior limb of the left internal capsule, unchanged by injection of contrast. On discharge a month later the patient was able to walk without help, the motor deficit was not severe, the hemianopia had disappeared but the sensory deficit persisted.

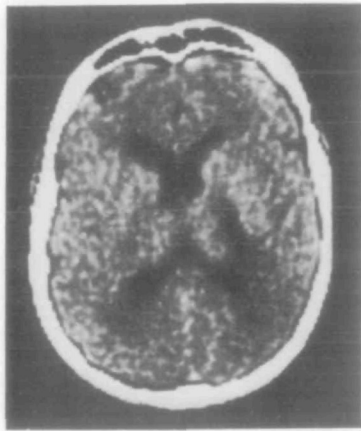

FIG. 3. *Case 2.* CT scan, showing area of reduced density in posterior limb of right internal capsule.

Case 4 (N 2889 D)

A woman, aged 68 years, was admitted on December 25, 1981. Her past history included calcified aortic narrowing. A left hemiplegia of sudden onset had developed on December 22, 1981. On admission, examination revealed a total left hemiplegia, anaesthesia of all sensory modalities down the left half of the body, and left visual extinction. Blood pressure was normal.

Neuropsychological examination was performed between days 11 and 16 after the stroke. Orientation in time and space was normal. At the beginning of her stay in hospital, the patient manifested left visual neglect, with the head and eyes most frequently turned to the right. When asked to enumerate the people in the room, she 'forgot' those on her left. There was left visual extinction, but this feature was notably improved by the time of neuropsychological examination. Crossing out marks across a page was normal. However, when asked to bisect a horizontal line, there was a distinct shift to the right. When asked to describe pictures, details on the extreme left were omitted. Placing of the principal towns on an outline map of France was correctly carried out. Spontaneous drawing (circle, square, bicycle, house, flower) was defective and imprecise, but slightly better when copying. Copying of Rey's figure was disorganized, with omission of detail on the extreme left. There was no agnosia for pictures, objects, or colours and no prosopagnosia. Speech was normal. Spontaneous and dictated writing revealed a failure to use the left side of the paper. Reading of letters, syllables and words was normal. Reading a text revealed difficulties in returning to the line. Mental arithmetic was unaffected. In arithmetical calculations, the operational sign placed at the left was sometimes neglected. There was an anosognosia when she was first in hospital. She suffered from motor impersistence.

Blood pressure was normal. ECG showed arrhythmia due to atrial fibrillation, but she returned to

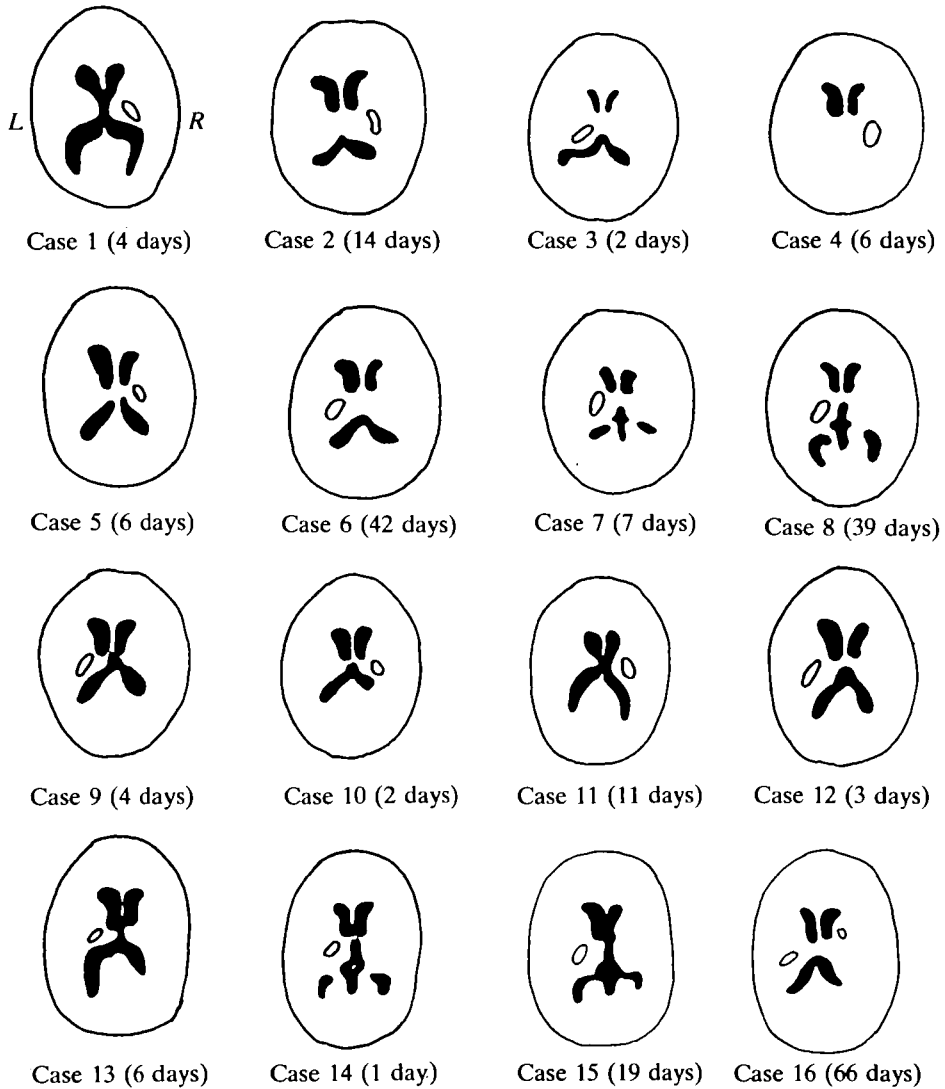


FIG. 4. Diagrams illustrating CT appearances in all 16 patients: time between onset of symptoms and CT scan is indicated in brackets.

sinus rhythm the following day. No biochemical abnormalities were detected. Doppler examination showed moderate stenosis at the origin of the right internal carotid artery, without reversal of flow in the ophthalmic artery. CT scan (28/12/82) showed diminished density in the posterior limb of the right internal capsule unchanged by injection of contrast. On discharge one month later, there was no alteration in symptoms.

Case 5 (N 1073 E)

A man, aged 71 years, was admitted on March 12, 1980, with a left hemiplegia. There was a history of hypertension and of a rapidly regressing left hemiplegia in 1975. On the evening of March 11, 1980, he

experienced paraesthesiae in the left leg, and on waking the next morning was hemiplegic. Examination on admission showed a left hemiplegia with brachiofacial predominance, diminished pin prick sensation over the whole left half of the body, but no deficit of position sense. There were no visual field disturbances and higher cerebral function was unaffected. ECG was normal. Doppler examination showed stenosis of the left internal carotid artery. Blood sugar was raised to 7.92 mmol/l. CT scan (17/3/1980) showed reduced density in the posterior limb of the right internal capsule. The symptoms were unchanged on discharge fifteen days later.

Case 6 (N 2320 E)

A woman, aged 68 years, was admitted on October 26, 1976 because of a right hemiplegia which had developed suddenly the previous day, together with a speech deficit. Past history revealed arterial hypertension which had been treated since 1967. Examination on admission showed moderate right hemiparesis and hypoaesthesia for all sensory modalities over the right half of the body. Visual fields were normal. The patient did not speak spontaneously, but would briefly answer questions. The informational content of her spontaneous speech was good, but language production was slow with some words missing and rare semantic paraphasia. When asked to name 25 pictures, some semantic paraphasia and perseveration were noted. Words in alphabetical series or categories revealed some loss of verbal fluency and the existence of perseveration. Repetition, comprehension of spoken and written language, spelling, and mental arithmetic were all normal.

ECG was normal. CT scan (7/12/1976) showed an area of reduced density in the posterior limb of the left internal capsule, which was thinly ringed after injection of contrast. Five years later, she still had a moderate right hemiparesis with hypoaesthesia of the right half of the body; semantic paraphasia remained evident in her speech.

Case 7 (N 2334 E)

A man, aged 45 years, was admitted on June 30, 1984, with right hemiplegia. There was a history of renal calculus. The right hemiplegia developed suddenly on June 26, 1984 together with a language deficit which regressed in 24 h. On admission, examination revealed moderate right hemiplegia, and diminished pin prick sensation over the right half of the body without any loss of position sense. The visual fields were normal and there was a mild dysarthria. Blood pressure was moderately raised. ECG showed left ventricular enlargement. Doppler examination revealed moderate stenosis at the origin of the left internal carotid artery. CT scan (3/7/1984) showed diminished density in the posterior limb of the left internal capsule. On discharge ten days later, the symptoms were unchanged.

Case 8 (N 875 E)

A woman, aged 67 years, was admitted on February 20, 1984, with a right hemiplegia. She had previously complained of frequent palpitations which were treated with amiodarone. A right hemiplegia of sudden onset had developed on January 28, 1984. Examination on admission showed a moderate right hemiplegia, diminished pin prick sensation down the right half of the body with astereognosis and impaired joint position sense. Visual fields were normal. There was slight dysarthria, with a reduction in fluency and in initiating speech. ECG was normal. Doppler examination demonstrated moderate stenosis at the origin of both internal carotid arteries. CT scan (8/3/1984) showed uptake of contrast in the posterior limb of the left internal capsule. Three months later, there was considerable improvement and she was able to walk without support.

Case 9 (N 356 E)

A woman, aged 83 years, was admitted on September 4, 1983, with a right hemiplegia. There was a previous history of diabetes treated by sulphamides since 1958, and moderate renal insufficiency. On August 5, 1983, she had experienced headaches. On August 7 she experienced dysarthria and was hemiplegic on waking the next morning. On admission, she had a complete right hemiplegia with diminished pin prick sensation over the right half of the body without disturbance of joint position

sense. There was no hemianopia, but there was dysarthria. ECG was normal. Blood sugar was raised to 10.3 mmol/l. Doppler examination revealed moderate stenosis at the origin of the left internal carotid artery. CT scan (11/8/83) showed a nonenhancing area of reduced density in the posterior limb of the left internal capsule. Four months later the hemiplegia was still severe but the sensory disturbances had disappeared.

Case 10 (N 2028 E)

A woman, aged 60 years, was admitted on March 18, 1984, with a left hemiplegia with which she had woken that morning. There was no significant previous history. Examination on admission revealed a total left hemiplegia, with no disturbance of sensation or visual fields, and no neglect syndrome. Blood pressure was normal. ECG showed some ventricular ectopic beats. Doppler examination revealed stenosis at the origin of the right internal carotid artery without reversal of flow in the ophthalmic artery. Blood sugar was 6.6 mmol/l. CT scan (20/3/1984) showed an area of reduced density in the posterior limb of the right internal capsule. Two months later the lower limb had recovered sufficiently to allow walking, but the upper limb showed little change.

Case 11 (N 5704 D)

A woman, aged 75 years, was admitted on March 1, 1983, with a left hemiplegia which had come on in two episodes on February 24, 1983. She had previously had a gastrectomy for peptic ulcer. Examination on admission revealed a left hemiplegia with brachiofacial predominance, without disturbances of sensation or of the visual fields and without a neglect syndrome. ECG was normal. Doppler examination showed moderate stenosis of the left internal carotid artery. CT scan (7/3/1983) revealed an area of reduced density in the posterior limb of the right internal capsule. Two months later, there was good recovery in the lower limb, but none in the upper.

Case 12 (84/9695)

A man, aged 46 years, was admitted on June 5, 1984, with a right hemiplegia with which he had woken that morning. He had previously suffered from severe hypertension. Examination on admission showed a complete right hemiplegia with no sensory or visual field disturbances; he was dysarthric. ECG showed enlargement of the left ventricle. Doppler examination was normal. CT scan on June 8, 1984, revealed an area of reduced density in the posterior limb of the left internal capsule. One month later there was considerable recovery in the lower limb, permitting walking with a severely spastic gait, but little recovery in the upper limb.

Case 13 (84/1347)

A man, aged 72 years, was admitted on January 21, 1984, with left hemianaesthesia. Arterial hypertension had recently been diagnosed. On the day of admission, the patient had suddenly felt weakness in the right lower limb and a disturbance of balance. Examination on admission showed total nondissociated hemianaesthesia in the right half of the body, without any motor deficit or asymmetry of tendon reflexes and without visual field defects. ECG, biochemistry and a Doppler examination were all normal. CT scan (27/1/1984) showed an area of reduced density in the posterior limb of the left internal capsule. On discharge fifteen days later he still had hypaesthesia of the whole left half of the body.

Case 14 (84/7010)

A woman, aged 42 years, was admitted on April 22, 1984, with right hemianaesthesia; there was no significant previous history. She noticed swelling of her right leg on the morning of admission, and had had palpitations the previous evening. Examination on admission revealed undissociated hemianaesthesia of the whole right half of the body, without motor disturbance or visual field defect. ECG, biochemistry, and Doppler testing were normal. CT scan (22/4/1984) showed reduced density in the posterior limb of the left internal capsule. On discharge fifteen days later she had completely recovered.

Case 15 (N 324 E)

A right-handed man, aged 84 years, with non-insulin-dependent diabetes, was admitted on June 18, 1982, with a right hemiparesis. Eight days previously he had suddenly had the impression of 'seeing three people instead of one'; this lasted only a few seconds. An hour later, he felt formication first in his right upper, then his right lower limb. On waking the next morning, he had a right hemiparesis, difficulty in speaking, and diplopia. The deficit became complete in the course of the day. Examination on admission revealed a total right hemiplegia and hypaesthesia for all sensory modalities on the same side. Visual fields were normal. There was dysarthria without dysphasia. The patient complained of vertical diplopia on looking in all directions, which was attributed to a defect in upward movement of the left eye. CT scan (29/6/1982) showed reduced density in the posterior limb of the left internal capsule.

Case 16 (84/21142)

A hypertensive woman, aged 71 years, with non-insulin-dependent diabetes, was admitted on December 10, 1984, because of the sudden onset 48 h earlier of a right hemiparesis with an initial loss of speech. Examination revealed a moderate right hemiparesis with brachiofacial predominance. Initially, there was ataxia of the right arm with difficulty in grasping an object with the eyes shut. Joint position sense, cutaneous sensation and the visual fields were normal. There was dysarthria, difficulty in organizing conversation and in recalling series of words (9 names of animals in 1 min), and a constructional apraxia. CT scan on December 11, 1984, showed a small area of reduced density in the anterior limb of the right internal capsule. A second scan (12/2/1985) showed persistence of this appearance, together with a new area of reduced density in the posterior limb of the left internal capsule. ECG was normal. Doppler examination coupled with echography showed diffuse atherosclerosis of the carotid and a calcified plaque at the left carotid bifurcation. There was gradual partial regression of the sensorimotor deficits and of the dysarthria.

DISCUSSION

The anterior choroidal artery is a branch of the internal carotid, and usually arises above the origin of the posterior communicating artery. Despite its long course its diameter is very narrow. Running at first between the brainstem and the uncus of the temporal lobe, it enters the inferior (temporal) horn of the lateral ventricle and ends in its choroid plexus, its branches anastomosing with those of the posterolateral choroidal artery. According to Abbie (1933), Carpenter *et al.* (1954), Lazorthes (1961), and Rhoton *et al.* (1979), it supplies the whole of the internal segment and part of the external segment of the globus pallidus; the posterior two-thirds of the posterior limb of the internal capsule, together with its retrolenticular segment, including the origins of the optic and auditory radiations; the optic tract; the lateral half of the lateral geniculate body; the most rostral part of the cerebral peduncle; the uncus; part of the amygdaloid nucleus; the anterior part of the hippocampus and fascia dentata; the tail of the caudate nucleus; and the choroid plexus of the inferior horn of the lateral ventricle. It does not participate in the supply of the thalamus proper (Percheron, 1977). There are anastomoses between the anterior choroidal artery and the posterior communicating, posterior and middle cerebral arteries, but most importantly with the posterolateral choroidal artery in the choroid plexus and lateral geniculate body.

In all cases described, CT scanning showed areas of reduced density, signifying recent ischaemia, in the posterior limb of the internal capsule, sparing the thalamus medially but encroaching on the globus pallidus laterally (fig. 3). The site of this diminished density corresponds exactly with the area of supply of the anterior choroidal artery as described above, and as reconstructed by Damasio (1983) on diagrams of regular CT cuts. Its distribution differs from the capsuloputamino-caudate territory involved in infarcts of the deep branches of the middle cerebral artery.

TABLE 2. CASES DESCRIBED IN THE LITERATURE

	<i>Kolisko (1)</i> (1891)	<i>Kolisko (2)</i> (1891)	<i>Foix et al.</i> (1925)	<i>Poppi</i> (1928)	<i>Ley</i> (1932)	<i>Abbie</i> (1933)	<i>Buge et al.</i> (1979)
Hemiplegia	+	+	+	+	+	+	0
Hemianaesthesia	+	+	+	+	+	+	0
Homonymous hemianopia	0	0	+	0	+	+	0
Other signs	0	0	0	Ptosis contralateral to the hemiplegia		Superior homonymous quadrantanopia contralateral to hemiplegia	Pseudobulbar syndrome; paralysis of vertical gaze
Observations				Associated lesions in the territory supplied by the paramedian artery of the mamillary peduncle (artery of Foix)		Bilaterally affected	Bilaterally affected

Involvement of the whole territory supplied by the anterior choroidal artery produces massive hemiplegia, hemianaesthesia for all sensory modalities, and a homonymous hemianopia; this is the clinical picture originally described by Foix *et al.* in 1925, and in 3 of the 7 cases described in the subsequent literature (Table 2). Three of our patients (Cases 1-3) correspond to this picture. The hemiplegia is usually severe and equal throughout the affected half of the body. The anterior choroidal artery supplies the upper motor neuron pathway at two sites: the cerebral peduncle and the posterior limb of the internal capsule, where it is now known that the pyramidal tract occupies the posterior half (Brion and Guiot, 1964; Englanger *et al.*, 1975; Hanaway and Young, 1977; Ross, 1980), which is supplied by the anterior choroidal artery. Anatomical examination shows that it is the capsular lesion which is usually responsible. The sensory deficit is of variable intensity, not dissociated, and involves the whole body half. It is related to lesions of the superior thalamic radiations situated in the thalamolenticular portion of the posterior limb of the internal capsule. A homonymous hemianopia can be the consequence of separate lesions at any of the three points at which the anterior choroidal artery supplies the visual pathway: the optic tract, the lateral geniculate body, and the optic radiation.

In anatomically verified cases, it is the optic radiation which is most frequently affected.

The clinical picture of anterior choroidal artery infarction is sometimes less complete; one or more of the three cardinal symptoms may be missing. In 3 out of the 7 observations in the literature, and in 7 of our own cases the clinical picture was one of hemiplegia associated with a sensory deficit of greater or lesser degree usually affecting half the body. Usually predominating in the upper limb, the sensory deficit was more or less complete, most frequently being a hypaesthesia (Cases 5-9, 15, 16) rather than an anaesthesia (Case 4). In 4 patients (Cases 4, 6, 8, 15), the sensory loss was not dissociated, while in 3 others (Cases 5, 7, 9), joint position sense was unaffected. In Case 16, there was isolated ataxia of the upper limb. Recently, Ward *et al.* (1984) have published an observation on a case of this type, shown on the basis of CT scanning to be due to infarction in the territory of the anterior choroidal artery.

The clinical picture may occasionally be that of a pure motor hemiplegia (Cases 10-12). Fisher and Curry (1965), in a clinical and neuropathological study of pure motor hemiplegia, found two types of ischaemic lesion to be responsible for this syndrome: capsuloputaminocaudate infarcts in the territory of the lateral lenticulostriate branches of the middle cerebral artery, and pallidocapsular infarcts in the territory of the perforating branches of the anterior choroidal artery. In a CT study of 30 cases of pure motor hemiplegia, Rascol *et al.* (1982) found both of the types described by Fisher and Curry (1965) in the form of reduced capsulopallidal or capsuloputaminocaudate densities. Such capsulopallidal lesions, when responsible for pure motor hemiplegia, seem to be due to small infarcts in the territory of the perforating branches of the anterior choroidal artery.

In 2 patients (Cases 13, 14), infarction in the territory of the anterior choroidal artery gave rise to undissociated sensory loss in half of the body, identical to that in the syndrome described by Dejerine and Roussy in 1906 due to a limited ischaemic lesion in the ventroposterolateral nucleus of the thalamus (Cambier, 1982); the term 'pure sensory stroke' was applied to this in 1965 by Miller Fisher, who also commented that it was possible to see this syndrome with pathologies other than thalamic. Derouesné *et al.* (1985) were the first to describe 'pure sensory stroke' in relation to an infarct in the territory of the anterior choroidal artery. In one of the cases illustrated by CT scan by Rosenberg and Koller (1981), a small lacunar infarct in the posterior limb of the internal capsule seems to be responsible for the symptoms.

A homonymous visual field defect can exceptionally be the only sign of an infarct in the territory of the anterior choroidal artery. The patient described by Abbie (1933) had bilateral occlusion of the anterior choroidal arteries, with the complete triad of symptoms on one side but a homonymous superior quadrantanopia on the other, in association with a lesion affecting the lateral part of the lateral geniculate body. One of the patients described by Rand *et al.* (1956) had a left upper homonymous quadrantanopia following surgical ligation of the right anterior choroidal artery.

Bilateral anterior choroidal artery infarcts are very rare, and their clinical presentation is very variable. Apart from the case of Abbie (1933), alluded to above, Buge *et al.* (1979) have reported a case of bilateral anterior choroidal infarction which presented as a major pseudobulbar syndrome without any motor deficit in the limbs. Oculomotor palsies have been described in cases of anterior choroidal artery infarction. Thus Poppi (1928) observed ptosis contralateral to the hemiplegia associated with infarction of the posterior limb of the internal capsule, cerebral peduncle and third nerve nucleus. Buge *et al.* (1979) noted paralysis of upward movement in a case of bilateral infarction in the territory of the anterior choroidal artery. In our Case 15 (previously published by Viader *et al.*, 1984), there was diplopia in association with defective upward eye movement on the side of the lesion.

Surgical ligation of the anterior choroidal artery was formerly employed for the treatment of Parkinson's disease (Cooper, 1954; Rand *et al.*, 1956) and could be entirely asymptomatic. This variability in clinical effects is a consequence of the rich anastomotic connections of the anterior choroidal artery with other vessels in its neighbourhood.

The aetiology of infarcts is frequently uncertain. In 2 of our patients (Cases 2 and 4), emboli of cardiac origin were probable. In 4 patients (Cases 7–10), carotid stenosis, confirmed by Doppler examination, was found on the side of the lesion, suggesting an embolus arising from the stenosed portion of artery. In 2 patients (Cases 12 and 16), lacunar infarcts due to arteriolar lipohyalinosis may be suspected. In the cases examined anatomically by Ley (1932) and by Buge *et al.* (1979), there was atheromatous stenosis of the internal carotid arteries, but the anterior choroidal artery was unaffected.

Language disorders following anterior choroidal artery infarction are inconstant and minor. They are often limited to a mild dysarthria (Cases 7–10, 12, 15, 16); less frequently (Cases 6, 8) they resemble the symptoms of thalamic aphasia (Cambier *et al.*, 1982a), with loss of verbal fluency, difficulty in organizing speech, rare semantic paraphasias, but sparing of repetition and comprehension. The interruption of thalamocortical connections between thalamic nuclei, particularly the pulvinar and postrolandic cortical language areas may account for its occurrence (Penfield and Roberts, 1959; Cambier *et al.*, 1982a).

In 3 cases with right-sided lesions, we have observed various degrees of left hemispatial neglect, similar to that seen in circumscribed parietal lesions (Hécaen *et al.*, 1956; Heilman *et al.*, 1971; Dehen and Cambier, 1980) or thalamic pathology (Watson and Heilman, 1979; Watson *et al.*, 1981; Cambier *et al.*, 1982b; Cambier and Graveleau, 1985). The very characteristic behaviour is seen essentially in visuospatial activities in which the attentional component predominates, such as crossing out symbols, the description and copying of pictures, copying of complex Rey's figure (Rey, 1959; Pillon, 1981) and the description of Poppelreuter's overlapping drawings test (Walsh, 1978). It is absent or less marked, on the other hand, when the patient is engaged in intentional activities, such as placing towns on an

outline map or spontaneous drawing. Lesions of the posterior limb of the internal capsule such as are brought about by infarction in the territory of the anterior choroidal artery interrupt the connections between the thalamus and the primary sensory and associative postrolandic cortex (Carpenter, 1976), particularly those between the pulvinar and the inferior parietal lobule (Mauguière *et al.*, 1978) which are important in attentional functions (Mesulam, 1981; Heilman *et al.*, 1985). The appearance of a neglect syndrome as a consequence of the interruption of these connections underlines the importance of thalamocortical mechanisms in the regulation of attentional behaviour directed towards the contralateral half of space. The lack of interruption of connections between the thalamus and the frontal cortex is probably responsible for the absence, or the very slight extent, of spatial neglect in some intentional activities.

REFERENCES

- ABBIE A A (1933) The clinical significance of the anterior choroidal artery. *Brain*, **56**, 233–246.
- BRION S, GUIOT G (1964) Topographie des faisceaux de projection du cortex dans la capsule interne et dans le pédoncule cérébral: étude des dégénérescences secondaires dans la sclérose latérale amyotrophique et la maladie de Pick. *Revue Neurologique*, **110**, 123–144.
- BUGE A, ESCOURROLLE R, HAUW J J, RANCUREL G, GRAY F, TEMPIER P (1979) Syndrome pseudo-bulbaire aigu par infarctus bilatéral limité du territoire des artères choroïdiennes antérieures. *Revue Neurologique*, **135**, 313–318.
- CAMBIER J (1982) Le syndrome de Dejerine-Roussy. *Revue Neurologique*, **138**, 979–988.
- CAMBIER J, ELGHOZI D, GRAVELEAU PH (1982a) *Neuropsychologie des Lésions du Thalamus. Rapport de Neurologie Présenté au Congrès de Psychiatrie et de Neurologie de Langue Française. LXXX^e Session, Barcelone 7 au 12 Juin 1982*. Paris: Masson.
- CAMBIER J, MASSON M, GRAVELEAU PH, ELGHOZI D (1982b) Sémiologie de négligence lors des lésions ischémiques dans le territoire de l'artère cérébrale postérieure droite. Rôle de la lésion thalamique. *Revue Neurologique*, **138**, 631–648.
- CAMBIER J, GRAVELEAU PH (1985) Thalamic syndromes. In: *Handbook of Clinical Neurology*, Volume 45. Edited by P. J. Vinken, G. W. Bruyn and H. L. Klawans. Amsterdam: Elsevier, pp. 87–98.
- CAMBIER J, GRAVELEAU PH, DECROIX J P, ELGHOZI D, MASSON M (1983) Le syndrome de l'artère choroïdienne antérieure: étude neuropsychologique de 4 cas. *Revue Neurologique*, **139**, 553–559.
- CARPENTER M B (1976) *Human Neuroanatomy*. 7th edition. Baltimore: Williams and Wilkins, pp. 463–464.
- CARPENTER M B, NOBACK C R, MOSS M L (1954) The anterior choroidal artery: its origins, course, distribution and variations. *Archives of Neurology and Psychiatry, Chicago*, **71**, 714–722.
- COOPER I S (1954) Surgical occlusion of the anterior choroidal artery in parkinsonism. *Surgery, Gynecology and Obstetrics*, **99**, 207–219.
- DAMASIO H (1983) A computed tomographic guide to the identification of cerebral vascular territories. *Archives of Neurology, Chicago*, **40**, 138–142.
- DEHEN H, CAMBIER J (1980) Négligence somesthésique, visuelle, auditive et impersistence motrice par lésion ischémique limitée hémisphérique droite. *Nouvelle Presse Médicale*, **9**, 249.
- DEJERINE J, ROUSSY G (1906) Le syndrome thalamique. *Revue Neurologique*, **14**, 521–532.
- DEROUESNÉ C, YELNIK A, CASTAIGNE P (1985) Déficit sensitif isolé par infarctus dans le territoire de l'artère choroïdienne antérieure. *Revue Neurologique*, **141**, 311–314.
- ENGLANGER R N, NETSKY M G, ADELMAN L S (1975) Location of human pyramidal tract in the internal capsule: anatomic evidence. *Neurology, Minneapolis*, **25**, 823–826.

- FISHER C M (1965) Pure sensory stroke involving face, arm and leg. *Neurology, Minneapolis*, **15**, 76–80.
- FISHER C M, CURRY H B (1965) Pure motor hemiplegia of vascular origin. *Archives of Neurology, Chicago*, **13**, 30–44.
- FOIX CH, CHAVANY J A, HILLEMAND P, SCHIFF-WERTHEIMER S (1925) Oblitération de l'artère choroïdienne antérieure. Ramollissement de son territoire cérébral. Hémiplégié, hémianesthésie, hémianopsie. *Bulletin de la Société d'Ophtalmologie de Paris*, **37**, 221–223.
- HANAWAY J, YOUNG R R (1977) Localization of the pyramidal tract in the internal capsule of man. *Journal of the Neurological Sciences*, **34**, 63–70.
- HÉCAEN H, PENFIELD W, BERTRAND C, MALMO R (1956) The syndrome of apractognosia due to lesions of the minor cerebral hemisphere. *Archives of Neurology and Psychiatry, Chicago*, **75**, 400–434.
- HEILMAN K M, PANDYA D N, KAROL E A, GESCHWIND N (1971) Auditory inattention. *Archives of Neurology, Chicago*, **24**, 323–325.
- HEILMAN K M, VALENSTEIN E, WATSON R T (1985) The neglect syndrome. In: *Handbook of Clinical Neurology*, Volume 45. Edited by P. J. Vinken, G. W. Bruyn and H. L. Klawans. Amsterdam: Elsevier, pp. 153–183.
- KOLISKO A (1891) *Über die Beziehung der Arteria choroïdea anterior zum hinteren Schenkel der inneren Kapsel des Gehirnes*. Vienna: A. Hölder.
- LAZORTHE G (1961) *Vascularisation et Circulation de Cérébrales*. Paris: Masson.
- LEY J (1932) Contribution à l'étude du ramollissement cérébral, envisagée au point de vue de la pathogénie de l'ictus apoplectique. *Journal de Neurologie et de Psychiatrie*, **32**, 785 and 895.
- MASSON M, DECROIX J P, HENIN D, DAIROU R, GRAVELEAU PH, CAMBIER J (1983) Syndrome de l'artère choroïdienne antérieure: étude clinique et tomodensitométrie de 4 cas. *Revue Neurologique*, **139**, 547–552.
- MAUGUIÈRE F, BALEYDIER C, GARDE A (1978) Organisation anatomique et fonctionnelle des aires corticales 'associatives' 7, 21 et 22 chez le singe: a propos de la mise en évidence par la technique du marquage par la peroxydase de projections corticales du pulvinar. *Revue Neurologique*, **134**, 93–102.
- MESULAM M-M (1981) A cortical network for directed attention and unilateral neglect. *Annals of Neurology*, **10**, 309–325.
- PENFIELD W, ROBERTS L (1959) *Speech and Brain-Mechanisms*. Princeton: Princeton University Press and London: Oxford University Press.
- PERCHERON G (1977) Les artères du thalamus humain: les artères choroïdiennes. *Revue Neurologique*, **133**, 547–558.
- PILLON B (1981) Troubles visuo-constructifs et méthodes de compensation: résultats de 85 patients atteints de lésions cérébrales. *Neuropsychologia*, **19**, 375–383.
- POPPI U (1928) La sindrome anatomo-clinica conseguente a lesione dell'arteria choroidea anteriore. *Rivista di Neurologia*, **1**, 466–475.
- RAND R W, BROWN W J, STERN W E (1956) Surgical occlusion of the anterior choroidal arteries in parkinsonism: clinical and neuropathologic findings. *Neurology, Minneapolis*, **6**, 390–401.
- RASCOL A, CLANET M, MENELFE C, GUIRAUD B, BONAFE A (1982) Pure motor hemiplegia: CT study of 30 cases. *Stroke*, **13**, 11–17.
- REY A (1959) *Le Test de Copie de Figure Complexe*. Paris: Centre de Psychologie Appliquée.
- RHOTON A L, FUJII K, FRADD B (1979) Microsurgical anatomy of the anterior choroidal artery. *Surgical Neurology*, **12**, 171–187.
- ROSENBERG N L, KOLLER R (1981) Computerized tomography and pure sensory stroke. *Neurology, New York*, **31**, 217–220.
- ROSS E D (1980) Localization of the pyramidal tract in the internal capsule by whole brain dissection. *Neurology, New York*, **30**, 59–64.
- VIADER F, MASSON M, MARION M H, CAMBIER J (1984) Infarctus cérébral dans le territoire de l'artère choroïdienne antérieure avec trouble oculomoteur. *Revue Neurologique*, **140**, 668–670.

- WALSH K W (1978) *Neuropsychology. A Clinical Approach*. Edinburgh: Churchill Livingstone, pp. 250-251.
- WARD T N, BERNAT J L, GOLDSTEIN A S (1984) Occlusion of the anterior choroidal artery. *Journal of Neurology, Neurosurgery and Psychiatry*, **47**, 1048-1049.
- WATSON R T, HEILMAN K M (1979) Thalamic neglect. *Neurology, New York*, **29**, 690-694.
- WATSON R T, VALENSTEIN E, HEILMAN K M (1981) Thalamic neglect: possible role of the medial thalamus and nucleus reticularis in behavior. *Archives of Neurology, Chicago*, **38**, 501-506.

(Received September 24, 1985. Revised November 29, 1985. Accepted December 20, 1985)