



# Delayed microsurgical revascularization in an acute ischemic stroke based on perfusion study

Jiri Dostal<sup>1</sup> · Jan Mracek<sup>1</sup> · Filip Heidenreich<sup>2</sup> · Vladimír Priban<sup>1</sup>

Received: 14 September 2023 / Accepted: 20 October 2023 / Published online: 1 November 2023  
© The Author(s), under exclusive licence to Springer-Verlag GmbH Austria, part of Springer Nature 2023

## Abstract

A 58-year-old patient presented with a severe neurological deficit due to a stroke caused by an occlusion of the left internal carotid artery siphon. Standard treatment failed and neurosurgical consult was delayed. Because of a favorable perfusion imaging finding, microsurgical revascularization via an extra-intracranial bypass (left superficial temporal artery — left middle cerebral artery) was performed 36 hours after the onset of the symptoms. The outcome of the patient was favorable. The authors want to emphasize the need to actively seek patients with a severe neurological deficit and still viable brain tissue. The time window and treatment alternatives are discussed.

**Keywords** CT perfusion · Carotid artery dissection · Large vessel occlusion · Intracranial atherosclerosis · Extra-intracranial bypass · 4D CT angiography

## Background

The standard of treatment of acute ischemic stroke due to a large vessel occlusion (LVO) is an intravenous thrombolysis (IVT) and mechanical thrombectomy (MTE). In case of their failure and continuing LVO, the prognosis of the patient is unfavorable. Appropriately indicated early surgical revascularization can be of great benefit for these patients. It can be done either via direct microsurgical embolectomy, or extra-intracranial (EC-IC) bypass, or both. The prophylactic effect of the EC-IC bypass has yet to be proven, but given the most common complication of the procedure is an ischemic stroke, the surgery acting as an acute treatment can be perceived differently. An immediate augmentation of blood flow to the penumbra area can mean a chance of returning to the previous lifestyle instead of living with disability or death for the patient [4].

Microsurgical vascular procedures are done routinely at almost all neurosurgical departments, but they are often disregarded in the indication of an acute stroke. We present a case of a failed standard treatment of an acute stroke followed by a perfusion guided revascularization delayed by 36 h with a successful outcome. We are convinced, that in a very specific group of patients with a large volume of ischemic, yet still viable brain tissue, the time limit for revascularization can be disregarded.

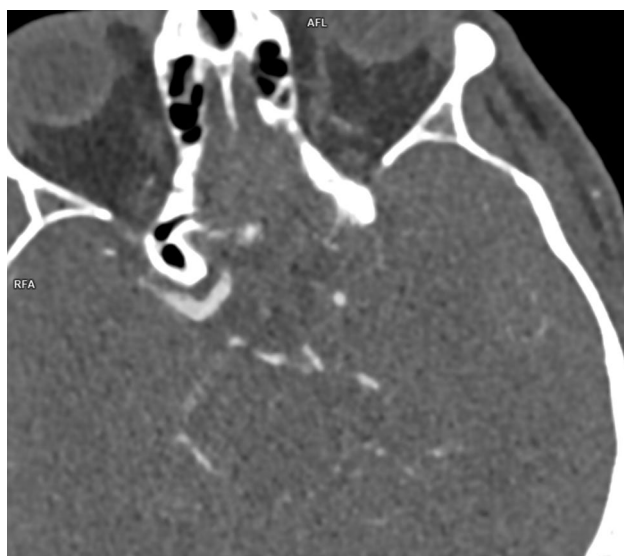
## Case report

A 58-year-old nonsmoker without any significant comorbidities presented to the emergency room (ER) of our hospital because of repeated dysesthesias of the right lower extremity. The symptoms developed 1 day after physical strain. During the examination at the ER the patient suddenly developed global aphasia, right-sided hemiplegia and facial palsy. All of the mentioned symptoms resolved subtotally in a few minutes. An urgent non-contrast CT showed no pathology, CTA showed an occlusion of the left internal carotid artery (ICA) (Fig. 1) in the carotid siphon due to a dissection (Fig. 2) in a severely atherosclerotic terrain (Fig. 3). The CT perfusion (CTP) showed a large area of penumbra zone without any ischemic core (Fig. 4). The patient was administered IVT and admitted to the neurological department.

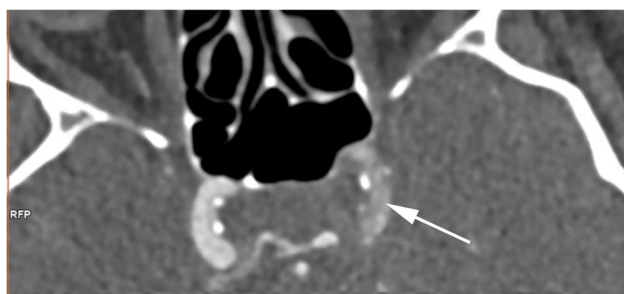
✉ Jiri Dostal  
dostalj@fnplzen.cz

<sup>1</sup> Department of Neurosurgery, University Hospital and Faculty of Medicine in Pilsen, Charles University, Pilsen, Czech Republic

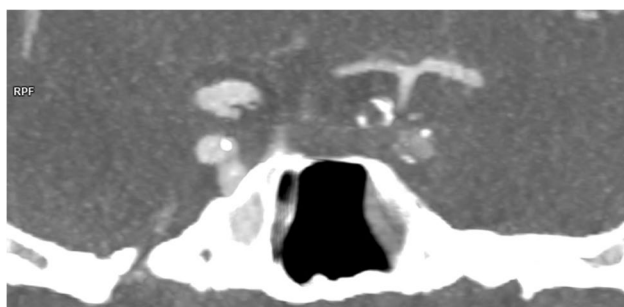
<sup>2</sup> Department of Imaging Methods, University Hospital and Faculty of Medicine in Pilsen, Charles University, Pilsen, Czech Republic



**Fig. 1** CTA (axial view) showing an occlusion of the left internal carotid artery (ICA)



**Fig. 2** CTA (axial view) showing a dissection of the left ICA



**Fig. 3** CTA (coronal view) showing an advanced intracranial atherosclerosis of the left ICA

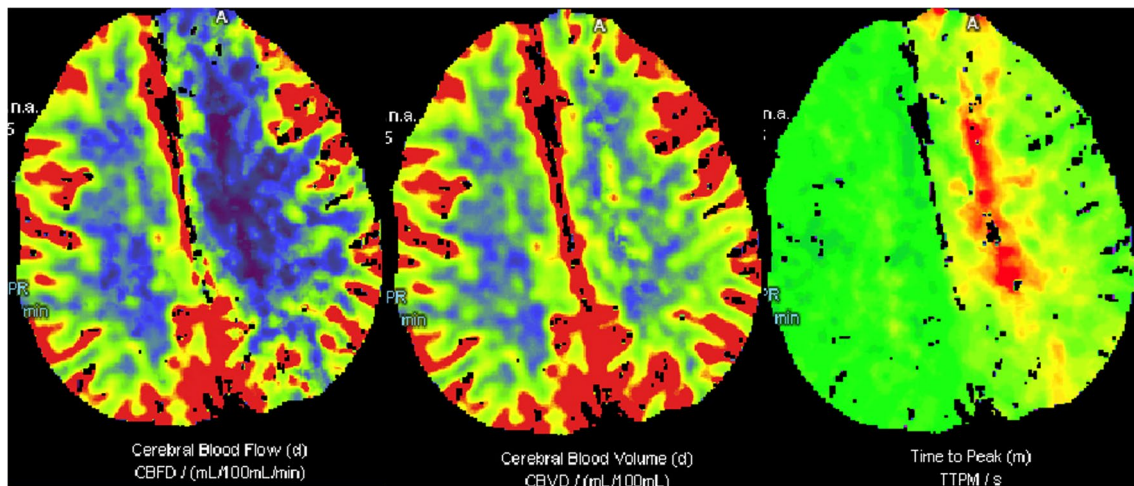
An endovascular specialist was consulted, and he contraindicated any procedure due to a severe intracranial atherosclerosis. Repeated CT scan showed neither hypodensity of brain tissue nor hematoma. Next day, more than 24 h after the onset of the symptoms, the patient developed a

fluctuating neurological deficit, which eventually fixed as a right-sided hemiplegia, global aphasia and facial palsy. Repeated CT, CTA, and CTP were performed. They showed no hypodensity, no hematoma, no ischemic core, slightly enlarged penumbra area, and lasting occlusion of left internal carotid artery with a good collateral circulation. Slowing of blood flow in the left MCA could be seen on the 4D CTA (post-processed from CTP datasets) (Fig. 5). No major ophthalmic artery or leptomeningeal collaterals, suggesting chronic ICA occlusion, were found on the CTA.

A neurosurgeon was consulted with a delay, and a surgical revascularization was indicated. The indication was based on a severe neurological deficit with a favorable perfusion imaging finding in a persisting LVO after the failure of the standard treatment. The neurological deficit did not improve with induced arterial hypertension. Because of the presumption of the collateral circulation through the circle of Willis being barely sufficient, the flow augmentation procedure was chosen. An extra-intracranial bypass connecting left superficial temporal artery with a left sided cortical branch of middle cerebral artery was performed (Fig. 6). The surgery was uneventful. The Cut Flow Index of the bypass [1] was 1; blood flow through the bypass was 29 ml/min. The revascularization was completed 36 h after the patient first entering the ER. Next day, repeated graphic studies were performed. CTA showed a patent bypass and persisting occlusion of the left ICA. CTP showed a major improvement of the formerly impaired perfusion with only a small ischemic core in a non-eloquent area of the left frontal lobe (Fig. 7). The patient was started on dual antiplatelet medication. At the 3-month follow-up, the patient had no aphasia and had a very light residual paresis of the right lower extremity. The patient was able to walk with a support of one stick. Repeated graphic studies were performed. CT showed a small hypodensity corresponding to the hypoperfused area of the non-eloquent left frontal lobe. CTA showed healed dissection and recanalization of the left ICA. The patient was put on a mono antiplatelet therapy (acetylsalicylic acid). The 9-month follow-up showed further improvement of the gait.

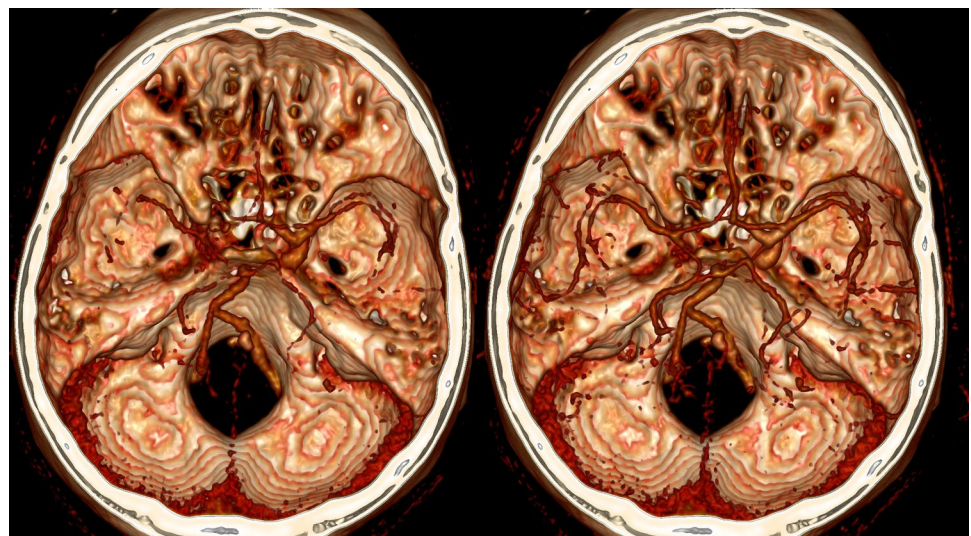
## Discussion

Reports of an emergency microsurgical revascularization in an acute stroke have been rare, but small case series showed promising results [3, 10, 12]. Single published cases showed the benefit of the surgery [7, 9]. In 2022, Fiedler et al. published the results of a prospective study EMIAS. The study concerned emergency microvascular procedure in a failure of MTE. It showed benefit for a small subgroup of patients [4]. Gautam et al. performed a meta-analysis of the current literature concerning microsurgical revascularization in a large vessel occlusion. They found out, that the correct



**Fig. 4** Preoperative CTP showing large penumbra area with only a minimal ischemic core in the left hemisphere

**Fig. 5** 4D CTA (post-processed from CTP datasets) showing slower blood flow in the left MCA compared to the right MCA



surgical indication improves the outcomes of the patients [15].

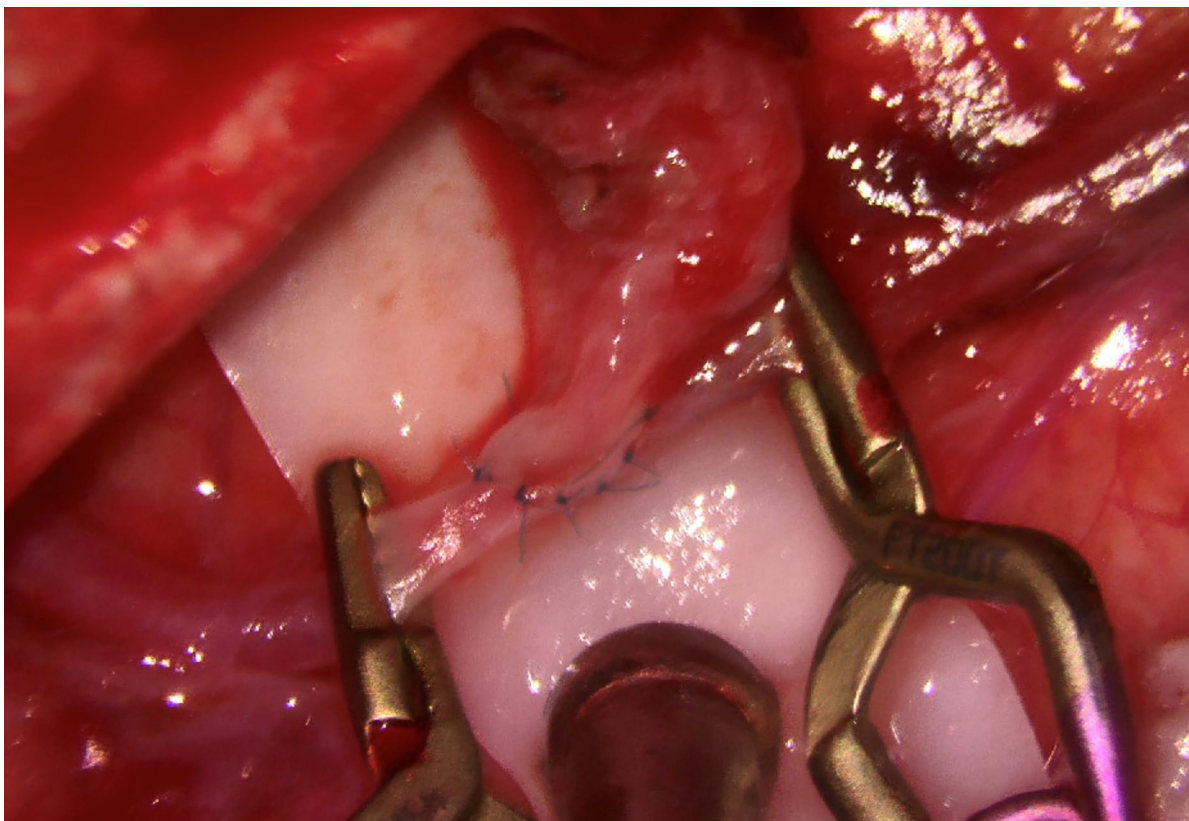
In a perfusion guided approach, Ma et al. showed benefit for the patients, when the IVT is administered up to 9 h after the onset of the symptoms [8]. DAWN study showed benefit for the patients, when the MTE is performed up to 24 h after the onset of the symptoms [11]. The results apply for a small and carefully chosen subgroup of patients.

The most feared complication of the mentioned procedures is a symptomatic intracerebral hemorrhage (sICH). DAWN study showed twice as many hemorrhages in the MTE group compared to the medical therapy group (6% and 3% respectively). The result was statistically non-significant. Ma et al. registered a sICH in 6% of patients administered IVT in the 9-h time window [8]. EC-IC bypass probably carries much lower risk of sICH, considering the LVO is not recanalized and the augmented

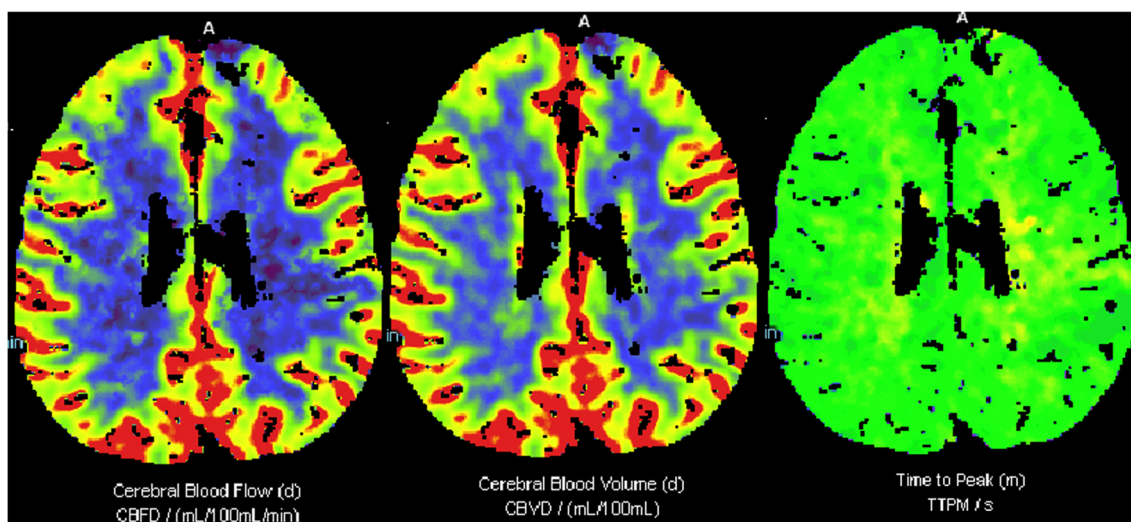
blood flow is lower and under lower pressure. The surgical results of the Carotid Occlusion Surgery Study registered no sICH up to 30 days after the surgery [5]. Although the study does not concern bypasses performed in an acute stroke, we believe, that the complications can be referenced to the mentioned topic. In the case of a microsurgical direct embolectomy from a cerebral vessel, the risk of bleeding might be comparable to that mentioned in the DAWN study. The principle of the large vessel recanalization is similar. High blood flow under high pressure into the hypoperfused brain tissue is renewed.

Kanematsu et al. published a case series of patients with the EC-IC bypass surgery shortly after the administration of recombinant tissue plasminogen activator (rt-PA). All patients were operated on longer than 5 h after the administration of rt-PA. No hemorrhages were registered [6]. A terminal half-life of rt-PA is 72 min [13]. With a high





**Fig. 6** Flow augmentation STA-MCA EC-IC bypass. Bypass flow was 29 ml/min, cut flow index was 1



**Fig. 7** CTP showing normalization of formerly impaired blood supply to left hemisphere with only a small ischemic core in a non-eloquent area of the left frontal lobe

probability delaying the surgery due to fear of hemorrhagic complication is unnecessary.

Although MRI perfusion-diffusion mismatch is becoming a standard study to evaluate the extent of

hypoperfusion and ischemic core at some departments, it has been shown that CT perfusion imaging yields the same accuracy [2]. Our department therefore routinely performs

CT perfusion imaging, as it is readily available, and more cost effective compared to the MRI.

Digital subtraction angiography (DSA) was not performed. Therapeutic angiography was not possible due to the occlusion localized in the terrain of a severe atherosclerosis of the intracranial ICA. The added benefit of the diagnostic DSA might have been the visualization of the subtle collateral vessels, which were not seen on the CTA. However, the visualization of these vessels would not have significantly influenced our surgical indication.

In the presented case, the patent EC-IC bypass ensured sufficient time for healing of the dissection and recanalization of the ICA occlusion. It might also act as a protective measure from the development of an ischemic core in case of systemic hypotension or increased demand for oxygenated blood by the brain. The maturation phenomenon can ensure further increase of blood flow into the hypoperfused hemisphere over time.

The conservative treatment approach was deemed inappropriate given a severe fluctuating neurological impairment and a corresponding finding of hypoperfusion on the CT perfusion imaging. The chance of spontaneous reparation in these rare cases remains unclear. Cerebrovascular reserve capacity examination can be considered, although acetazolamide challenge could further worsen the perfusion state of the ischemic hemisphere and lead to an ischemic core formation. Sebök et al. published a protocol for a potentially less harmful selection of the patients with an ischemic stroke in an acute LVO, who could benefit from an acute EC-IC bypass surgery [14]. The protocol includes a perfusion assessment with MRI, BOLD MRI and NOVA-qMRI. One of the selection criteria was low or moderate neurological impairment (NIHSS 1-15, modified Rankin score <4). The patient presented in this case report had a severe neurological impairment and a clear finding of a significant penumbra hypoperfusion of the left hemisphere with only a minimal ischemic core. Any advanced graphical examination was deemed unnecessary and would further delay the surgery.

We assume that the EC-IC bypass surgery augmenting blood flow into the acutely hypoperfused hemisphere without a fully developed ischemic core might provide a major benefit for the patients with a severe neurological deficit. By reason of the chance of spontaneous reparation of hypoperfusion being unknown, low departmental complication rate of EC-IC bypass surgery should be a mandatory condition taken into consideration.

## Conclusion

We are convinced that in the case of an ischemic stroke with a major neurological deficit in the large vessel occlusion and failed standard treatment, CT, CTA, and CTP should

be performed. If the graphic studies show no ischemic core and significant penumbra area, time window may not be the decisive factor in the indication of the microsurgical revascularization. Under these circumstances, even a delayed EC-IC bypass surgery is safe and effective.

**Author contribution** Jiri Dostal — conceptualization, case management, surgery, resources, writing original draft, visualization. Jan Mracek — case management, resources, writing – review and editing, funding acquisition. Filip Heidenreich — writing – review and editing, visualization – providing of graphic studies. Vladimir Priban — case management, supervision, resources, writing — review and editing, funding acquisition.

**Funding** Jiri Dostal, Jan Mracek, and Vladimir Priban were supported by the Ministry of Health of the Czech Republic — conceptual development of research organization Faculty Hospital in Pilsen; Grant number: FNPI, 00669806.

**Data availability** The additional data are available from the corresponding author upon reasonable request.

## Declarations

**Consent to participate and consent for publication** Not applicable

**Conflict of interest** The authors declare no competing interests.

## References

1. Amin-Hanjani S, Du X, Mlinarevich N et al (2005) The cut flow index: an intraoperative predictor of the success of extracranial-intracranial bypass for occlusive cerebrovascular disease. *Neurosurgery* 56:75–85 discussion 75-85
2. Campbell BC, Christensen S, Levi CR et al (2012) Comparison of computed tomography perfusion and magnetic resonance imaging perfusion-diffusion mismatch in ischemic stroke. *Stroke* 43:2648–2653
3. Diaz FG, Ausman JI, Mehta B et al (1985) Acute cerebral revascularization. *J Neurosurg* 63:200–209
4. Fiedler J, Roubec M, Grubhoffer M et al (2022) Emergent microsurgical intervention for acute stroke after mechanical thrombectomy failure: a prospective study. *J Neurointerv Surg*
5. Grubb RL Jr, Powers WJ, Clarke WR et al (2013) Surgical results of the carotid occlusion surgery study. *J Neurosurg* 118:25–33
6. Kanematsu R, Kimura T, Ichikawa Y et al (2018) Safety of urgent STA-MCA anastomosis after intravenous rt-PA treatment: a report of five cases and literature review. *Acta Neurochir (Wien)* 160:1721–1727
7. Lee CY, Kim CH, Lee CY et al (2017) Urgent bypass surgery following failed endovascular treatment in acute symptomatic stroke patient with MCA occlusion. *Neurologist* 22:14–17
8. Ma H, Campbell BCV, Parsons MW et al (2019) Thrombolysis guided by perfusion imaging up to 9 hours after onset of stroke. *N Engl J Med* 380:1795–1803
9. Mracek J, Mork J, Stepanek D et al (2013) Urgent extracranial-intracranial bypass in the treatment of acute hemodynamic ischemic stroke: case report. *J Neurol Surg A Cent Eur Neurosurg* 74:325–331
10. Ngo HM, Trinh HT, Felbaum R et al (2022) Emergency extra-intracranial bypass surgery in a patient with neurologic deficit

- after an accident in carotid occlusive test: a case report. *Int J Surg Case Rep* 94:107071
11. Nogueira RG, Jadhav AP, Haussen DC et al (2018) Thrombectomy 6 to 24 hours after stroke with a mismatch between deficit and infarct. *N Engl J Med* 378:11–21
  12. Nussbaum ES, Janjua TM, Defillo A et al (2010) Emergency extracranial-intracranial bypass surgery for acute ischemic stroke. *J Neurosurg* 112:666–673
  13. Reed M, Kerndt CC, Nicolas D. Alteplase (2023) In: StatPearls [Internet]. Treasure Island (FL): StatPearls Publishing. Available from: <https://www.ncbi.nlm.nih.gov/books/NBK499977/>
  14. Sebök M, Esposito G, Niftrik CHBV et al (2022) Flow augmentation STA-MCA bypass evaluation for patients with acute stroke and unilateral large vessel occlusion: a proposal for an urgent bypass flowchart [published online ahead of print. *J Neurosurg* 1–9. <https://doi.org/10.3171/2021.10.JNS21986>
  15. Thongphetsavong Gautam A, Seh H, Jain A et al (2021) Open microvascular thrombectomy for acute intracranial large vessel occlusion: microsurgery in the endovascular thrombectomy era. *World Neurosurg* 145:e278–e290

**Publisher's note** Springer Nature remains neutral with regard to jurisdictional claims in published maps and institutional affiliations.

Springer Nature or its licensor (e.g. a society or other partner) holds exclusive rights to this article under a publishing agreement with the author(s) or other rightsholder(s); author self-archiving of the accepted manuscript version of this article is solely governed by the terms of such publishing agreement and applicable law.