

## INTERHEMISPHERIC SUBDURAL HEMATOMA

Gilbert J. Toffol, DO, José Biller, MD, and Harold P. Adams, Jr., MD

Department of Neurology, Division of Cerebrovascular Diseases,  
University of Iowa Hospitals and Clinics, Iowa City;  
and Iowa City Veterans Administration Hospital

Reprint address: Gilbert J. Toffol, DO, Department of Neurology, Division of Cerebrovascular Diseases,  
University of Iowa Hospitals & Clinics, Iowa City, IA 52242

**Abstract**—A case of interhemispheric subdural hematoma (ISH) following closed head injury is reported. Our patient had seizures and mental status changes. Cranial computed tomography (CT) demonstrated areas of increased density along the right side of the falx cerebri and over the right leaf of the tentorium cerebelli. Conservative treatment was chosen and the patient recovered. Ten other patients with ISH were compared with ours. Head injury is the leading cause of ISH. Most patients display confusion, lethargy, or a “falx syndrome,” with a delayed interval of prominent neurological deficits from the time of injury until presentation. Although patients with ISH can be successfully treated by medical management, surgical intervention may be required.

**Keywords**—hematoma; falx; trauma; arteriography; craniotomy

### Introduction

Interhemispheric subdural hematoma (ISH) is often seen in child abuse cases where the child was given a severe shaking.<sup>1,2</sup> However, ISH is rare among adults. ISH is usually of traumatic origin and has characteristic clinical features.<sup>3</sup> Mental status changes appear several hours to days after the trauma; however, rapid deterioration without warning can occur.<sup>4</sup> Before computed tomography (CT) patients who had a contra-

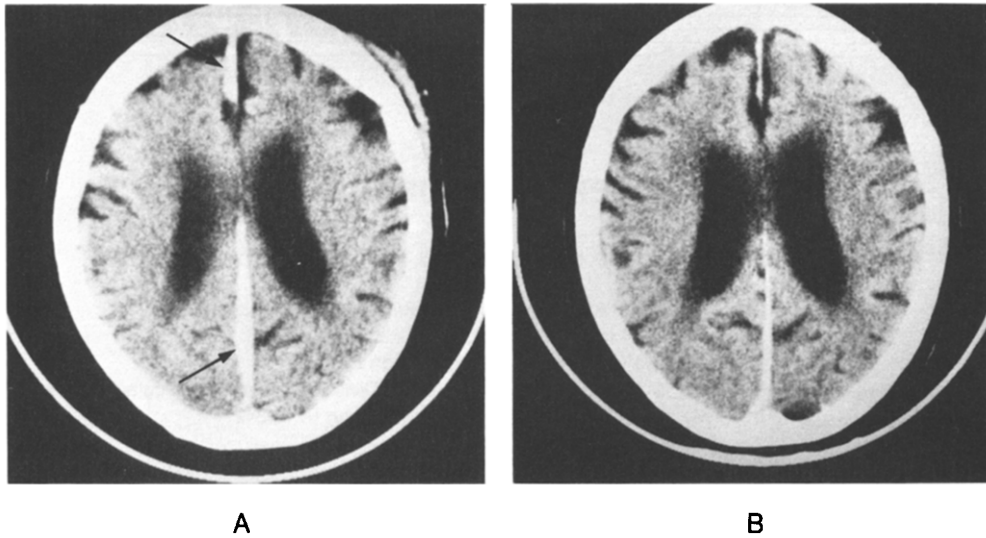
lateral leg weakness or crural hemiparesis were labeled as having a “falx syndrome.”<sup>5</sup> The differential diagnosis of this neurological finding encompasses anterior cerebral artery territory infarctions, anterior communicating artery aneurysms with subarachnoid hemorrhage, and an ISH.

On unenhanced CT scans, ISH is characterized by a crescentic hyperdensity with flat medial and convex lateral borders. Frequently the hematoma extends along the tentorium cerebelli.<sup>6</sup> These abnormalities on the CT scan may be confusing and lead to failure to diagnose a potentially treatable condition. We present a case with the typical ISH findings on CT scans who was successfully managed medically.

### Case Report

A 66-year-old man with a history of chronic alcohol abuse was transferred to the Iowa City Veterans Administration Hospital with facial lacerations, seizures, and disorientation. Earlier in the day he fell and sustained a head injury. Several hours later, he had two generalized seizures.

General physical examination showed no abnormalities. Neurological examination disclosed temporal disorientation, retrograde amnesia, and an unsteady, wide-based



**Figure 1. A:** Initial CT scan shows areas of increased density along the right side of the falx cerebri (arrows). **B:** Partial resolution of these areas two days later.

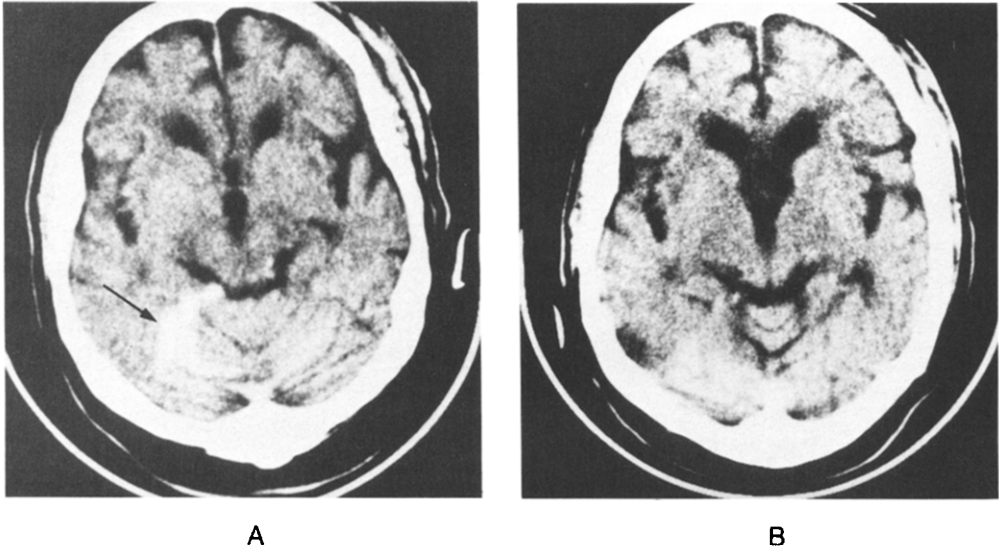
gait. He did not have unilateral or bilateral leg paresis. Findings from routine laboratory tests were normal. A CT scan demonstrated a high-density lesion along the right side of the falx cerebri extending over the right tentorium cerebelli, consistent with an ISH (Figures 1 and 2). The EEG was normal. Because of his stable neurological condition, conservative management was elected. He was treated with phenytoin 100 mg three times daily, thiamine 100 mg/d and folate 1 mg/d. The patient's mental status and gait improved. A second CT scan seven days later showed resolution of the right interhemispheric and tentorium cerebelli subdural hematoma (Figure 3).

## Discussion

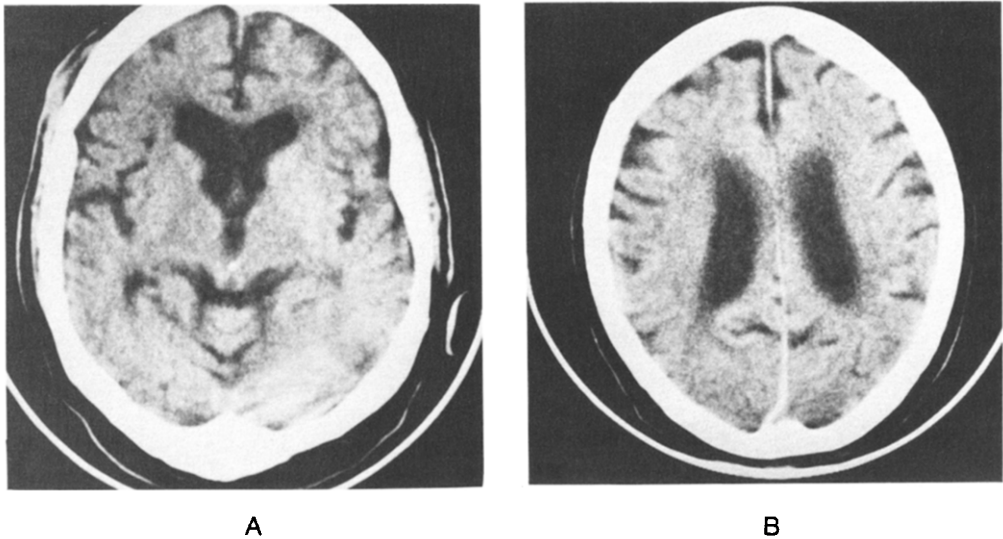
To determine the clinical presentation and possible therapeutic alternatives, we reviewed ten previously reported cases of ISH that had CT verification and adequate clinical notable information. We included our case and outlined the data in Table 1. Nine of the 11 patients had a history of head injury.<sup>3,4,7-11</sup> The remaining two patients had spontaneous ISH, one caused by a bleeding

diathesis<sup>12</sup> and the other by a ruptured saccular aneurysm.<sup>13</sup> None of the patients with traumatic ISH experienced loss of consciousness at the time of injury. However, in seven patients mental status changes or lethargy later developed.<sup>3,4,7-9,11</sup> Seizures occurred in three patients,<sup>3,7</sup> and six patients presented with a "falx syndrome."<sup>7-12</sup> Nine patients had a unilateral ISH,<sup>3,4,7-10,12</sup> one was bilateral,<sup>11</sup> and the other had an evenly uniform appearance that widened the anterior interhemispheric space.<sup>13</sup> Seven hematomas extended to the tentorium cerebelli.<sup>4,7-9,11,13</sup> Cerebral angiography was performed in four patients. One patient, who experienced sudden onset of a left third-nerve palsy, had two aneurysms of which one ruptured.<sup>13</sup> Two patients had malalignment of anterior cerebral artery vessels,<sup>7,9</sup> and a third had coexisting subdural hematomas located over the convex lateral sides of the brain.<sup>3</sup>

Craniotomy was performed in six patients; in four, evacuation of the hematoma was accomplished.<sup>4,7,9</sup> One patient had placement of Jackson-Pratt drains in each interhemispheric fissure,<sup>11</sup> and the other patient had two intracranial aneurysms clipped.<sup>13</sup> Burr holes were performed in



**Figure 2.** A: Initial CT scan shows extension of the hematoma to the right leaf of the tentorium cerebelli (arrow). B: Partial resolution of the hematoma two days later.



**Figure 3.** CT scan a week later shows complete resolution of the ISH and the hematoma over the tentorium cerebelli.

three patients. Two patients had convexity located subdural hematomas that were aspirated and drained through burr holes.<sup>3,4</sup> The third patient, because of poor medical condition, has aspiration using a cone needle through a single burr hole for the ISH.<sup>12</sup> Medical therapy was used in the remaining two patients and both recovered.<sup>10</sup> At least

three of the nine surgically treated patients died.<sup>4,12</sup>

A CT scan accurately delineates ISH and may obviate the need for cerebral angiography in patients with known trauma. Although CT is helpful in identifying the configuration of an ISH, it is not useful in determining the underlying cause in all

**Table 1. Adult Cases of ISH With CT Documentation**

Ref	Age/Sex	Etiology	Presentation/ Interval Delay	Clinical Findings	Falx Syndrome	CT	Angiography	Treatment	Outcome
3	44/M	HT	Headaches, seizures/7 d	Confusion	No	L ISH	L CSH	Burr holes for CSH	Recovered
4	54/M	HT	Normal/24 h	Decerebrate	No	R ISH, R CSH	ND	Burr holes for CSH	Expired
4	62/M	HT	Confusion/48 h	Decerebrate	No	L ISH, Tentorium ex- tension	ND	Craniotomy	Expired
7	27/M	HT	Disorientation, seizures/10 h	Right hemiparesis, legs > arms	Yes	L ISH, Tentorium ex- tension	ACAs shifted	Craniotomy	Recovered
8	24/M	HT	Amnestic/36 h	Left hemiparesis, leg > arm	Yes	R ISH, Tentorium ex- tension	ND	Craniotomy	Recovered
9	61/M	HT	Normal/6 h	Lethargy, left leg weakness	Yes	R ISH Tentorium extension	ACAs separated	Craniotomy	Recovered
10	59/M	HT	Normal/18 h	Headache, left leg weakness	Yes	R ISH	ND	Medical	Recovered
11	43/F	HT	Lethargy, confusion/4 d	Paraparesis, right arm weakness	Yes	Bilateral ISH, Tentorium extension	ND	Craniotomy, J-P drains	Recovered
12	80/M	AC	Obtundation/ 10 d	Tetraparesis, legs > arms	Yes	L ISH L ICH	ND	Burr hole	Expired
13	55/F	SA	Headaches/ sudden	Left third-nerve palsy	No	Uniformed ISH, Tentorium extension	Ruptured PCoA SA, Unrup. L ICA SA	Craniotomy for aneurysms	Recovered
Present Case	66/M	HT	Seizures/3 h	Amnestic, un- steady gait	No	R ISH, Tentorium ex- tension	ND	Medical	Recovered

Abbreviations: ISH, interhemispheric subdural hematoma; CT, computed tomography; HT, head trauma; L, left; R, right; CSH, convexity subdural hematoma; ND, not done; AC, anticoagulant; ICH, intracerebral hematoma; ACA, anterior cerebral artery; SA, saccular aneurysm; PCoA, posterior communicating artery; ICA, internal carotid artery.

hematomas. Cerebral arteriography gives added information in those patients who lack history of trauma.

Once the diagnosis of ISH is made, a neurosurgical consultation should be obtained. Burr-hole aspiration is unlikely to result in complete drainage of the clot.<sup>8</sup> Craniotomy with evacuation of the hematoma seems to be an acceptable treatment. However, approximately 50% of these hematomas are small and reabsorb spontaneously.<sup>14</sup> Fruin and associates<sup>10</sup> have suggested initial conservative medical treatment with methods to control and monitor intracranial pressure, proceeding to craniotomy only if neurological deterioration occurs. Our patient did not progress neurologically and did not develop increased intracranial pressure that might have warranted neurosurgical intervention.

## Summary

Computed tomography is effective in confirming the diagnosis of ISH. Typical abnormalities of ISH include contralateral crural paresis, paraparesis, seizures, and delayed mental status changes. Patients with ISH should be closely monitored for neurological deterioration. The larger lesions associated with progressive neurological dysfunction should be removed. Parasagittal craniotomy appears to be the only safe and acceptable method under those circumstances.

*Acknowledgment*—The authors would like to thank Ms. Darla Drake for the preparation of this manuscript.

## REFERENCES

1. Zimmerman RA, Bilaniuk LT, Bruce D, et al: Interhemispheric acute subdural hematoma: A computed tomographic manifestation of child abuse by shaking. *Neuroradiology* 1978; 16:39-40.
2. Zimmerman RA, Bilaniuk LT, Bruce D, et al: Computed tomography of craniocerebral injury in the abused child. *Radiology* 1979; 130:687-690.
3. Ogsbury JS, Schneck SA, Lehman RA: Aspects of interhemispheric subdural hematoma, including the falx syndrome. *J Neurol Neurosurg Psychiatry* 1978; 41:72-75.
4. Pozzati E, Gaist G, Vinei A, et al: Traumatic interhemispheric subdural hematomas. *J Trauma* 1982; 22:241-243.
5. List CF: Interhemispheric subdural suppuration. *J Neurosurg* 1950; 7:313-324.
6. Zimmerman RD, Russell EJ, Yaberg E, et al: Falx and interhemispheric fissure on axial CT: II. Recognition and differentiation of interhemispheric subarachnoid and subdural hemorrhage. *AJNR* 1982; 3:635-642.
7. Glista GG, Reichman HO, Brumlik J, et al: Interhemispheric subdural hematoma. *Surg Neurol* 1978; 10:119-122.
8. Fearnside MR, Hall K, Sengupta RP: Interhemispheric subdural hematoma following head injury. *Aust NZ J Surg* 1979; 49:678-680.
9. Esposito DP, Jagadishwar D, El Gammal T, et al: Interhemispheric subdural hematoma. *South Med J* 1984; 77:379-381.
10. Fruin AH, Juhl GL, Taylor C: Interhemispheric subdural hematoma. Case report. *J Neurosurg* 1984; 60:1300-1302.
11. Kasdon DL, Magruder MR, Stevens EA, et al: Bilateral interhemispheric subdural hematomas. *Neurosurgery* 1979; 5:57-59.
12. Ho SU, Spehlmann R, Ho HT: CT scan in interhemispheric subdural hematoma. Clinical and pathological correlation. *Neurology* 1977; 27:1097-1098.
13. Friedman MB, Brant-Zawadzki M: Interhemispheric subdural hematoma from ruptured aneurysm. *Comput Radiol* 1983; 7:129-134.
14. Russell NA, Benoit BG, Del Carpio R, et al: Interhemispheric subdural hematoma (Abstract 100). *Can J Neurol Sci* 1984; 11:342.